This is a digital copy of a book that was preserved for generations on library shelves before it was carefully scanned by Google as part of a project to make the world's books discoverable online.

It has survived long enough for the copyright to expire and the book to enter the public domain. A public domain book is one that was never subject to copyright or whose legal copyright term has expired. Whether a book is in the public domain may vary country to country. Public domain books are our gateways to the past, representing a wealth of history, culture and knowledge that's often difficult to discover.

Marks, notations and other marginalia present in the original volume will appear in this file - a reminder of this book's long journey from the publisher to a library and finally to you.

Usage guidelines

Google is proud to partner with libraries to digitize public domain materials and make them widely accessible. Public domain books belong to the public and we are merely their custodians. Nevertheless, this work is expensive, so in order to keep providing this resource, we have taken steps to prevent abuse by commercial parties, including placing technical restrictions on automated querying.

We also ask that you:

+ *Make non-commercial use of the files* We designed Google Book Search for use by individuals, and we request that you use these files for personal, non-commercial purposes.

+ *Refrain from automated querying* Do not send automated queries of any sort to Google's system: If you are conducting research on machine translation, optical character recognition or other areas where access to a large amount of text is helpful, please contact us. We encourage the use of public domain materials for these purposes and may be able to help.

+ *Maintain attribution* The Google "watermark" you see on each file is essential for informing people about this project and helping them find additional materials through Google Book Search. Please do not remove it.

+ *Keep it legal* Whatever your use, remember that you are responsible for ensuring that what you are doing is legal. Do not assume that just because we believe a book is in the public domain for users in the United States, that the work is also in the public domain for users in other countries. Whether a book is still in copyright varies from country to country, and we can't offer guidance on whether any specific use of any specific book is allowed. Please do not assume that a book's appearance in Google Book Search means it can be used in any manner anywhere in the world. Copyright infringement liability can be quite severe.

About Google Book Search

Google's mission is to organize the world's information and to make it universally accessible and useful. Google Book Search helps readers discover the world's books while helping authors and publishers reach new audiences. You can search through the full text of this book on the web at `http://books.google.com/`

B 3 9015 00212 231 8
University of Michigan – BUHR

Digitized by Google



Digitized by Google

610.5
P3
S7
L8t

Digitized by Google

Digitized by Google

Digitized by Google

Digitized by Google

30111

TRANSACTIONS

OF THE

PATHOLOGICAL SOCIETY OF LONDON.

VOLUME THE THIRTY-SECOND.

COMPRISING THE REPORT OF THE PROCEEDINGS FOR THE SESSION 1880-81.

LONDON:
SMITH, ELDER & CO., 15, WATERLOO PLACE.
1881.

Digitized by Google

THE present publication, being the Thirty-second Volume of Transactions, constitutes the Thirty-fifth published Annual Report of the Pathological Society's Proceedings.

The COUNCIL think it right to repeat that the exhibitors are alone responsible for the descriptions given of the Specimens exhibited by them, the only change made in the Reports furnished by the authors being such verbal alterations as were absolutely necessary.

58, BERNERS STREET, OXFORD STREET.
October, 1881.

Digitized by Google

TABLE OF CONTENTS.

OF VOLUME XXXII.

List of Presidents of the Society iv
List of Officers and Members for 1881 . . v—xxxiii
Annual Report of Council for 1880 xxxv
Address of the President xxxix
List of Specimens Exhibited during the Session 1880-81 xlv
List of Specimens Reported on by the Committee on Morbid Growths lvii
List of Plates lviii
List of Woodcuts lx
Diseases, etc., of the Nervous System . . . 1
Diseases, etc., of the Organs of Respiration . . 16
Diseases, etc., of the Organs of Circulation . . 35
Diseases, etc., of the Organs of Digestion . . 79
Diseases, etc., of the Genito-Urinary Organs . 139
Diseases, etc., of the Osseous System . . . 152
Morbid Growths 194
Diseases, etc., of the Skin 245
Miscellaneous Specimens 273
Specimens from the Lower Animals 311
Discussion on the Pathology of Rickets . . . 313
Index 405

Digitized by Google

Presidents of the Society.

ELECTED	
1846	CHARLES J. B. WILLIAMS, M.D., F.R.S.
1848	CHARLES ASTON KEY.
1850	PETER MERE LATHAM, M.D.
1852	CÆSAR H. HAWKINS, F.R.S.
1853	BENJAMIN GUY BABINGTON, M.D., F.R.S.
1855	JAMES MONCRIEFF ARNOTT, F.R.S.
1857	Sir THOMAS WATSON, Bart., M.D., F.R.S.
1859	Sir WILLIAM FERGUSSON, Bart., F.R.S.
1861	JAMES COPLAND, M.D., F.R.S.
1863	PRESCOTT G. HEWETT, F.R.S.
1865	THOMAS BEVILL PEACOCK, M.D.
1867	JOHN SIMON, D.C.L., F.R.S.
1869	RICHARD QUAIN, M.D., F.R.S.
1871	JOHN HILTON, F.R.S.
1873	Sir WILLIAM JENNER, Bart., M.D., K.C.B., D.C.L., F.R.S.
1875	GEORGE D. POLLOCK.
1877	CHARLES MURCHISON, M.D., LL.D., F.R.S.
1879	JONATHAN HUTCHINSON.
1881	SAMUEL WILKS, M.D., F.R.S.

Digitized by Google

OFFICERS AND COUNCIL

OF THE

Pathological Society of London,

ELECTED AT

THE GENERAL MEETING, JANUARY 4TH, 1881.

President.

SAMUEL WILKS, M.D., F.R.S.

Vice-Presidents.

GEORGE BUCHANAN, M.D.
THOMAS BUZZARD, M.D.
ANDREW CLARK, M.D.
JAMES EDWARD POLLOCK, M.D.
CHRISTOPHER HEATH.
JONATHAN HUTCHINSON.
S. JAMES A. SALTER, F.R.S.
SEPTIMUS WILLIAM SIBLEY.

Treasurer.

GEORGE JOHNSON, M.D., F.R.S.

Council.

THOMAS BARLOW, M.D.
EVAN BUCHANAN BAXTER, M.D.
JOHN CAVAFY, M.D.
SIDNEY COUPLAND, M.D.
SIR JOSEPH FAYRER, K.C.S.I., M.D.
WILLIAM MILLER ORD, M.D.
R. DOUGLAS POWELL, M.D.
GEORGE HENRY SAVAGE, M.D.
FREDERICK TAYLOR, M.D.
THOMAS TILLYER WHIPHAM, M.D.
W. MORRANT BAKER.
J. N. C. DAVIES-COLLEY.
JOHN WARRINGTON HAWARD.
HENRY GREENWAY HOWSE.
WILLIAM BEDFORD KESTEVEN, M.D.
JOSEPH LISTER, F.R.S.
ROBERT WILLIAM PARKER.
WILLIAM JOHNSON SMITH.
WAREN TAY.
WILLIAM JOHNSON WALSHAM.

Honorary Secretaries.

JOSEPH FRANK PAYNE, M.D. | HENRY MORRIS.

Trustees.

THOS. BEVILL PEACOCK, M.D. | RICHARD QUAIN, M.D., F.R.S.
GEORGE D. POLLOCK.

Digitized by Google

Digitized by Google

Members are requested to indicate to the Secretaries corrections when necessary.

LIST OF MEMBERS OF THE SOCIETY.

Honorary Members.

ARNOTT, JAMES MONCRIEFF, F.R.S., Chapel House, Lady Bank, Fifeshire; and 36, Sussex-gardens, Hyde-park, W.

BILLROTH, THEODOR, M.D., Professor of Surgery in the University of Vienna.

BRUECKE, ERNST, M.D., Professor of Physiology in the University of Vienna.

CHARCOT, J. M., M.D., Physician to the "Hôpital de la Salpêtrière," and Professor at the Faculty of Medicine of Paris.

CHAUVEAU, A., M.D., Professor of Physiology at the Medical School of Lyons.

COHNHEIM, JULIUS, M.D., Professor of General Pathology and Pathological Anatomy in the University of Breslau.

GROSS, SAMUEL D., M.D., D.C.L. Oxon., LL.D., Professor of Surgery in the Jefferson Medical College of Philadelphia.

HELMHOLTZ, H., M.D., Professor of Physiology in the University of Heidelberg.

HENLE, J., M.D., Professor of Anatomy and Physiology in the University of Göttingen.

LUDWIG, C., M.D., Professor of Physiology in the University of Leipzig.

PIROGOFF, NIKOLAUS, M.D., Professor of Surgery to the Medico-Chirurgical Academy of St. Petersburg.

RINDFLEISCH, EDOUARD, M.D., Professor of Pathological Anatomy in the University of Bonn.

ROBIN, CHARLES, M.D., Professor of Histology at the Faculty of Medicine of Paris.

SCHWANN, THEODOR, Professor of Physiology at the University of Liège.

THIERSCH, CARL, M.D., Professor of Surgery in the University of Leipzig.

VIRCHOW, RUDOLF, M.D., Professor of Pathological Anatomy in the University of Berlin.

EXPLANATION OF ABBREVIATIONS.

O.M.—Original Member.	V.-P.—Vice-President.
Pres.—President.	S.—Secretary.
T.—Treasurer.	C.—Member of Council.

Those marked thus (†) have paid Composition Fee for Annual Subscription.
Those marked thus (‡) have paid Composition Fee for Transactions.

GENERAL LIST OF MEMBERS.

Elected

1879 ABERCROMBIE, JOHN, M.D., 30, Alderney-street, S.W.

1858 ACLAND, HENRY WENTWORTH, M.D., F.R.S., Regius Professor of Medicine, University of Oxford, Physician to the Radcliffe Infirmary, Oxford.

‡1866 ADAMS, ARTHUR BAYLEY,

Digitized by Google

Elected

1869 ADAMS, JAMES EDWARD, Surgeon to the London Hospital, 17, Finsbury-circus, E.C.

O.M. ADAMS, WILLIAM, Consulting Surgeon to the National Orthopædic Hospital, 5, Henrietta-street, Cavendish-square, W. (C. 1851-4. V.-P. 1867-9.)

1859 ADAMS, WILLIAM, Tower Lodge, Regent's-park-road, Gloucester-gate, N.W. (C. 1877-8.)

1848 AIKIN, CHARLES A., 7, Clifton-place, Sussex-square, Hyde-park, W. (C, 1864-6.)

1872 AIKIN, CHARLES EDMUND, 7, Clifton-place, Sussex-square, Hyde-park, W.

1871 AIR, A. CUMMINGS, 316, Kennington-park-road, S.E.

1880 AITKEN, WILLIAM, M.D., F.R.S., Professor of Pathology, Army Medical School, Netley, Southampton, Park Villa, Weston-grove-road, Woolston, Southampton.

1869 ALLBUTT, THOMAS CLIFFORD, M.D., F.R.S., Physician to the Leeds General Infirmary, 35, Park-square, Leeds.

1877 ALTHAUS, JULIUS, M.D., Senior Physician to the Hospital for Epilepsy and Paralysis, Regent's Park, 36, Bryanston-street, Portman-square.

1868 ANDERSON, J. FORD, M.D., 28, Buckland-crescent, Belsize-park, N.W.

1880 ANDERSON, JAMES, M.A., M.D., C.M., 25, Welbeck-street, Cavendish-square, W.

1871 ANDERSON, WILLIAM, Assistant Surgeon to, and Lecturer on Anatomy at, St. Thomas's Hospital, 13, Welbeck-street, Cavendish-square, W.

1859 ANDREW, EDWYN, M.D., Hardwick House, St. John's-hill, Shrewsbury.

1863 ANDREW, JAMES, M.D., Physician to St. Bartholomew's Hospital, 22, Harley-street, W. (C. 1868-70.)

1863 BAGSHAWE, FREDERICK, M.A., M.D., 16, Warrior-square, Hastings.

1864 BAKER, WILLIAM MORRANT (C.), Assistant Surgeon to, and Lecturer on Physiology at, St. Bartholomew's Hospital, 26, Wimpole-street, Cavendish-square, W. (C. 1873-6, 1881. S. 1878-80.)

‡1856 BALDING, DANIEL BARLEY, Royston, Herts.

1880 BALL, BENJAMIN, Professeur à la Faculté de Médecine de Paris, Médecin en Chef de la Clinique des Maladies Mentales, Faubourg St. Honoré, 3, Paris.

1881 BALLANCE, CHARLES A., St. Thomas's Hospital.

1851 BARCLAY, A. WHYTE, M.D., Physician to St. George's Hospital, 23A, Bruton-street, Berkeley-square, W. (C. 1858-61.)

1875 BARKER, ARTHUR E. J., Assistant Surgeon and Assistant Teacher of Clinical Surgery, University College Hospital, 87, Harley-street, Cavendish-square, W.

1874 BARLOW, THOMAS, M.D., B.S. (C.), Assistant Physician to University College Hospital and to the Children's Hospital, Great Ormond-street, 10, Montague-street, Russell-square, W.C. (C. 1879-80.)

1871 BARNES, ROBERT, M.D., Obstetric Physician to St. George's Hospital, 15, Harley-street, Cavendish-square, W.

Digitized by Google

Elected

1862 BARRATT, JOSEPH GILLMAN, M.D., Accoucheur to the St. George's and St. James's Dispensary, 8, Cleveland-gardens, Bayswater, W.

1877 BARROW, A. BOYCE, Pathological Registrar, King's College Hospital, 17, Welbeck-street, Cavendish-square, W.

1881 BARRS, ALFRED GEORGE, M.B., General Infirmary, Leeds.

1879 BARTLETT, HENRY, M.D., 171, Loughboro'-road, Stockwell, S.W.

1853 BARWELL, RICHARD, Surgeon to, and Lecturer on Surgery at, the Charing Cross Hospital, 32, George-street, Hanover-square, W. (C. 1862-4.)

1861 BASTIAN, H. CHARLTON, M.A., M.D., F.R.S., Professor of Pathologica Anatomy in University College, and Physician to University College Hospital, 20, Queen Anne-street, W. (C. 1869-71.)

1877 BATEMAN, ARTHUR W., B.A., Tenterfield, New South Wales.

†1876 BATTESON, JOHN, Medical Officer of the Royal Humane Society, 1, Coborn-place, Bow-road, E.

1870 BÄUMLER, CHRISTIAN G. H., M.D., Professor of Materia Medica in the University of Erlangen.

1871 BAXTER, EVAN BUCHANAN, M.D. (C.), Professor of Materia Medica, King's College, London, and Assistant Physician to King's College Hospital, 28, Weymouth-street, Portland-place, W. (C. 1880.)

1874 BEACH, FLETCHER, M.B., Metropolitan District Asylum, Darenth, near Dartford, Kent.

1879 BEALE, EDWIN CLIFFORD, M.B., 23, Upper Berkeley-street, Portman-square, W.

1852 BEALE, LIONEL S., M.B., F.R.S., Professor of Medicine at King's College, Physician to King's College Hospital, 61, Grosvenor-street, W. (C. 1858-9. V.-P. 1874-5.)

1856 BEALEY, ADAM, M.D., M.A., Oak-lea, Harrogate.

†1878 BEANEY, JAMES GEORGE, Senior Surgeon to the Melbourne Hospital, Melbourne, Victoria.

1870 BECK, MARCUS, M.S., Assistant Surgeon to University College Hospital, 30, Wimpole-street, Cavendish-square, W. (C. 1875-7.)

1865 BEEBY, WALTER, M.D., Bromley, Kent.

1880 BEEVOR, CHARLES EDWARD, M.B., National Hospital for Paralysed and Epileptic, 23, Queen's-square, W.C.

1875 BELL, H. ROYES, Surgeon to King's College Hospital, 44, Harley-street, Cavendish-square, W.

1865 BELLAMY, EDWARD, Surgeon to the Charing Cross Hospital, 17, Wimpole-street, Cavendish-square, W. (C. 1876-8.)

1847 BENNET, JAMES HENRY, M.D., Weybridge, Surrey.

O.M. BENNETT, SIR JAMES RISDON, M.D., F.R.S., Consulting Physician to St. Thomas's Hospital, and to the City of London Hospital for Diseases of the Chest, 22, Cavendish-square, W. (C. 1846-8. V.-P. 1856-9.)

1877 BENNETT, WILLIAM HENRY, Assistant Surgeon to St. George's Hospital, Surgeon to the Belgrave Hospital for Children, 5, Savile-row, Burlington-gardens.

Digitized by Google

Elected

1878 BERNARD, FRANCIS W., M.D., Medical Superintendent, Stockwell Small-pox Hospital, Stockwell, S.W.

‡1856 BICKERSTETH, EDWARD R., Surgeon to the Liverpool Royal Infirmary, 2, Rodney-street, Liverpool.

1878 BINDON, WILLIAM JOHN VEREKER, M.D., 2, Elm-villas, Kilburn, N.W.

1850 BIRKETT, EDMUND LLOYD, M.D., Consulting Physician to the City of London Hospital for Diseases of the Chest, 48, Russell-square, W.C. (C. 1856-7.)

O.M. BIRKETT, JOHN, Consulting Surgeon to Guy's Hospital, 59, Green-street, Grosvenor-square, W. (C. 1851. V.-P. 1860-2.)

1881 BISS, CECIL YATES, M.B., Assistant Physician to the Middlesex Hospital, Claremont, Sydenham-park, S.E., and 2, Old Burlington-street, W.

1865 BISSHOPP, JAMES, Bedford-place, Tunbridge Wells.

1853 BLACK, CORNELIUS, M.D., Physician to the Chesterfield Dispensary, St. Mary's-gate, Chesterfield.

1877 BLACK, JAMES, 16, Wimpole-street, Cavendish-square, W.

1850 BLAGDEN, ROBERT, Stroud, Gloucestershire.

1863 BLANCHET, JEAN B., M.D., M.S., Montreal, Quebec, Canada.

1876 BLASSON, WILLIAM, Edgeware, Middlesex.

1879 BOILEAU, J. P. H., M.D., Surgeon-Major, Army Medical Department; Assistant Professor of Pathology, Netley School of Medicine, Netley.

1876 BOND, THOMAS, M.B., Assistant Surgeon and Lecturer on Forensic Medicine to Westminster Hospital, 7, Broad Sanctuary, Westminster, S.W.

1869 BOURNE, WALTER, M.D.

1880 BOWEN, ALFRED LONGMORE, 5, Lewisham-road, Greenwich, S.E.

1861 BOWER, RICHARD NORRIS, 14, Doughty-street, Mecklenburg-square, W.C.

1851 BOWMAN, WILLIAM, F.R.S., Surgeon to the Royal Ophthalmic Hospital, 5, Clifford-street, Bond-street, W. (C. 1855-6.)

1879 BRAILEY, WM. ARTHUR, M.D., Lecturer on Comparative Anatomy at St. George's and Guy's Hospitals, 16, Orchard-street, Portman-square, W.

1880 BRAMWELL, BYROM, M.D., 4, Drumsheugh-gardens West, Edinburgh.

1877 BRIDGES, ROBERT, M.B., M.A. Oxford, Casualty Physician to St. Bartholomew's Hospital, 52, Bedford-square, W.C.

‡1867 BRIDGEWATER, THOMAS, M.B. Lond., Harrow-on-the-hill, Middlesex.

1873 BRIGGS, JACOB MYERS, M.D., Coeymans, New York, U.S.

1868 BRIGHT, G. C., M.B., Cannes, France.

1857 BRISCOE, JOHN, 12, Broad-street, Oxford.

†1851 BRISTOWE, JOHN S., M.D., F.R.S., Physician to, and Lecturer on the Theory and Practice of Medicine at, St. Thomas's Hospital, 11, Old Burlington-street, W. (C. 1854-8. S. 1861-4. C. 1865-7. V.-P. 1868-76.)

1860 BROADBENT, WILLIAM HENRY, M.D. Lond., Physician to St. Mary's Hospital, and Physician to the London Fever Hospital, 34, Seymour-street, Portman-square, W. (C. 1871-3.)

Digitized by Google

Elected

1877 BROCKMAN, E. F., Madras Medical Service [care of Mr. Lewis, Gower-street.]

1852 BRODHURST, BERNARD E., Surgeon to the Royal Orthopædic Hospital, 20, Grosvenor-street, W. (C. 1862-4.)

1863 BRODIE, GEORGE BERNARD, M.D., Consulting Physician-Accoucheur to Queen Charlotte's Hospital, 3, Chesterfield-street, Mayfair, W.

1865 BROWN, AUGUSTUS, M.D., 38, Arundel-square, Islington, N.

1871 BROWN, FREDERICK GORDON, 16, Finsbury-circus, E.C.

1875 BROWNE, GEORGE BUCKSTON, 80, Wimpole-street, Cavendish-square, W.

1866 BROWNE, LENNOX, Surgeon to the Central Throat and Ear Hospital, and to the Royal Society of Musicians, 36, Weymouth-street, Portland-place, W.

O.M. BROWNE, JOSEPH HULLETT, M.D., late Physician to the St. Pancras Royal General Dispensary, Ridgeway House, near Southampton. (C. 1859-60.)

1877 BRUCE, J. MITCHELL, M.D., Assistant Physician to Charing Cross Hospital and to the Hospital for Consumption, Brompton, 70, Harley-street, Cavendish-square, W.

1855 BRYANT, THOMAS, Surgeon to Guy's Hospital, 53, Upper Brook-street, Grosvenor-square, W. (C. 1863-6. V.-P. 1877-79.)

1854 BUCHANAN, GEORGE, M.D. (V.-P.), Medical Officer of the Local Government Board, 24, Nottingham-place, Marylebone-road, W. (C. 1864-6. V.-P. 1880-81.)

1862 BUCHANAN, ALBERT, M.B. Lond., 364, Camden-road, N.

1858 BUDD, GEORGE, M.D., F.R.S., Ashleigh, Barnstaple. (C. 1862-4.)

1878 BURNET, ROBERT WILLIAM, M.D., 57, Queen Anne-street, Cavendish-square, W.

1853 BURTON, JOHN M., Lee-park Lodge, Lee, Kent, S.E.

1880 BURTON, SAMUEL HERBERT, M.B., Norfolk and Norwich Hospital, Norwich.

1872 BUTLIN, HENRY TRENTHAM, Assistant Surgeon to St. Bartholomew's Hospital, Assistant Surgeon to the West London Hospital, 47, Queen Anne-street, W. (C. 1876-8.)

1866 BUTT, WILLIAM FREDERICK, 25, Park-street, Park-lane, W.

1856 BUZZARD, THOMAS, M.D. (V.-P.), Physician to the National Hospital for the Epileptic and Paralysed, 56, Grosvenor-street, W. (C. 1869-70. V.-P. 1881.)

†O.M. CAMPS, WILLIAM, M.D. (C. 1856-9.)

‡1855 CARPENTER, ALFRED, M.D., High-street, Croydon.

1879 CARRINGTON, ROBERT E., M.D., Senior Demonstrator of Anatomy at Guy's Hospital, 4, St. Thomas's-street, S.E.

1871 CARTER, CHARLES HENRY, M.D., B.S. Lond., Physician to the Hospital for Women, 45, Great Cumberland-place, Hyde-park, W.

1855 CARTER, H. VANDYKE, M.D., Professor of Anatomy and Physiology, Grant Medical College, Bombay.

Digitized by Google

Elected

1876 CARTER, ROBERT BRUDENELL, Ophthalmic Surgeon to, and Lecturer on Ophthalmic Surgery at, St. George's Hospital, 69, Wimpole-street, Cavendish-square, W.

1879 CASSIDY, JOSEPH LAMONT, M.D., 82, Guilford-street, Russell-square, W.C.

1877 CASSON, JOHN HORNSEY, 47A, Portland-place.

†1868 CAVAFY, JOHN, M.D. (C.), Senior Assistant Physician to St. George's Hospital, 2, Upper Berkeley-street, Portman-square, W. (C. 1881.)

1864 CAY, CHARLES VIDLER, Smedleys, Matlock Bank, Derby.

1863 CAYLEY, WILLIAM, M.D., Physician to, and Lecturer on the Principles and Practice of Medicine at, the Middlesex Hospital, 58, Welbeck-street, Cavendish-square, W. (C. 1870-1, 1875-8. S. 1872-4.)

1869 CHAFFERS, EDWARD, Keighley, Yorkshire.

1849 CHALK, WILLIAM OLIVER, 3, Nottingham-terrace, Regent's-park, N.W. (C. 1856-7.)

1876 CHARLES, T. CRANSTOUN, M.D., M.C., Lecturer on Practical Physiology at St. Thomas's Hospital, 61, West Cornwall-road, South Kensington, S.W.

1870 CHEADLE, WALTER BUTLER, M.D., Physician (with charge of Out-patients) to St. Mary's Hospital, and Physician to the Hospital for Sick Children, Great Ormond-street, 2, Hyde-park-place, Cumberland-gate, W.

1879 CHEYNE, WILLIAM WATSON, M.B., C.M., Assistant Surgeon to King's College Hospital, 6, Old Cavendish-street, W.

1858 CHILD, GILBERT W.

1873 CHISHOLM, EDWIN, M.D., Abergeldie, Ashfield, near Sydney, New South Wales.

1855 CHOLMELEY, WILLIAM, M.D., Physician to the Great Northern Hospital, and to the Margaret-street Infirmary for Consumption, 63, Grosvenor-street, W. (C. 1871-3.)

1871 CHRISTIE, THOMAS BEATH, M.D., Superintendent of the Royal India Asylum, Ealing, Middlesex.

1865 CHURCH, WILLIAM SELBY, M.D., Physician to St. Bartholomew's Hospital, 130, Harley-street, Cavendish-square, W. (C. 1871-3.)

†1868 CHURCHILL, FREDERICK, M.B., Assistant Surgeon to the Victoria Hospital for Children, 4, Cranley-gardens, Queen's-gate, S.W.

1861 CLAPTON, EDWARD, M.D., 10A, St. Thomas's-street, Southwark, S.E.

1854 CLARK, ANDREW, M.D. (V.-P.), Physician to the London Hospital, 16, Cavendish-square, W. (C. 1862-5. V.-P. 1881.)

1872 CLARK, ANDREW, Assistant Surgeon to the Middlesex Hospital, 19, Cavendish-place, W.

1881 CLARKE, W. BRUCE, M.B., 12, Buckingham-street, Strand, W.C.

1867 CLARKE, WILLIAM FAIRLIE, M.A., M.D., Southborough, Tunbridge Wells. (C. 1873-5.)

1875 CLARKSON, JOHN, Surgeon in the India Department, Bombay Presidency, India.

Digitized by Google

Elected

1875 CLUTTON, HENRY HUGH, M.A., Assistant Surgeon to St. Thomas's Hospital, 16, Palace-road, Albert-embankment, S.E.

‡1865 COATES, CHARLES, M.D., Physician to the Bath General and Royal United Hospitals, 10, Circus, Bath.

1856 COCKLE, JOHN, M.D., M.A., Physician to the Royal Free Hospital, 13, Spring-gardens, Charing-cross, S.W.

COLLEY, see DAVIES-COLLEY.

1879 COLLINS, WM. MAUNSELL, M.D., Surgeon, Scots Guards, 70A, Grosvenor-street, W.

1878 COLLYNS, R. T. POOLE, Atkinson Morley Hospital, Copse-hill, Wimbledon.

1858 COOKE, ROBERT THOMAS, Surgeon to the Scarborough Dispensary, 15, St. Nicholas-cliff, Scarborough, Yorkshire.

1871 COOKE, THOMAS, Assistant Surgeon to the Westminster Hospital, 16, Woburn-place, W.C.

1866 COOMBS, ROWLAND HILL, Mill-street, Bedford.

1879 COOPER, ARTHUR, 2, Henrietta-street, Cavendish-square, W.

1853 CORNISH, WILLIAM ROBERT, Surgeon-Major, Madras Army, Sanitary Commissioner for Madras.

1875 CORY, ROBERT, M.D., Assistant Obstetric Physician to St. Thomas's Hospital, 14, Palace-road, Albert-embankment, S.E.

1876 COTTLE, ERNEST WYNDHAM, M.A., Assistant Surgeon to the Hospital for Diseases of the Skin, Blackfriars, 3, Savile-row.

1859 COULSON, WALTER J., Surgeon to the Lock Hospital, 17, Harley-street, Cavendish-square, W.

†1861 COUPER, JOHN, Surgeon to the London Hospital, 80, Grosvenor-street, Grosvenor-square, W. (C. 1870-2.)

1873 COUPLAND, SIDNEY, M.D. (C.), Physician to, and Lecturer on Pathological Anatomy at, the Middlesex Hospital, 14, Weymouth-street, Portland-place. (C. 1878-81.)

1879 COWBURN, GEORGE HERBERT, late House Physician, St. George's Hospital, 1, Clevedon-villas, St. Thomas's, Exeter.

1873 CRIPPS, WILLIAM HARRISON, Surgical Registrar to St. Bartholomew's Hospital, 6, Stratford-place, Oxford-street, W.

O.M. CRISP, EDWARDS, M.D., 16, Beaufort-street, Chelsea, S.W. (C. 1846-7-V.-P. 1870-2.)

1848 CRITCHETT, GEORGE, Consulting Surgeon to the Royal London Ophthalmic Hospital, Moorfields, 21, Harley-street, W. (S. 1849. C. 1851, 1858-9. V.-P. 1866-7.)

1877 CROCKER, HENRY RADCLIFFE, M.D., Physician to the Skin Department, University College Hospital; Assistant Physician and Pathologist to the East London Hospital for Children, 28, Welbeck-street, Cavendish-square, W.

1856 CROFT, JOHN, Surgeon to St. Thomas's Hospital, 61, Brook-street, Grosvenor-square, W. (C. 1870-2.)

1879 CROOKE, GEORGE FREDERICK, M.B. [Gainsborough, Lincolnshire.]

1861 CROSBY, THOMAS BOOR, M.D., 21, Gordon-square, W.C.

Digitized by Google

Elected

1875 CROSS, FRANCIS RICHARDSON, 5, The Mall, Clifton, Bristol.

1871 CUMBERBATCH, ELKIN, Demonstrator of Anatomy at St. Bartholomew's Hospital, 17, Queen Anne-street, W.

1858 CUMBERBATCH, LAURENCE T., M.D., 25, Cadogan-place, Sloane-street, S.W.

1873 CURNOW, JOHN, M.D., Professor of Anatomy at King's College, and Assistant Physician to King's College Hospital, 3, George-street, Hanover-square, S.W.

‡1865 CURRAN, WILLIAM, M.D., Army Medical Staff. [Agent: Mr. H. K. Lewis, 136, Gower-street, W.C.]

1873 DAVIDSON, ALEXANDER, M.D., Physician to the Liverpool Royal Infirmary; Lecturer on Pathology at the Liverpool Medical School, 2, Gambier-terrace, Liverpool.

1869 DAVIES-COLLEY, J. NEVILLE C., M.B. (C.), Surgeon to Guy's Hospital, 36, Harley-street, Cavendish-square. (C. 1880-81.)

O.M. DAVIES, HERBERT, M.D., Consulting Physician to the London Hospital, and to the Infirmary for Asthma, 23, Finsbury-square, E.C. (C. 1849-50. V.-P. 1871.)

‡1859 DAVIS, FRANCIS WILLIAM, R.N., Surgeon to the Naval Medical Establishment, Lisbon. [Agents: Messrs. Hallett and Co., 7, St. Martin's-place, Trafalgar-square, W.C.]

1879 DAVY, HENRY, M.B., 34, Southernhay, Exeter.

1866 DAY, WILLIAM HENRY, M.D., Physician to the Samaritan Free Hospital for Women and Children, 10, Manchester-square, W.

1872 DECASTRO, JAMES C., M.B., Pau, France.

1871 DE LIEFDE TEMPLE, JOHN, M.D. [per Mr. James Nimmo, 7, Red Lion-court, Watling-street, E.C.].

1880 DENT, CLINTON T., Assistant Surgeon to St. George's Hospital, 29, Chesham-street, Belgrave-square, S.W.

1863 DEVEREUX, DANIEL, Tewkesbury, Gloucestershire.

1856 DICK, H., M.D.

1871 DICKINSON, EDWARD HARRIMAN, M.A. Oxon., M.D., Physician to the Liverpool Northern Hospital, and Lecturer on Comparative Anatomy at the Liverpool School of Medicine, 162, Bedford-street, Liverpool.

1858 DICKINSON, WILLIAM HOWSHIP, M.D., Physician to the Hospital for Sick Children, Physician and Lecturer on Medicine to St. George's Hospital, 9, Chesterfield-street, Mayfair, W. (C. 1866-8. S. 1869-71. V.-P. 1872-4.)

1872 DIVER, EBENEZER, M.D., Kenley, Caterham-valley, Surrey.

O.M. DIXON, JAMES, Consulting Surgeon to the Royal Ophthalmic Hospital, Moorfields; Harrowlands, Dorking, Surrey. (C. 1852-6. V.-P. 1860-2.)

Digitized by Google

Elected

1872 DORAN, ALBAN HENRY GRIFFITHS, Surgeon to Out-Patients, Samaritan Hospital; Pathological Assistant to Museum, Royal College of Surgeons, 51, Seymour-street, Portman-square, W.

†1866 DOWN, JOHN LANGDON H., M.D., Physician to, and Lecturer on Clinical Medicine at, the London Hospital, 81, Harley-street, Cavendish-square, W. (C. 1872-4.)

1872 DOWSE, THOMAS STRETCH, M.D., 14, Welbeck-street, Cavendish-square.

1880 DRESCHFELD, JULIUS, M.D., 292, Oxford-road, Manchester.

1879 DREWITT, F. G. DAWTREY, M.B., 14, Cottage-road, Chester-square, S.W.

1865 DUCKWORTH, DYCE, M.D., Assistant Physician to St. Bartholomew's Hospital, 11, Grafton-street, Bond-street, W. (C. 1877.)

1863 DUDFIELD, THOMAS ORME, M.D., 8, Upper Phillimore-place, Kensington, W.

1847 DUDGEON, ROBERT E., M.D., 53, Montagu-square, W.

1852 DUFF, GEORGE, M.D., High-street, Elgin.

1865 DUFFIN, ALFRED BAYNARD, M.D., Physician to King's College Hospital 18, Devonshire-street, Portland-place, W. (C. 1872-4.)

1875 DUKA, THEODORE, M.D., Surgeon-Major, H.M.'s Bengal Army; Torquay, Devonshire.

1868 DUKE, OLIVER THOMAS, M.B., India.

1871 DUKES, CLEMENT, M.D., B.S. Lond., Physician to Rugby School, Sunnyside, Rugby.

1877 DUNBAR, J. J. MACWHIRTER, Assistant House-Physician to St. George's Hospital, Argyle House, Clapham-common, S.W.

1877 DUNCAN, ANDREW, M.D., 8, Henrietta-street, Covent-garden, W.C.

1880 DUNCAN, JAS. MATTHEWS, M.D., Obstetric Physician to St. Bartholomew's Hospital, 71, Brook-street, Grosvenor-square, W.

1861 DUNN, ROBERT WILLIAM, 13, Surrey-street, Strand, W.C.

1858 DURHAM, ARTHUR EDWARD, Surgeon to Guy's Hospital, 82, Brook-street, Grosvenor-square, W. (C. 1869-71.)

1879 DURHAM, FREDERIC, M.B., 38, Brook-street, Grosvenor-square, W.

1880 EDMUNDS, WALTER, M.D., 1, Fairfax-road, South Hampstead, N.W.

1867 ELLIS, JAMES, M.D., California.

1873 ENGELMANN, GEORGE JULIUS, M.D., A.M., 3003, Locust-street, St. Louis, Miss., U.S.

1846 ERICHSEN, JOHN ERIC, F.R.S., Consulting Surgeon to University College Hospital, 6, Cavendish-place, Cavendish-square, W. (C. 1849-51. V.-P 1863-4.)

1853 EVANS, CONWAY, M.D., The Garden House, Clements-inn, W.C. (C. 1867-8.)

1873 EVANS, GEORGE HENRY, M.D.

Digitized by Google

Elected

1875 Evans, Julian, A.M., M.D., Physician to the Victoria Hospital for Sick Children, 123, Finboro'-road, Redcliffe-square, West Brompton, S.W.

1879 Eve, Frederic S., Curator of Museum, St. Bartholomew's Hospital, 14, Furnival's Inn, Holborn, W.C.

1876 Ewart, James Cossar, M.B., C.M., School of Medicine, Edinburgh.

1881 Ewart, Joseph, M.D., late Professor of Medicine at Calcutta Medical College, Montpellier Terrace, Brighton.

1877 Ewart, William, M.B., Assistant Physician to the Hospital for Consumption, Brompton, 33, Curzon-street, Mayfair, W.

‡1859 Ewens, John, Cotham Brow, Bristol.

1864 Fagge, Charles Hilton, M.D., Physician to, and Lecturer on Pathology at, Guy's Hospital, 11, St. Thomas's-street, Southwark, S.E. (C. 1870-2.)

1862 Farquharson, Robert, M.D., M.P., Migvie Lodge, Porchester-gardens, Hyde-park, W. (C. 1876-7.)

1872 Fayrer, Sir Joseph, K.C.S.I., M.D. F.R.S. Ed. (C.), Hon. Physician to the Queen, Surgeon-Major, Bengal Army, Examining Medical Officer to the Secretary of State for India in Council, 53, Wimpole-street, Cavendish-square, W. (C. 1880.)

1872 Fenn, Edward L., M.B., The Old Palace, Richmond, Surrey.

1880 Fenwick, Bedford, M.D., 29, Harley-street, Cavendish-square, W.

1872 Fenwick, John C. J., M.D., Physician to the Durham County Hospital, Chilton Hall, Ferry-hill, and 16, Old Elvet, Durham.

1863 Fenwick, Samuel, M.D., Physician, with charge of out-patients to, and Lecturer on Medicine at, the London Hospital, 29, Harley-street, W.

1846 Fincham, George T., M.D., Physician to the Westminster Hospital, 13, Belgrave-road, S.W. (C. 1855.)

1876 Finlay, David W., M.D., Assistant Physician to the Middlesex Hospital, 21, Montagu-street, Portman-square, W.

1870 Fish, John Crockett, M.D., 92, Wimpole-street, W.

1859 Fisher, Alexander, M.D., Assistant Surgeon, R.N., Her Majesty's Ship "Endymion."

1855 Flower, William H., F.R.S., Conservator of the Museum, Royal College of Surgeons, 39, Lincoln's-inn-fields, W.C. (C. 1862-4.)

1872 Forbes, Daniel Mackay, L.R.C.P. Ed., 204, Hoxton-street, N.

†O.M. Forster, John Cooper, 29, Upper Grosvenor-street, W. (C. 1857-8. V.-P. 1871-3.)

‡1866 Foster, Balthazar Walter, M.D., Physician to the General Hospital, Birmingham, 16, Temple-row, Birmingham.

1872 Fotherby, Henry J., M.D., Physician to the Metropolitan Free Hospital, 3, Finsbury-square, E.C.

1880 Fowler, James Kingston, B.A., M.B., 35, Clarges-street, Piccadilly, W.

1878 Fox, Thomas Colcott, M.B., B.A., 14, Harley-street, Cavendish-square, W.

Digitized by Google

Elected

1862 Fox, Wilson, M.D., Holme Professor of Clinical Medicine in University College, and Physician to University College Hospital, 67, Grosvenor-street, W. (C. 1868-70. V.-P. 1875-77.)

1858 Francis, Charles Richard, M.B., Bengal Medical Establishment, Indian Army.

O.M. Frere, J. C.

1864 Frodsham, John Mill, M.D., Streatham, S.W.

1880 Gabbett, Henry Singer, M.B., 33, Upper Bedford-place, W.C.

‡1858 Gairdner, William Tennant, M.D., Professor of Medicine in the University of Glasgow, 225, St. Vincent-street, Glasgow.

1870 Galton, Edmund H., Springfield House, Brixton-hill, S.W.

1870 Galton, John H., M.D., 1, Woodside, Anerley-road, Upper Norwood, S.E.

1855 Gamgee, Joseph Sampson, Consulting Surgeon to the Queen's Hospital, Birmingham, 20, Broad-street, Birmingham.

1855 Gamgee, J.

1877 Garlick, George, M.D., 33, Great James-street, Bedford-row, W.C.

1846 Garrod, Alfred Baring, M.D., F.R.S., Consulting Physician to King's College Hospital, 10, Harley-street, Cavendish-square, W (C. 1851. V.-P. 1863-5.)

1879 Garstang, Thomas Walter Harrop, Oakleigh, Dobcross, Manchester.

1872 Garton, William, Hardshaw-street, St. Helen's, Lancashire.

O.M. Gay, John, Senior Surgeon to the Great Northern Hospital, 34, Finsbury-place, E.C. (C. 1852-4. V.-P. 1870-2.)

1880 Gibbes, Heneage, M.B., 94, Gower-street, Bedford-square, W.

1853 Gibbon, Septimus, M.D., 39, Oxford-terrace, Hyde-park, W.

1878 Gibbons, R. A., M.D., Physician to the Infirmary for Consumption Margaret-street, 88, Cadogan-place, S.W.

1876 Gill, John, M.D., Newton Abbot, Devon.

1873 Godlee, Rickman John, M.B., B.S., Assistant Surgeon to University College Hospital; Demonstrator of Anatomy in University College; 81, Wimpole-street, Cavendish-square, W. (C. 1877-80.)

1875 Godson, Clement, M.D., Assistant Physician-Accoucheur to St. Bartholomew's Hospital, 9, Grosvenor-street, W.

1879 Godwin, Charles Henry Young, Surgeon Major, Army, 23, The Common, Woolwich.

1878 Golding-Bird, Cuthbert H., M.B., Assistant Surgeon to Guy's Hospital, 13, St. Thomas's-street, S.E.

1871 Goodhart, James Frederick, M.D., Assistant Physician to, and Teacher of Clinical Medicine at, Guy's Hospital, 27, Weymouth-street, Portland-place, W. (C. 1876-8.)

1875 Gould, Alfred Pearce, M.S., Assistant Surgeon to, and Lecturer on Anatomy at, the Westminster Hospital, 16, Queen Anne-street, W.

1870 Gowers, William Richard, M.D. (C.), Assistant Physician to University College Hospital, 50, Queen Anne-street, Cavendish-square, W. (C. 1878-9.)

Digitized by Google

Elected

1858 GOWLLAND, PETER Y., Surgeon to St. Mark's Hospital, 34, Finsbury-square, E.C.

1867 GREEN, T. HENRY, M.D. (C.), Physician to Charing Cross Hospital, Assistant Physician to the Hospital for Consumption, Brompton, 74, Wimpole-street, W. (C. 1871-3, 1878-9. S. 1875-6.)

1873 GREENFIELD, WILLIAM SMITH, M.D., B.S., Professor of General Pathology in the University of Edinburgh, 7, Heriot-row, Edinburgh. (C. 1877-80.)

‡1855 GREENHILL, WILLIAM ALEXANDER, M.D., Carlisle-parade, Hastings.

1863 GREENHOW, EDWARD HEADLAM, M.D., F.R.S., Consulting Physician to the Middlesex Hospital, Castle Lodge, Reigate. (C. 1867-9. V.-P. 1877-8.)

1876 GRIFFITHS, THOMAS D., M.D., Hearne Lodge, Swansea.

1861 GUENEAU DE MUSSY, HENRI, M.D., 15, Rue du Cirque, Paris.

1863 GULL, SIR WILLIAM WITHEY, Bart., M.D., D.C.L., F.R.S., Consulting Physician to Guy's Hospital, 74, Brook-street, Grosvenor-square, W.

1881 GULLIVER, GEORGE, M.B., Assistant Physician to St. Thomas's Hospital, S.E.

1880 GUNN, R. MARCUS, M.B., C.M., 108, Park-street, Grosvenor-square, W.

1876 GWYTHER, JAMES, M.B. Lond., St. Mary Church, Torquay.

1849-59 HABERSHON, SAMUEL OSBORNE, M.D., 70, Brook-street, Grosvenor-square, W. (Re-elected 1874.) (C. 1855-6.)

1851 HACON, E. DENNIS, 269, Mare-street, Hackney, N.E. (C. 1872.)

1879 HADDEN, WALTER BAUGH, M.D., Demonstrator of Morbid Anatomy at St. Thomas's Hospital, 7, Coventry-street, Piccadilly, W.

1877 HALLOWES, FREDERICK BLACKWOOD, Redhill, Surrey.

1848 HARE, CHARLES JOHN, M.D., late Physician to University College Hospital, 57, Brook-street, Grosvenor-square, W. (C. 1852-4. V.-P. 1874-7.)

†1856 HARLEY, GEORGE, M.D., F.R.S., 25, Harley-street, Cavendish-square, W. (C. 1862-5. V.-P. 1878-80.)

1872 HARRIS, HENRY, M.D., Trengweath-place, Redruth, Cornwall.

1879 HARRIS, VINCENT DORMER, M.D., Casualty Physician to St. Bartholomew's Hospital, 39, Wimpole-street, Cavendish-square, W.

†1858 HART, ERNEST, 38, Wimpole-street, Cavendish-square, W. (C. 1867-8.)

1870 HAWARD, JOHN WARRINGTON (C.), Surgeon to St. George's Hospital, 16, Savile-row, W. (C. 1879-81.)

O.M. HAWKINS, CÆSAR H., F.R.S., Consulting Surgeon to St. George's Hospital, 26, Grosvenor-street, W. (V.-P. 1846-51. *Pres.* 1852-3.)

1857 HAWKSLEY, THOMAS, M.D., Physician to the Margaret-street Dispensary for Consumption, 31, Grosvenor-street, W.

1856 HEATH, CHRISTOPHER (V.-P.), Holme Professor of Clinical Surgery in University College, and Surgeon to University College Hospital, 36, Cavendish-square, W. (C. 1866-7. V.-P. 1879-81.)

1881 HEBB, RICHARD G., M.D., 61, Torrington-square, W.C.

1878 HELLIER, JOHN B., M.B., Headingley, Leeds.

1879 HENDERSON, GEORGE COURTENAY, M.B., University College Hospital.

Digitized by Google

Elected

1869 HENSLEY, PHILIP J., M.D., Assistant Physician to St. Bartholomew's Hospital, 4, Henrietta-street, Cavendish-square, W.

‡1868 HESLOP, THOMAS P., M.D., Physician to the Children's Hospital, Birmingham.

O.M. HEWETT, PRESCOTT G., F.R.S., Consulting Surgeon to St. George's Hospital, 1, Chesterfield-street, Mayfair, W. (C. 1846-52. V.-P. 1854-7. *Pres.* 1863-4. V.-P. 1865-8.)

1855 HEWITT, GRAILY, M.D., Obstetric Physician to University College Hospital, 36, Berkeley-square, W. (C. 1865-7.)

1864 HICKMAN, WILLIAM, M.B., Surgeon to the Samaritan Free Hospital, 1, Dorset-square, N.W.

1860 HILL, M. BERKELEY, M.B., Surgeon to University College Hospital, and Surgeon for Out-Patients to the Lock Hospital, 55, Wimpole-street, Cavendish-square, W. (C. 1874-5.)

1875 HITCHCOCK, HARRY KNIGHT, M.D., Skibbereen, Branksome-park, Bournemouth, Hants.

1880 HOBSON, JOHN MORRISON, M.D., 3, Addiscombe-villas, Lower Addiscombe-road, Croydon.

1874 HOGGAN, GEORGE, M.B., 7, Trevor-terrace, Rutland-gate, S.W.

1847 HOLMAN, H. MARTIN, M.D., Hurstpierpoint, Sussex.

1854 HOLMES, TIMOTHY, Surgeon-in-Chief to the Metropolitan Police, Surgeon to St. George's Hospital, 18, Great Cumberland-place, Hyde-park, W. (C. 1862-3. S. 1864-7. C. 1868. V.-P. 1869-71.)

1850 HOLT, BARNARD WIGHT, Consulting Surgeon to the Westminster Hospital, 14, Savile-row, W. (C. 1853.)

O.M. HOLTHOUSE, CARSTEN. (C. 1852-4, V.-P. 1874-5.)

1878 HOOD, DONALD WILLIAM CHARLES, M.D., 43, Green-street, Park Lane.

1864 HOOD, WHARTON P., M.D., 65, Upper Berkeley-street, Portman-square, W.

1870 HOPE, WILLIAM, M.D., 56, Curzon-street, Mayfair, W.

1879 HORROCKS, PETER, M.D., 29, Merrick-square, S.E.

1877 HOUGHTON, WALTER B., M.D., Assistant Physician to Charing Cross Hospital, 26, Cavendish-square, W.

1880 HOVELL, T. MARK, 3, Mansfield-street, Portland-place, W.

1866 HOWARD, EDWARD, M.D.

1875 HOWSE, HENRY GREENWAY, M.S. (C.), Surgeon to Guy's Hospital, and to the Evelina Hospital for Sick Children, 10, St. Thomas's-street, S.E. (C. 1878-81.)

†1856 HUDSON, JOHN, M.D., 11, Cork-street, Bond-street, W.

1854 HULKE, JOHN WHITAKER, F.R.S., Surgeon to the Middlesex Hospital and Surgeon to the Royal London Ophthalmic Hospital, 10, Old Burlington-street, W. (C. 1863-5. S. 1868-72. V.-P. 1873-6, T. 1877-9.)

1854 HULME, EDWARD CHARLES, Woodbridge-road, Guildford.

1853 HUMBY, EDWIN, M.D., 83, Hamilton-terrace, St. John's Wood, N.W.

1874 HUMPHREYS, HENRY, M.D., late Physician to the Children's Hospital at Pendlebury, 9, St. Margaret's-terrace, St. Leonard's-on-Sea.

Digitized by Google

Elected

1852 HUTCHINSON, JONATHAN (V.-P.), Surgeon to the London Hospital, and to the Royal London Ophthalmic Hospital, Moorfields, 15, Cavendish-square, W. (C. 1856-9. V.-P. 1872-3, 1881. P. 1879-80.)

1880 INGRAM, ERNEST FORTESCUE, Chelsea Infirmary, Call-street, Chelsea.

1865 JACKSON, J. HUGHLINGS, M.D., Physician to the London Hospital, Physician to the National Hospital for the Paralysed and Epileptic, 3, Manchester-square, W. (C. 1872-3.)

1875 JALLAND, WILLIAM HAMERTON, St. Leonard's House, Museum-street, York.

‡1853 JARDINE, JOHN LEE, Capel, near Dorking, Surrey.

1847 JAY, EDWARD, 112, Park-street, Grosvenor-square, W.

O.M. JENNER, SIR WILLIAM, Bart., M.D., D.C.L., K.C.B., F.R.S., Consulting Physician to University College Hospital, 63, Brook-street, Grosvenor-square, W. (C. 1850-3. V.-P. 1862-4 1875-6. *Pres.* 1878-4

1881 JENNINGS, WILLIAM OSCAR, M.D., 8, Rue Roy, Paris.

1875 JESSETT, FREDERIC BOWREMAN, Pier-road, Erith, Kent.

1879 JESSOP, CHARLES MOORE, Army Medical Department, China.

1866 JESSOP, THOMAS RICHARD, 31, Park-square, Leeds.

1878 JOHNSON, ARTHUR JUKES, Yorkville, Ontario, Canada.

1876 JOHNSON, CHARLES HENRY, late Staff Surgeon, Turkish Contingent, Repton, Burton-on-Trent.

O.M. JOHNSON, GEORGE, M.D., F.R.S. (*Treasurer*), Physician to King's College Hospital, 11, Savile-row, W. (C. 1846-50. V.-P. 1863-4. T. 1880-81.)

1881 JOHNSTON, JOSEPH, M.D., Brigade Surgeon, Army Medical Department, St. John's Wood Barracks, N.W.

1854 JOHNSTONE, ATHOL A. W., St. Moritz House, 61, Dyke-road, Brighton.

1853 JONES, SYDNEY, M.B., Surgeon to St. Thomas's Hospital, 16, George-street, Hanover-square, W. (C. 1864-6.)

1862 JONES, THOMAS RIDGE, M.D., Physician to the Victoria Hospital for Sick Children, 4, Chesham-place, S.W.

1858 JONES, WILLIAM PRICE, M.D., Claremont-road, Surbiton, Kingston.

1867 KELLY, CHARLES, M.D., Professor of Hygiene, King's College, Strand, Broadwater-road, Worthing, Sussex. (C. 1874.)

1846 KENT, THOMAS J., 60, St. James's-street, S.W.

1852 KERSHAW, W. WAYLAND, M.D., Kingston-on-Thames.

1872 KESTEVEN, WILLIAM B., M.D. (C.), Little-park, Enfield, Middlesex. (C. 1879-81.)

1879 KESTEVEN, WILLIAM HENRY, 401, Holloway-road, N.

1859 KIALLMARK, HENRY WALTER, 5, Pembridge-gardens, Bayswater, W. (C. 1875-6.)

1867 KING, EDWIN HOLBOROW, Killcott, Godalming, Surrey.

1871 KING, ROBERT, M.B., Bargaly, Newton Stewart, N.B.

1852 KINGDON, J. ABERNETHY, Surgeon to the City Dispensary, and to the City of London Truss Society, 2, New Bank-buildings, Lothbury, E.C.

Digitized by Google

Elected

‡1856 KINGSLEY, HENRY, M.D., Physician to the Stratford Infirmary, Stratford, on-Avon, Warwickshire.

1878 KLEIN, EDWARD EMANUEL, M.D., F.R.S., 94, Philbeach-gardens, Warwick-road, Earl's Court, S.W.

1877 KNIGHT, CHARLES FREDERICK, 8, Northampton-square, Clerkenwell, E.C.

1875 LACY, C. S. DE LACY, 5, Ovington-square, Brompton, S.W.

1878 LANCEREAUX, ETIENNE, M.D., 3, Rue St. Arnaud, Paris.

‡1865 LANCHESTER, HENRY THOMAS, M.D., 53, High-street, Croydon.

1877 LANG, ALEXANDER, M.B. [41, Warwick-road, S.W.]

1851 LANGMORE, JOHN C., M.B., 20, Oxford-terrace, Hyde-park, W. (C. 1858-61.)

1865 LANGTON, JOHN, Surgeon to, and Lecturer on Anatomy at, St. Bartholomew's Hospital, and Surgeon to the City of London Truss Society, 2, Harley-street, Cavendish-square, W.

1869 LARCHER, O., M.D. Par., Laureate of the Institute of France, of the Medical Faculty and Academy of Paris, 97, Rue de Passy, Paris. [M. Kliensieck, Libraire, Rue de Lille, 11, Paris, per Messrs. Longman.]

1873 LATHAM, PETER WALLWORK, M.D., Physician to Addenbrooke Hospital and Downing Professor of Medicine, Cambridge University, 17, Trumpington-street, Cambridge.

1876 LAW, WILLIAM THOMAS, M.D., 20, Warrior Gardens, St. Leonards-on-Sea.

1853 LAWRENCE, HENRY JOHN HUGHES, Surgeon, Grenadier Guards' Hospital, Rochester-row, Westminster, S.W. (C. 1873-5.)

1859 LAWSON, GEORGE, Surgeon to the Middlesex Hospital, and Surgeon to the Royal London Ophthalmic Hospital, Moorfields, 12, Harley-street, Cavendish-square, W. (C. 1870-1.)

1879 LAYCOCK, GEORGE LOCKWOOD, M.B., 12, Upper Berkeley-street, Portman-square, W.

1875 LEDIARD, HENRY AMBROSE, M.D., Surgeon to the Cumberland Infirmary 78, Lowther-street, Carlisle.

1852 LEE, HENRY, Consulting Surgeon to St. George's Hospital, 9, Savile-row, W. (C. 1860-2. V.-P. 1875-6.)

1879 LEECH, DANIEL JOHN, M.D., 96, Mosley-street, Manchester.

1877 LEES, DAVID B., M.D., Assistant Physician to St. Mary's Hospital, and to the Hospital for Sick Children, 2, Thurloe Houses, Thurloe-square, S.W.

1867 LEES, JOSEPH, M.D., 21, Brixton-road, S.W.

1877 LEESON, JOHN RUDD, M.B., C.M., 6, Clifden-road, Twickenham.

1868 LEGG, JOHN WICKHAM, M.D., Assistant Physician to, and Lecturer on Pathological Anatomy at, St. Bartholomew's Hospital, 47, Green-street, Park-lane, W. (C. 1874-5.)

‡1867 LEUDET, T. EMILE, M.D. Par., Professor of Clinical Medicine, 49, Boulevard Cauchoise, Rouen, France. [M. Kliensieck, Libraire, Rue de Lille 11, Paris, per Messrs. Longman.]

Digitized by Google

Elected

1861 LICHTENBERG, GEORGE, M.D., 47, Finsbury-square, E.C.

1875 LINGARD, ALFRED, 2, Palace-road, Albert Embankment, S.E.

1877 LISTER, JOSEPH, D.C.L., LL.D., F.R.S., (C.) Professor of Clinical Surgery at King's College, and Surgeon to King's College Hospital, 12, Park Crescent, Regent's Park, W. (C. 1880-1.)

1878 LITTLEJOHN, SALTER G., M.B., C.M., Central London District Schools, Hanwell.

1848 LITTLE, WILLIAM JOHN, M.D., 18, Park-street, Grosvenor-square, W. (C. 1851-2. V.-P. 1856-9.)

†1862 LITTLE, LOUIS S., China. [18, Park-street.]

1874 LIVEING, EDWARD, M.D., 52, Queen Anne-street, Cavendish-square, W.

1863 LIVEING, ROBERT, M.D., Physician to the Skin Department and Lecturer on Dermatology at the Middlesex Hospital, 11, Manchester-square, W. (C. 1876.)

1876 LONGHURST, ARTHUR EDWIN TEMPLE, M.D., 22, Wilton-street, Grosvenor-place, S.W.

1881 LUBBOCK, MONTAGU, M.D., 19, Grosvenor-street, W.

1873 LUCAS, R. CLEMENT, M.B., M.S., Assistant Surgeon to Guy's Hospital 18, Finsbury-square, E.C.

1880 LUND, EDWARD, 22, St. John-street, Manchester.

1879 LUNN, JOHN REUBEN, Resident Medical Officer, New Marylebone Infirmary, Rackham-street, Ladbroke-grove-road, Notting-hill, W.

1876 LYELL, ROBERT WISHART, M.D., Assistant Surgeon to the Middlesex Hospital, and to the Royal London Ophthalmic Hospital, 26, Harley-street, Cavendish-square, W.

1871 MCCARTHY, JEREMIAH, M.A., Surgeon to the London Hospital, 15, Finsbury-square, E.C. (C. 1878-80.)

1873 MCCONNELL, J. F., Professor of Pathology, Medical College, Calcutta. [Per Grindlay & Co., Parliament-street.]

1871 MAC CORMAC, WILLIAM, Surgeon to St. Thomas's Hospital, 13, Harley-street, W. (C. 1878-80.)

1875 MACKELLAR, ALEXANDER OBERLIN, Assistant Surgeon, St. Thomas's Hospital, 22, George-street, Hanover-square, W.

1873 MACKELLAR, PETER H., M.B., Medical Officer, Fever Hospital, Stockwell, S.W.

1870 MACKENZIE, GEORGE WELLAND, 13, William-street, Lowndes-square, S.W.

1870 MACKENZIE, JOHN T., Bombay, India. [East India United Service Club, 14, St. James's-square.]

1864 MACKENZIE, MORELL, M.D., Physician to the Hospital for Diseases of the Throat, and Lecturer on Diseases of the Throat at the London Hospital, 19, Harley-street, Cavendish-square, W.

1878 MACKENZIE, STEPHEN, M.D., Physician (with care of out-patients) to and Lecturer on Medicine at, the London Hospital, 26, Finsbury-square, E.C.

1879 MACLAGAN, THOMAS JOHN, M.D., 9, Cadogan-place, Belgrave-square, S.W.

1865 MACLAURIN, H. N., M.D.

Digitized by Google

Elected

1876 MACLEAN, THOMAS EDWIN, M.B., B.S.

1879 MACMAHON, JAMES THOMAS, L.K.Q.C.P.I., Beaumont Lodge, Howard-road, South Norwood, S.E.

1876 MACNAMARA, CHARLES, Surgeon to the Westminster Hospital, 13, Grosvenor-street, W.

1879 MACREADY, JONATHAN FORSTER, 125, Harley-street, W.

1875 MAHOMED, FREDERICK AKBAR, M.D., Medical Registrar, Guy's Hospital, 12, St. Thomas's-street, S.E.

1877 MAKINS, GEORGE HENRY, Blackheath-park, S.E.

1876 MALLAM, BENJAMIN, Meadow Side, Leacroft-road, Staines.

1876 MAPLES, REGINALD, Spalding, Lincolnshire.

1857 MARCET, WILLIAM, M.D., F.R.S., 39, Grosvenor-street, W. (C. 1869-71.)

1868 MARSH, F. HOWARD, Assistant Surgeon to the Hospital for Sick Children, Assistant Surgeon to St. Bartholomew's Hospital, 36, Bruton-street, Berkeley-square. (C. 1876-7.)

1876 MARSHALL, FRANCIS JOHN, St. George's Hospital.

1846 MARSHALL, JOHN, F.R.S., Surgeon to University College Hospital, 10, Savile-row, W. (C. 1861.)

1856 MARTIN, ROBERT, M.D., Consulting Physician to St. Bartholomew's Hospital, 51, Queen Anne-street, Cavendish-square, W. (C. 1871-2.)

1860 MASON, FRANCIS, Surgeon to St. Thomas's Hospital, 5, Brook-street, Grosvenor-square, W. (C. 1873-5.)

1867 MASON, PHILIP BROOKES, Burton-on-Trent.

†1852 MAY, GEORGE, Jun., M.B., Surgeon, Royal Berkshire Hospital, Reading.

1881 MAYLARD, ALFRED ERNEST, M.B., 8, Addiscombe-villas, Croydon, Surrey.

1874 MEREDITH, WILLIAM APPLETON, M.B., Assistant Surgeon to the Samaritan Hospital, 14, Old Burlington-street, W.

1859 MESSER, JOHN COCKBURN, M.D., Assistant Surgeon, R.N., Her Majesty's Ship "Edinburgh," Queensferry, N.B.

‡1867 MICKLEY, ARTHUR GEORGE, M.B., Resident Medical Officer, St. Mary's Infirmary, St. John's-road, Upper Holloway.

1866 MICKLEY, GEORGE, M.A., M.B., St. Luke's Hospital, Old-street, E.C.

1877 MILNER, EDWARD, Surgeon to the Lock Hospital, 32, New Cavendish-street, Portland-place, W.

†1859 MONTEFIORE, NATHANIEL, 18, Portman-square, W.

1879 MOORE, NORMAN, M.D., Demonstrator of Morbid Anatomy and Warden of the College; the College, St. Bartholomew's Hospital.

1881 MOORE, THOMAS, 6, Lee-terrace, Blackheath, S.E.

1861 MOREHEAD, CHARLES, M.D., 11, North Manor-place, Edinburgh.

1847 MORGAN, JOHN, 3, Sussex-place, Hyde-park-gardens, W. (C. 1856-8.)

1875 MORGAN, JOHN H., Assistant Surgeon to the Charing Cross Hospital, and to the Hospital for Sick Children, Great Ormond-street, 12, Chapel-street, Grosvenor-square, W.

1874 MORISON, ALEXANDER, M.B., C.M., 7, The Terrace, Green-lanes, N.

1880 MORISON, BASIL GORDON, M.B., C.M., 70, Marquess-road, Canonbury, N.

Digitized by Google

Elected

1869 MORRIS, HENRY, M.A., M.B. (HON. SECRETARY), Surgeon to, and Lecturer on Surgery at, the Middlesex Hospital, 2, Mansfield-street, Portland-place, W. (C. 1877-9. S. 1881.)

1879 MORRIS, MALCOLM ALEXANDER, Lecturer on Skin Diseases at St. Mary's Hospital, 63, Montagu-square, W.

1875 MORTON, JOHN, M.B., Guildford.

1879 MOULLIN, CHARLES W. MANSELL, M.D., 17, George-street, Hanover-square, W.

1860 MOXON, WALTER, M.D., Physician to Guy's Hospital, 6, Finsbury-circus E.C. (C. 1868-70, V.P. 1876-8.)

1878 MUMFORD, WILLIAM LUGAR, M.D., 1, Bartlett's-passage, Holborn-circus, E.C.

1876 MUNRO, WILLIAM, M.D., C.M., 102, Carl-street, Lower Broughton-road, Manchester.

1872 MURRAY, J. JARDINE, 99, Montpellier-road, Brighton.

1864 MYERS, ARTHUR B. R., Surgeon to 1st Battalion Coldstream Guards, the Hospital, Vincent-square, Westminster, S.W. (C. 1872-3.)

1874 NANKIVELL, ARTHUR WOLCOT, St. Bartholomew's Hospital, Chatham.

1873 NETTLESHIP, EDWARD, Ophthalmic Surgeon to St. Thomas's Hospital, 4, Wimpole-street, Cavendish-square, W.

1875 NEWBY, CHARLES HENRY, 87, Adelaide-road, N.W.

1865 NEWMAN, WILLIAM, M.D., Stamford, Lincolnshire.

1868 NICHOLLS, JAMES, M.D., Chelmsford, Essex.

1876 NICHOLSON, JOHN FRANCIS, M.D., Physician to the Hull General Infirmary, 29, Albion-street, Hull.

1878 NOOTT, W. M., 8, Kensington-park-road, W.

1864 NORTON, ARTHUR T., Surgeon to St. Mary's Hospital, 6, Wimpole-street, Cavendish-square, W. (C. 1877-9.)

1856 NUNN, THOMAS WILLIAM, Consulting Surgeon to the Middlesex Hospital, 8, Stratford-place, Oxford-street, W. (C. 1864-6. V.-P. 1878-80.)

1871 NUNNELEY, REV. FREDERICK BARHAM, M.D.

1880 O'CONNOR, BERNARD, M.D., 40, Brook-street, Grosvenor-square, W.

1873 O'FARRELL, GEORGE PLUNKETT, M.B., Tangier House, Boyle, Ireland.

1880 OGILVIE, GEORGE, M.B., Lecturer on Experimental Physics at the Westminster Hospital, 27, Welbeck-street, Cavendish-square, W.

1880 OGILVIE, LESLIE, M.B., Lecturer on Comparative Anatomy at the Westminster Hospital, 40, Weymouth-street, Portland-place, W.

1850 OGLE, JOHN W., M.D., Consulting Physician to St. George's Hospital, 30, Cavendish-square, W. (C. 1855-6. S. 1857-60. C. 1861-3. V.-P. 1865-8.)

1876 OLIVER, JOHN FERENS, M.D., 12, Old Elvet, Durham.

1860 ORANGE, WILLIAM, M.D., Broadmoor, Wokingham, Berkshire.

1875 ORD, WILLIAM MILLER, M.D. (C.), Physician to, and Lecturer on Medicine at, St. Thomas's Hospital, 7, Brook-street, Hanover-square, W. (C. 1880.)

Digitized by Google

Elected

1878 Orlebar, Hotham George, M.D., 11, Pevensey-road, St. Leonard's-on-Sea.

1879 Ormerod, J. A., M.B., Casualty Physician to St. Bartholomew's Hospital, 25, Upper Wimpole-street, W.

1875 Osborn, Samuel, 10, Maddox-street, Bond-street, W.

1876 Ottley, Walter, M.B., 93, Ladbroke-grove, Notting-hill, W.

1881 Owen, Isambard, M.B., Curator of Museum, St. George's Hospital, 41, Gloucester-gardens, W.

1865 Owles, James Allden, M.D., 204, Burlington-street, Liverpool.

1875 Page, Herbert William, M.A., M.C. Cantab., Surgeon (with charge of out-patients) to and Lecturer on Operative and Practical Surgery at St. Mary's Hospital, 146, Harley-street, Cavendish-square, W.

1870 Paget, Sir James, Bart., D.C.L., F.R.S., Consulting Surgeon to St. Bartholomew's Hospital, 1, Harewood-place, Hanover-square, W.

1872 Parker, Robert William (C.), Assistant Surgeon to the East London Children's Hospital, 8, Old Cavendish-street, W. (C. 1881.)

1874 Parker, Rushton, M.B., B.S., Professor of Surgery in University College, Liverpool, and Assistant Surgeon to the Royal Infirmary, 69, Rodney-street, Liverpool.

1853 Parkinson, George, 50, Brook-street, Grosvenor-square, W.

1865 Pavy, Frederick William, M.D., F.R.S., Physician to, and Lecturer on Medicine at, Guy's Hospital, 35, Grosvenor-street, W. (C. 1872-4.)

1868 Payne, Joseph Frank, B.A., M.D. (Hon. Secretary), Assistant Physician to, and Lecturer on Pathological Anatomy at, St. Thomas's Hospital, 78, Wimpole-street, Cavendish-square, W. (C. 1873-5. S. 1880-1.)

O.M. Peacock, Thomas Bevill, M.D. (Trustee), Consulting Physician to St. Thomas's Hospital, and Consulting Physician to the City of London Hospital for Diseases of the Chest, 20, Finsbury-circus, E.C. (C. 1846-9. S. 1850-1. V.-P. 1852-6. C. 1858-61. P. 1865-6. V.-P. 1867-70.)

1872 Pearce, Joseph Chaning, M.D., C.M., The Manor House, Brixton-rise, S.W.

1878 Pearse, Thomas Frederick, M.D., Bramshott, Liphook, Hants.

1863 Pearson, David R., M.D., 23, Upper Phillimore-place, Kensington, W.

1879 Peel, Robert, 130, Collins-street East, Melbourne, Victoria.

1878 Philipps, Sutherland Rees, M.D., 3, Berkeley-place, Cheltenham.

1871 Phillips, Charles Douglas F., M.D., 2, Grosvenor-square, W.

1878 Phillips, John Walter, Physician to the Benevolent Asylum of Melbourne, 30, Stanley-street, West Melbourne, Victoria.

1877 Phillips, Richard, 27, Leinster-square, Bayswater, W.

1875 Philpot, Harvey John.

1863 Pick, Thomas Pickering, Surgeon to, and Lecturer on Anatomy at, St. George's Hospital, 13, South Eaton-place, S.W. (C. 1870-1.)

1867 Pitt, Edward G., M.D.

1876 Pitts, Bernard, M.A., M.B., Resident Assistant Surgeon, St. Thomas's Hospital, S.E.

1846 Pollock, George D. (Trustee), Consulting Surgeon to St. George's

Digitized by Google

Elected

Hospital, 36, Grosvenor-street, W. (S. 1850-3. C. 1854-6. V.-P. 1863-5. P. 1875-6.)

1850 POLLOCK, JAMES EDWARD, M.D. (V.-P.), Physician to the Hospital for Consumption and Diseases of the Chest, Brompton, 52, Upper Brook-street, W. (C. 1862-4. V.-P. 1879-81.)

1870 POORE, GEORGE VIVIAN, M.D., Assistant Physician to University College Hospital, 30, Wimpole-street, W.

1876 PORT, HEINRICH, M.D., 48, Finsbury-square, E.C.

1879 POTTER, HENRY PERCY, Kensington Infirmary, 49, Church-street, Kensington.

1866 POWELL, RICHARD DOUGLAS, M.D. (C.), Physician to the Middlesex Hospital; Physician to the Hospital for Consumption and Diseases of the Chest, Brompton, 15, Henrietta-street, Cavendish-square, W. (C. 1873-5, 1881. S. 1877-9.)

1865 POWER, HENRY, Ophthalmic Surgeon to St. Bartholomew's Hospital, 37A, Great Cumberland-place, Hyde-park, W. (C. 1876-7.)

1856 PRIESTLEY, WILLIAM OVEREND, M.D., Consulting Physician-Accoucheur to King's College Hospital, and to the St. Marylebone Infirmary, 17, Hertford-street, Mayfair, W.

†1848 PURNELL, JOHN JAMES, Surgeon to the Royal General Dispensary, Woodlands, Streatham-hill, S.W. (C. 1858-61.)

1865 PYE-SMITH, PHILIP HENRY, M.D., Assistant Physician to, and Lecturer on Physiology at, Guy's Hospital, 56, Harley-street, Cavendish-square, W. (C. 1874-7.)

O.M. QUAIN, RICHARD, M.D., F.R.S. (TRUSTEE), Consulting Physician to the Hospital for Consumption and Diseases of the Chest, Brompton, 67, Harley-street, Cavendish-square, W. (C. 1846-51. S. 1852-6. T. 1857-68. *Pres.* 1869-70. V.-P. 1871-3.)

1859 RADCLIFFE, CHARLES BLAND, M.D., Physician to the Westminster Hospital, 25, Cavendish-square, W.

1872 RALFE, CHARLES HENRY, M.D., M.A., Assistant Physician to the London Hospital, 26, Queen Anne-street, W. (C. 1877-9.)

1857 RAMSKILL, J. SPENCE, M.D., Consulting Physician to the London Hospital, Physician to the National Hospital for the Paralysed and Epileptic, 5, St. Helen's-place, Bishopsgate-street, E.C.

1848 RANDALL, JOHN, M.D., Medical Officer, St. Marylebone Infirmary, 35, Nottingham-place, W. (C. 1864-6.)

1875 RANGER, W. GILL, 4, Finsbury-square, E.C.

1857 RANKE, HENRY, M.D., Munich.

1865 RASCH, ADOLPHUS A., M.D., Physician for Diseases of Women to the German Hospital, 7, South-street, Finsbury-square, E.C.

1870 RAY, EDWARD REYNOLDS, Dulwich, S.E.

1871 RAYNER, HENRY, M.D., Lecturer on Mental Diseases at St. Thomas' Hospital, Medical Superintendent, Middlesex County Lunatic Asylum, Hanwell W.

Digitized by Google

Elected

1858 REED, FREDERICK GEORGE, M.D., 46, Hertford-street, Mayfair, W.

1866 REEVES, HENRY ALBERT, Assistant Surgeon to the London Hospital, 6, Grosvenor Street, W.

1875 REID, ROBERT WILLIAM, M.D., C.M., Lecturer on Anatomy at St. Thomas's Hospital, 10, Nottingham-place, W.

1881 RENNER, WILLIAM, M.R.C.S., Wilberforce-street, Free Town, Sierra Leone.

1854 REYNOLDS, J. RUSSELL, M.D., F.R.S., Consulting Physician to University College Hospital, 38, Grosvenor-street, W. (C. 1868-9.)

1871 RICHARDS, J. PEEKE, Medical Superintendent, Middlesex County Lunatic Asylum, Hanwell, W.

1866 RIVINGTON, WALTER, M.S. Lond., Surgeon to the London Hospital, 22, Finsbury-square, E.C.

‡1865 ROBERTS, DAVID LLOYD, M.D., Physician to St. Mary's Hospital, Manchester, 23, St. John's-street, Manchester.

1871 ROBERTS, FREDERICK THOMAS, M.D., Professor of Materia Medica at University College, and Physician to University College Hospital, and to the Hospital for Consumption, &c., Brompton, 53, Harley-street, Cavendish-square, W.

1878 ROBERTS, WILLIAM HOWLAND, M.D., Surgeon, Madras Army, Madras, [East India United Service Club, St. James's Square].

1856 ROBINSON, THOMAS, M.D., 5, Woburn-square, W.C.

1876 ROPER, ARTHUR, 17, Granville Park, Blackheath, S.E.

1858 ROSE, HENRY COOPER, M.D., Surgeon to the Hampstead Dispensary, High-street, Hampstead, N.W. (C. 1873-4.)

1876 ROSE, WILLIAM, M.B., B.S., Assistant Surgeon to King's College, 21, Welbeck Street, Cavendish-square, W.

1879 ROSS, JAMES, M.D., C.M., 335, Oxford-street, Manchester.

1875 ROSSITER, GEORGE FREDERICK, 14, Melina-crescent, Weston-super-Mare.

1877 ROTH, BERNARD, M.S., 48, Wimpole Street, Cavendish-square, W., and Rossmore, Preston-road, Brighton.

1858 ROUSE, JAMES, Surgeon to St. George's Hospital, 2, Wilton-street, Grosvenor-place, S.W.

1869 RUTHERFORD, WILLIAM, M.D., F.R.S., Professor of Physiology in the University of Edinburgh, 14, Douglas Crescent, Edinburgh.

1853 SALTER, S. JAMES A., M.B., F.R.S. (V.-P.), Late Dental Surgeon to Guy's Hospital, Basingfield, near Basingstoke, Hants. (C. 1861-3. V.-P. 1880-1.)

1852 SANDERSON, HUGH JAMES, M.D., 26, Upper Berkeley-street, Portman-square, W.

1854 SANDERSON, JOHN BURDON, M.D., F.R.S., Jodrell Professor of Human Physiology at University College (C. 1864-7. V.-P. 1873-4.), 26, Gordon-square, W.C.

1877 SANGSTER, ALFRED, M.B., B.A., 7, Old Burlington-street, W.

1875 SANGSTER, CHARLES, 148, Lambeth-road, S.E.

Digitized by Google

Elected

1877 SANKEY, H. R. O., Sandywell-park, near Cheltenham.

‡1847 SANKEY, W. H. OCTAVIUS, M.D., Sandywell-park, near Cheltenham. (C. 1855.)

1871 SAUNDERS, CHARLES EDWARD, M.D., 21, Lower Seymour-street, Portman-square, W.

1873 SAVAGE, GEORGE HENRY, M.D. (C.), Bethlem Royal Hospital, St. George's-road, S.E. (C. 1881.)

1854 SCOTT, JOHN, 10, Tavistock-square, W.C.

1877 SEMON, FÉLIX, M.D., 59, Welbeck-street, Cavendish-square.

1852 SEMPLE, ROBERT HUNTER, M.D., Physician to the Bloomsbury Dispensary, 8, Torrington-square, W.C. (C. 1859-61.)

1872 SERGEANT, EDWARD, Medical Officer of Health, Town Hall, Bolton, Lancashire.

1876 SHARKEY, SEYMOUR, M.B., Assistant Physician and Demonstrator of Morbid Anatomy to St. Thomas's Hospital, 16, Palace-road, Albert Embankment, S.E.

1880 SHATTOCK, S. G., Curator, University College Museum, 9, Downshire-hill, Hampstead.

1877 SHEPPARD, CHARLES E., Rotherwood, Oakhill-road, Putney.

1856 SHILLITOE, BUXTON, Surgeon to the Great Northern Hospital, and to the Lock Hospital, 2, Frederick's-place, Old Jewry, E.C.

1855 SIBLEY, SEPTIMUS W. (V.-P.), 7, Harley-street, Cavendish-square, W. (C. 1863-5. V.-P. 1879-81.)

1875 SIDDALL, JOSEPH BOWER, M.D., C.M., Duxmere-house, Ross, Herefordshire.

1847 SIEVEKING, EDWARD H., M.D., Physician to St. Mary's Hospital, 17, Manchester-square, W. (C. 1854-7. V.-P. 1864-5.)

1880 SILCOCK, A. QUARRY, M.B., B.S., University College Hospital.

O.M. SIMON, JOHN, C.B., D.C.L., F.R.S., Consulting Surgeon to St. Thomas's Hospital, 40, Kensington-square, W. (C. 1846-8. V.-P. 1855-9. *Pres.* 1867-8. V.-P. 1869-71.)

1866 SIMS, FRANCIS MANLEY BOLDERO, Assistant Surgeon to the Hospital for Diseases of the Skin, and Surgeon to the St. George's Dispensary, 12, Hertford-street, May-fair, W.

1865 SIMS, J. MARION, M.D., 267, Madison-avenue, New York.

1877 SKINNER, WILLIAM A., 45, Upper Belgrave-street, S.W.

1875 SMEE, ALFRED HUTCHINSON, The Grange, Hackbridge, Carshalton, Surrey.

1879 SMITH, E. NOBLE, 24, Queen Anne-street, Cavendish-square.

1872 SMITH, GILBART, M.D., Assistant Physician to the London Hospital, Physician to the Royal Hospital for Diseases of the Chest, City-road, Visiting Physician to the Margaret-street Infirmary for Consumption, 68, Harley-street, Cavendish-square, W.

1875 SMITH, GEORGE JOHN MALCOLM, M.B., Hurstpierpoint, Sussex.

1863 SMITH, HENRY, Surgeon to, and Professor of Surgery at, King's College Hospital, 82, Wimpole-street, Cavendish-square, W. (C. 1873-4.)

Digitized by Google

Elected

1866 SMITH, HEYWOOD, M.D., Physician to the Hospital for Women, 18, Harley-street, Cavendish-square, W.

SMITH (P. H. PYE), see PYE-SMITH.

1846 SMITH, PROTHEROE, M.D., Physician to the Hospital for Women, 42, Park-street, Grosvenor-square, W.

1873 SMITH, RICHARD T., M.D., Physician to the St. Pancras Dispensary, 53, Haverstock-hill, N.W.

1869 SMITH, ROBERT SHINGLETON, M.D., Lecturer on Physiology, Bristol Medical School, 9, Richmond-hill, Clifton, Bristol.

1878 SMITH, HERBERT URMSON, M.B., Cape Colony.

1879 SMITH, ROBERT, M.A., M.D., Assistant Physician to Charing Cross Hospital, W.C.

1856 SMITH, THOMAS, Surgeon to St. Bartholomew's Hospital, 5, Stratford-place, Oxford-street, W. (C. 1867-9. V.-P. 1877-8.)

1866 SMITH, WILLIAM, Melbourne, Australia.

1870 SMITH, WILLIAM JOHNSON (C.), Surgeon, Seamen's Hospital, Greenwich, S.E. (C. 1879-81.)

1869 SMITH, WILLIAM WILBERFORCE, M.D., 2, Eastbourne-terrace, Bishop's-road, W.

1870 SNOW, WILLIAM VICARY, M.D., Richmond Gardens, Bournemouth.

1868 SOUTHEY, REGINALD, M.D., Physician to St. Bartholomew's Hospital, 6, Harley-street, Cavendish-square, W.

1868 SPRY, G. FREDERICK HUME, M.D., 2nd Life Guards, Army and Navy Club, Pall-mall, S.W.

1855 SQUIRE, WILLIAM, M.D., 6, Orchard-street, Portman-square, W. (C. 1870-2.)

1861 SQUIRE, ALEXANDER BALMANNO, 24, Weymouth-street, Portland-place, W.

1876 STARTIN, JAMES, 17, Sackville-street, Piccadilly, W.

1854 STEWART, WILLIAM EDWARD, 16, Harley-street, Cavendish-square, W.

1879 STIRLING, EDWARD CHARLES, Adelaide, South Australia.

†1853 STREATFEILD, J. F., Surgeon to the Royal London Ophthalmic Hospital, Moorfields, and Ophthalmic Surgeon to University College Hospital, 15, Upper Brook-street, W.

1875 STURGE, W. A., M.D., Nice, Alpes Maritimes, France.

1863 STURGES, OCTAVIUS, M.D., Physician to the Westminster Hospital, 85, Wimpole-street, Cavendish-square, W.

1871 SUTHERLAND, HENRY, M.D., 6, Richmond-terrace, Whitehall, S.W.

1876 SUTRO, SIGISMUND, M.D., Senior Physician to the German Hospital, 37A, Finsbury-square, E.C.

1864 SUTTON, HENRY G., M.B., Physician to and Lecturer on Pathology at, the London Hospital, Physician to the City of London Hospital for Diseases of the Chest, 9, Finsbury-square, E.C. (C. 1875-6.)

‡1867 SWAIN, WILLIAM PAUL, 20, Ker-street, Devonport.

1881 SYMONDS, CHARTERS JAMES, M.S., 16, St. Thomas's-street, S.E.

Digitized by Google

Elected

1870 TAIT, ROBERT LAWSON, Surgeon to the Birmingham and Midland Hospital for Women, 7, Great Charles-street, Birmingham.

1864 TATHAM, JOHN, M.D., Physician to the Hospital for Consumption and Diseases of the Chest, Brompton, 12, George-street, Hanover-square, W.

1870 TAY, WAREN (C.), Surgeon to, and Demonstrator of Practical Anatomy at, the London Hospital, 4, Finsbury-square, E.C. (C. 1881.)

1871 TAYLOR, FREDERICK, M.D. (C.), Assistant Physician to Guy's Hospital, 15, St. Thomas's-street, S.E. (C. 1879-81.)

1880 TAYLOR, SEYMOUR, M.B., M.C., 140, South Lambeth-road.

1861 TEEVAN, WILLIAM FREDERIC, Surgeon to the West London Hospital, 10, Portman-square, W.

1879 THIN, GEORGE, M.D., 22, Queen Anne-street, Cavendish-square, W.

1870 THOMAS, JOHN DAVIES, M.B., University College Hospital (India).

1852 THOMPSON, SIR HENRY, Knt., Emeritus Professor of Clinical Surgery in University College, 35, Wimpole-street, Cavendish-square, W. (S. 1859-63. C. 1865-67. V.-P. 1868-70.)

1874 THORNTON, JOHN KNOWSLEY, M.B., Surgeon to the Samaritan Free Hospital for Women and Children, 22, Portman-street, Portman-square.

1872 THORNTON, WILLIAM PUGIN, Surgeon to the Hospital for Diseases of the Throat, and to the St. Marylebone General Dispensary, 42, Devonshire-street, Portland-place, W.

1865 THOROWGOOD, J. C., M.D., Lecturer on Materia Medica at the Middlesex Hospital, Physician to the City of London Hospital for Diseases of the Chest, 61, Welbeck-street, W. (C. 1876-78.)

1877 TIBBITS, HERBERT, F.R.C.P. Ed., 68, Wimpole-street, W.

1880 TIBARD, NESTOR ISIDORE (C.), M.B. Lond., 39, Curzon-street, Mayfair, W.

1856 TOMES, J., F.R.S., Consulting Dental Surgeon to the Middlesex Hospital, Upwood Gorse, Caterham, Surrey. (C. 1867-9.)

1864 TONGE, MORRIS, M.D., Harrow-on-the-hill, Middlesex.

1872 TOWNSEND, THOMAS SUTTON, 68, Queen's Gate, South Kensington.

1881 TREVES, FREDERICK, Assistant Surgeon to the London Hospital, 18, Gordon-square, W.C.

1851 TROTTER, JOHN W., Surgeon-Major, Coldstream Guards, Bossall Vicarage, York. (C. 1865-9.)

1859 TRUMAN, EDWIN THOMAS, Surgeon-Dentist in Ordinary to Her Majesty's Household, 23, Old Burlington-street, W.

1867 TUCKWELL, HENRY MATTHEWS, M.D., Physician to the Radcliffe Infirmary, 64, High-street, Oxford.

1858 TUDOR, JOHN, Dorchester, Dorset.

†1875 TURNER, FRANCIS CHARLEWOOD, M.D., Physician to the London Hospital, 15, Finsbury-square, E.C.

1863 TURNER, JAMES SMITH, Dental Surgeon to the Middlesex Hospital, 12, George-street, Hanover-square, W.

Digitized by Google

Elected

1858 TURTLE, FREDERICK, Clifton Lodge, Woodford, Essex.

1878 TYRRELL, WALTER.

1880 TYSON, WILLIAM JOSEPH, M.B., Medical Officer of the Folkestone Infirmary, 89, Sandgate-road, Folkstone,

1854 VASEY, CHARLES, 5, Cavendish-place, Cavendish-square, W.

1867 VENNING, EDGCOMBE, late Surgeon, 1st Life Guards, 87, Sloane-street.

1868 VINCENT, OSMAN, Surgeon to the National Orthopædic Hospital, 45, Seymour-street, Portman-square, W.

†1867 WAGSTAFFE, WILLIAM WARWICK, B.A., Assistant Surgeon to St. Thomas's Hospital, 2, Palace-road, Albert Embankment, S.E. (C. 1874, C. 1878-80. S. 1875-7.)

O.M. WAITE, CHARLES D., M.D., Senior Physician to the Westminster General Dispensary, 3, Old Burlington-street, W.

1881 WALLER, BRYAN CHARLES, M.D., 15, Lonsdale-terrace, Edinburgh.

1873 WALSHAM, WILLIAM J., M.B., C.M. (C.), Assistant Surgeon to and Demonstrator of Anatomy and Operative Surgery at St. Bartholomew's Hospital, Surgeon to the Metropolitan Free Hospital and to the Royal Hospital for Diseases of the Chest, 27, Weymouth-street, Portland-place. (C. 1881.)

1859 WALTERS, JOHN, M.B., Reigate, Surrey.

1847 WARD, T. OGIER, M.D., 12, Place de la Mare, Caen. (C. 1851-3.)

1858 WARDELL, JOHN RICHARD, M.D., Calverley-park, Tunbridge Wells.

1877 WARNER, FRANCIS, M.D., Assistant Physician to the London Hospital and to the East London Hospital for Children, 24, Harley-street.

1877 WATERHOUSE, CHARLES, M.B., M.C., Aigburth, Liverpool.

1879 WATERS, JOHN HENRY, M.D., 101, Jermyn-street, St. James's, S.W.

1878 WATNEY, HERBERT, M.D., Lecturer on Materia Medica at St. George's Hospital, 1, Wilton-crescent, S.W.

1855 WATSON, SIR THOMAS, Bart., M.D., F.R.S., 16, Henrietta-street, Cavendish-square, W. (*Pres.* 1857-8. V.-P. 1859-63.)

1865 WATSON, W. SPENCER, Surgeon to the Great Northern Hospital, Surgeon to the Royal South London Ophthalmic Hospital, 7, Henrietta-street, Cavendish-square, W. (C. 1875-6.)

1880 WATTEVILLE, ARMAND DE, M.A., M.B., Medical Electrician to St. Mary's Hospital; 9, Wimpole-street, Cavendish-square, W.

1860 WAY, JOHN, M.D., 4, Eaton-square, S.W. (C. 1873-4.)

†1858 WEBER, HERMANN, M.D., Physician to the German Hospital, 10, Grosvenor-street, Grosvenor-square, W. (C. 1867-70. V.-P. 1878-80.)

1876 WEIR, ARCHIBALD, M.D., St. Mungho's, Great Malvern.

1864 WELCH, THOMAS DAVIES, M.D., Wilton Lodge, Queen's-road, Weybridge, Surrey.

1853 WELLS, THOMAS SPENCER, Surgeon to the Samaritan Free Hospital for Women and Children, 3, Upper Grosvenor-street, W. (C. 1865-8. V.-P. 1876-7.)

†1851 WEST CHARLES, M.D., Nice, Alpes Maritimes, France. (C. 1856-7.)

Digitized by Google

Elected

1877 West, Samuel, M.B., Assistant Physician to the City of London Hospital for Diseases of the Chest, Victoria-park, Casualty Physician to St. Bartholomew's Hospital, 15, Wimpole-street, Cavendish-square, W.

1878 Wharton, Henry Thornton, M.A., 39, St. George's-road, Kilburn.

1867 Whipham, Thomas Tillyer, M.B. (C.), Physician to, and Lecturer on Clinical Medicine at, St. George's Hospital, 11, Grosvenor-street, Grosvenor-square, W. (C. 1880-1.)

1869 Whipple, John H. C., M.D., Assistant Surgeon, 1st Battalion Coldstream Guards, Hospital, Vincent-square, Westminster, S.W.

1877 White, Charles Haydon, 20, Shakespeare-street, Nottingham.

1881 White, John Bradshaw, M.D., Hackney Infirmary, Homerton.

1881 White, William Hale, M.D., Demonstrator of Anatomy at Guy's Hospital, S.E.

‡1868 Whitehead, Walter, 248, Oxford-road, Manchester.

1877 Whitmore, William Tickle, 7, Arlington-street, S.W.

1870 Wickstead, Francis William, Chester House, Weston-super-Mare.

1879 Wilcox, Henry, M.B., Hurst-villa, Lewisham High-road, S.E.

1867 Wilcox, Richard Wilson, Temple-square, Aylesbury, Bucks.

1869 Wilkin, John F., M.D., M.C., New Beckenham, Kent.

1871 Wilkinson, J. Sebastian, Surgeon to the Central London Ophthalmic Hospital, 83, Wimpole-street, W.

1855 Wilks, Samuel, M.D., F.R.S., President, Physician to, and Lecturer on Medicine at, Guy's Hospital, 72, Grosvenor-street, W. (C. 1857-60. V.-P. 1869-72. P. 1881.)

1879 Willcocks, Frederick, M.B., 52, Scarsdale-villas, Kensington.

1869 Williams, Albert, M.D., 60, Kirkdale, Sydenham, S.E.

O.M. Williams, C. J. B., M.D., F.R.S., Consulting Physician to the Hospital for Consumption and Diseases of the Chest, Brompton [47, Upper Brook-street, Grosvenor-square, W.]. (*Pres.* 1846-7. V.-P. 1848-52. C. 1853-5. V.-P. 1858-61.)

‡1858 Williams, Charles, Surgeon to the Norfolk and Norwich Hospital, 9, Prince of Wales-road, Norwich.

1866 Williams, Charles Theodore, M.D., Physician to the Hospital for Consumption and Diseases of the Chest, Brompton, 47, Upper Brook-street, Grosvenor-square, W. (C. 1875-8.)

1872 Williams, John, M.D., Assistant Obstetric Physician to University College Hospital, 28, Harley-street, Cavendish-square, W. (C. 1878-80.)

1864 Williams, W. Rhys, M.D., Commissioner in Lunacy, 19, Whitehall-place, S.W.

1876 Williamson, James Mann, M.D., Ventnor, Isle of Wight.

1863 Willis, Francis, M.D., Braceborough, Stamford.

1859 Wilson, Edward Thomas, M.B., Montpelier-terrace, Cheltenham.

1859 Wilson, Robert James, F.R.C.P. Ed., 7, Warrior-square, St. Leonard's-on-Sea.

1863 Wiltshire, Alfred, M.D., Joint Lecturer on Midwifery at St. Mary's Hospital, 57, Wimpole-street, Cavendish-square, W.

Digitized by Google

Elected

‡1861 WINDSOR, THOMAS, Consulting Surgeon to the Salford Royal Hospital; Manchester Medical Society, The Owen's College, Coupland-street, Manchester.

1874 WISEMAN, JOHN GREAVES, Dearden-street, Ossett, Yorkshire.

1865 WITHERBY, WILLIAM H., M.D., Pitt-place, Coombe, Croydon.

1850 WOOD, JOHN, F.R.S., Surgeon to, and Professor of Clinical Surgery at, King's College Hospital, 68, Wimpole-street, W. (C. 1857-9. V.-P. 1872-4.)

1854 WOOD, WILLIAM, M.D., Physician to St. Luke's Hospital, 99, Harley-street, W.

1876 WOOD, WILLIAM EDWARD RAMSDEN, M.A., M.B. Cantab., Bethlem Royal Hospital, St. George's-road, S.E.

1879 WOODWARD, G. P. M., M.D., Deputy Surgeon General, Clarendon House, Norwood-road, Tulse-hill.

1865 WORKMAN, CHARLES JOHN, M.D., Titherley, Teignmouth, Devon.

1863 WORLEY, WILLIAM CHARLES, 43, De Beauvoir-road, N.

1869 WYMAN, W. S., M.D., Westlands, Upper Richmond-road, Putney, S.W.

1869 YEO, J. BURNEY, M.D., Physician with Charge of Out-Patients to King's College Hospital, and Assistant Physician to the Brompton Hospital for Consumption, 44, Hertford-street, Mayfair, W.

1872 YOUNG, HENRY, M.B., Monte Video, South America.

Digitized by Google

Digitized by Google

ANNUAL REPORT OF COUNCIL,

1880-81.

In presenting their Annual Report the Council are glad to be able, as in former years, to congratulate the Society on the continuance of its prosperity, as evinced particularly by the increasing number of its members and the high average of attendance at its meetings.

The total number of members is now 626.

During the past year 41 new members have been elected, viz. 31 *resident* and 10 *non-resident*.

Eleven members have resigned.

The Society has lost eight members by death:—Geo. Chas. Coles, Jacob Lockhart Clarke, Alfred Leggatt, Wm. Gordon Wotton (King's Langley), Edward C. Seaton, Edward Amphlett, James Pearson Irvine, Alfred G. P. Wilks (Ryde).

Dr. Pearson Irvine was a member of the Council, and for several years had contributed largely to the 'Transactions.' The Council feel that, by his premature death, the Society has sustained a specially severe loss, and one which, of necessity, is not soon or easily replaced.

It was judged best to hold no special debate in the early part of the year; but in the present session the subject of rickets has given rise to a discussion which will, the Council think, prove of great value by bringing out prominently the views now prevailing regarding this disease. The Council feel that the best thanks of the Society are due to Dr. Hilton Fagge for having undertaken the introduction of the debate, and for the able manner in which he has introduced it. The thanks of the Society are due also to those gentlemen who, by taking part in the debate, have explained the results of their experience.

Digitized by Google

The system of exhibiting specimens by card, which was introduced nearly two years ago, but which had been in operation for only a short period at the date of the last Annual Report, has been proved by the past year's experience to work well, and has been, the Council believe, a means of largely increased usefulness to the Society, without interference with other specimens which, for various reasons, have seemed better adapted for exhibition with oral communication.

In accordance with a suggestion of the President, a list of desiderata was drawn up a few months since, and has been now distributed to the members of the Society—a proceeding which, the Council believe, will be a means of guiding those who have the opportunity of exhibiting specimens, with regard to what seems, at the present time, more particularly needed for the elucidation of moot points in pathology. At the same time "it is not intended in the least to restrict the spontaneous action of members, or to limit its scope. Miscellaneous specimens, not mentioned in the list, will, of course, be as acceptable as heretofore."

The income of the Society during the past financial year has amounted to £630 15s. 6d., of which the sum of £473 11s. was formed by members' subscriptions and admission fees, and £87 5s. 6d. by the sale of the Society's 'Transactions.'

The total expenditure during the year amounts to £504 16s. 8d., of which the sum of £293 18s. represents the cost of the current volume of the 'Transactions.'

The funded stock of the Society remains the same as at the date of the last Report, viz. £1067 15s. 1d. in Consols.

Digitized by Google

THE PATHOLOGICAL SOCIETY OF LONDON,

Cr. *In Account with the Treasurer,* Dr. GEORGE JOHNSON, F.R.S., *34th Session,* 1879–80. **Dr.**

	£	s.	d.	£	s.	d.
By *Balance* from last account 1st January, 1879	33	8	10			
Cheque outstanding (Noble Smith)	5	3	0			
				38	11	10
Subscriptions, &c.:						
395 Annual Subscriptions, 1879-80	414	15	0			
5 Ditto, Arrears	5	4	0			
31 Admission Fees	32	11	0			
10 Composition Fees (Non-Resident)	21	0	0			
				473	11	0
Sale of Transactions: May account	74	0	6			
ditto	2	17	0			
November ditto	10	8	0			
				87	5	6
Dividends on £1067 15*s.* 1*d.* Consols, January	15	13	7			
July	15	13	7			
				31	7	2
				£630	15	6

To *Meetings:*	£	s.	d.	£	s.	d.
Payment to Royal Medical and Chirurgical Society for Rent, Gas, &c.	63	0	0			
Refreshments, Waiters, Management	36	15	0			
Richard Coldrey, Meetings, &c.	7	10	0			
Microscopes and Lamps (Pillischer)	31	1	6			
				138	6	6
Transactions: Vol. XXXI (750 copies): Printing, Binding, and Delivery (Adlard)	181	12	2			
Lithography and Woodcuts (Noble Smith)	37	17	0			
Ditto (Burgess)	18	14	0			
Ditto (Huth)	14	0	0			
Ditto (Mintern)	8	2	0			
Ditto (West, Newman & Co.)	30	7	10			
Ditto (Cooper)	2	2	0			
Index (Wheatley)	3	3	0			
				293	18	0
Illustrations for Vol. XXX (Noble Smith)	5	3	0			
Ditto (Collins)	10	1	6			
				15	4	6
Stationery (Wodderspoon)	14	12	3			
Ditto (Odell and Ives)	1	5	0			
				15	17	3
Secretariat and Treasury:						
Assistance to Hon. Secs. (Mr. Wheatley)	7	7	0			
Posting Ledgers (Mr. McDermott)	2	2	0			
Collecting Subscriptions, &c.	16	7	6			
Petty Cash (Hon. Secretaries)	2	3	7			
Ditto (Mr. Wheatley)	9	1	4			
				37	1	5
Cabinet maker (Cribb & Son)	4	9	0			
				4	9	0
				504	16	8
Balance at Bankers				125	18	10
				£630	15	6

Audited and compared with the Vouchers and found correct.

Auditors { DAVID B. LEES, M.D.
A. PEARCE GOULD, M.S.

Digitized by Google

Digitized by Google

ADDRESS

BY THE PRESIDENT,

SAMUEL WILKS, M.D., F.R.S.,

DELIVERED ON TAKING THE CHAIR, FEBRUARY 19TH, 1881.

GENTLEMEN,—Allow me to thank you very much for the honour you have conferred upon me in electing me to the office of President of your Society. Advantages, no doubt, accrue from the operation of the rule which renders vacant this chair every two years, thus allowing members with different inclinations and sympathies to take their turn in giving a bias to, if not directing, the operations of the Society. The regulation is, no doubt, a good one; it brings fresh influences to bear upon us, and prevents us working in one groove. I am particularly unfortunate, therefore, in succeeding a President like Mr. Hutchinson, who has so many sides to his professional character that it were difficult to declare which branch of pathology he has favoured more than another, all of them being of equal familiarity to him. If it had been considered expedient to have a permanent President, I know no man in the profession who could have more worthily filled the office, as to satisfy the wants of every member, than Mr. Hutchinson. It may be as well, however, that we have this continued change, and, perhaps, even advisable that Presidents do show a bias towards one particular mode of pathological procedure rather than another, so that each in its turn may then receive a due share of cultivation. The widest difference of opinion, in respect to the object of our Society, appears to me to have been exhibited in the tendency, on the one hand, to limit our work to morbid anatomy, or to the increase of knowledge by the addition of fresh-ascertained anatomical facts, and, on the other hand, by the attempt to extend our boundaries by the discussion of some large and general questions in pathology. I may as well at once express my opinion that

Digitized by Google

it is in the former direction that I consider the best work is to be done.

I have always considered that the glory of this Society has lain in its cultivation of morbid anatomy. If this were not so, wherefore the need of its existence? Before its foundation other Societies were in full force, one of their functions being the discussion of questions of pathology, and to them the right still remains; but the opportunity was needed by which those engaged in the new science of pathology could organise their work and bring together facts, so as to place on a surer foundation the more substantial and material data on which so many morbid processes depend.

The Society set to work in a thoroughly scientific spirit, and its labours and successes have been great. Morbid anatomy, it must be remembered, is a comparatively new science; it has almost grown up in our own day. When I first entered my own hospital a uniform examination of the dead was not the rule, the *post-mortem* examination being made at the discretion of the physician or surgeon to satisfy some question in diagnosis. It is true that Valsalva and Morgagni had collected together some splendid material in Italy, and that, in France, Andral and Cruveilhier had long been at work on pathological anatomy, and that Rokitansky was arranging the fruits of his vast labours in Vienna; but the experience of these men had not become common knowledge, transfused through the profession, so that pathological anatomy may be correctly stated to be a science of our own day, and our 'Transactions' bear testimony to this truth, constituting as they do a kind of epitome of its history; or representing, indeed, a microcosm of this branch of medicine. The earlier volumes indicate how we were, at the time of their issue, comparatively in the childhood of knowledge; how ignorant we were at the birth of this Society of facts which every one is now familiar with, and how year by year we have grown in stature, until we have reached our present eminence.

In the early history of medicine it was regarded almost in the light of a great discovery that life was incompatible with destruction of the brain, lungs, or heart, and that these three organs constituted, therefore, the tripod of life. This very trite and obvious truth, put in this beautiful epigrammatic way, has even been transplanted into some modern works; but the knowledge contained in it is much on a par with that which I have of a watch; this amounts to my acquaintance with the fact that if a spring or a chain be broken the ma-

Digitized by Google

chinery comes to a standstill. It requires further insight to ascertain that the derangement and cessation of these more striking portions of the mechanism may be merely the manifestations, to the uneducated eye, of those general and subtle changes in the more recondite parts within. In the same way how often is heart disease but the mere outward expression of a universal degeneration of the tissues or death through the brain, due to causes altogether independent and remote. So, in the early history of our Society, specimens of disease of the heart came before us in which the derangements due to mechanical alterations were only too obvious; then the more common diseases of other organs were presented to us, and so we continued until descriptions of more minute changes, found in these and more complex tissues, became the practice, and thus, by an enormous advance in morbid histology, our present position was reached. The development of pathological science may be found in our volumes, and an account of some of the best discoveries of the day in their pages.

Special individual facts, about which the crudest information existed, have grown into well-marked pathological processes, and the knowledge of some now well-recognised form of disease has had its origin and grown to maturity in these rooms. My mind naturally reverts to some subjects in which I have had a personal interest; for example, lymphadenoma. An early volume of our 'Transactions' gives a description of a case of enlarged glands in the neck and mediastinum, a later volume gives another case, and so on, until the whole subject relating to this remarkable malady may be found discussed and elaborated in the works of this Society. Then take Addison's disease. The discoverer had described, in a most accurate manner, the clinical features of the disease now known by his name, so accurately, indeed, that I am not aware that any fact of importance has subsequently been added; but he failed to define the exact pathological changes which take place in the organ affected: the true anatomical basis of the disease was made out, or, perhaps, fought out, at this Society. Or if we take syphilis, we have a most clear and convincing proof that the glory of this Society has lain in its cultivation of morbid anatomy. I have no hesitation in saying, or at least in giving it as my opinion, that the knowledge obtained of the nature of this disease since the birth of the Society, and contained in its 'Transactions,' is of more worth than any which can be found in whole libraries of syphilography made before this

Digitized by Google

epoch. Why is this? The answer is the best proof of the necessity of a Society like ours. In prepathological times it had been said that syphilis was a disease which affected the skin, the bones, and the external parts of the body, but that the interior escaped, and for no other reason (if reason it can be called) than that no surgeon had cared to look inside after death. When this was done it was found that chancres and buboes, nodes and ulcers, could affect internal parts as well as external. Thus, the whole history of visceral and internal syphilis is written in our 'Transactions.'

The subject of syphilis suggests a thought as to the practical value of our studies, and contains an answer to the question sometimes propounded—Why so great devotion to pathology? Does it help us to cure the sick? Can it assist us in alleviating the sufferings of our fellow-creatures, which is the great object of our calling? Or, does not pathology keep far in advance of therapeutics? For my part I have not the slightest feeling of sympathy with these questions, for I believe that discoveries in pathology and therapeutics always go hand in hand. Of course, I know there is a doctrine which maintains that therapeutics has a basis of its own, and physiology and pathology may be altogether ignored. I need not remind you, gentlemen, who are engaged in scientific work, that such considerations as ulterior and practical results are not worthy of you. A scientific man is a worker for truth, and, in my experience, if he sees any other object before him than the immediate result of his investigations, or if he be working by any other light than the "*siccum lumen*," of which Bacon speaks, he will miss his mark. The discovery of a new fact must bring with it good, although the scientific man works for truth alone, and feels that knowledge is its own reward. But sometimes you have an answer as to what practical result follows a furtherance of pathology, and you may instance syphilis, and declare that the knowledge of internal visceral disease arising from this affection has saved the lives of thousands of human beings.

It would, indeed, be easy to show the enormous accumulation of knowledge which has arisen from a simple inspection of the dead, and we are proud to think that much of this is contained in our 'Transactions.' It is herein that our strength lies, and I should recommend that we continue in the old and excellent way. There is an immense harvest yet to reap, as the list of desiderata, drawn up under the auspices of your late President, will show. This marks

Digitized by Google

our position in pathological knowledge, we are within a tolerably defined circle and our ambition is to enlarge it.

There is a simple mode by which much knowledge might be obtained, but is one which we have not much used. I allude to a kind of numerical method in reference to the occurrence of morbid growths and deposits in the various tissues of the body. A mere enumeration of a large number of cases, stating the position of primary and secondary growths, would assist us much in a knowledge of their nature and origin. At the present time an opinion exists amongst the less educated in the profession that such a list as that found in the nomenclature of the College of Physicians, or as may be found in most works on pathology or medicine, is a strictly pathological one. They are of opinion that there are certain distinct forms of disease known as tubercle, cancer, &c., and that these may affect all or any of the tissues of the body. The different organs are placed in order, and then the different diseases attached to them, as inflammation, suppuration, tubercle, cancer, &c. Now, those who have made a study of morbid anatomy know how erroneous is such an opinion, and that many of these organs are never or rarely attacked primarily by some of these diseases, which, when found therein, are always of secondary formation. Now, if several hundred cases of cancer could be reported, and it were found that in none of them were certain tissues affected, the fact would go far to show that these were incapable of being assailed, and the same might appear if certain parts were never affected but by secondary growths. Suppose, for instance, in this summary it were seen that the lungs in a certain number of cases were affected by cancer, and it could be shown (as in a majority of instances it no doubt could) that the cancerous deposits were secondary to growths elsewhere, it would follow that the seeds had been brought there from some other part. Suppose, moreover, that there were a few cases left in which this result of infection was not so evident, such exceptional cases might raise a reasonable doubt as to some error in the observation.

Not only could the method be adopted with new growths, but with other morbid conditions which pervade several parts, as, for example, suppuration. Suppose it were found that suppuration of the lung was always secondary, and the same of the kidney and some other organs, a great and important fact would be arrived at. In this way, by the process of exclusion, it might be discovered

Digitized by Google

that the only primary morbid changes in the alveoli of the lung were the production of well-formed cells or leucocytes and their modification known as tubercle. Herein might lie the beginning and ending of all the changes which the lung proper can undergo, and that all the diseases found therein had their seeds brought from elsewhere.

The same method could be applied to other organs, so that we should learn the limit of morbid changes in each one. A simple inspection of the dead, together with a careful history of every case of morbid growth or deposit, would lead us to most important knowledge as to their origin. It would lead to the same point, but from a different direction, as that which is aimed at by those who are studying the origin of cancer and new growths from a histological point of view; you may still continue in the path which Dr. Creighton is pursuing, and endeavour to discover by the microscope the relation between morbid growths and the natural tissue elements; but this will not interfere, but rather supplement, the other, or rough-and-ready method, which I have mentioned.

In conclusion, let me say that our Society stands out prominently in the history of medicine as having taken a large share in the cultivation of one of its most important branches. It has made constant progress, and has never slackened in its work, and if you now, [gentlemen, maintain it in the same path during my two years of office I shall be more than content.

Digitized by Google

LIST OF SPECIMENS AND REPORTS

BROUGHT BEFORE THE SOCIETY DURING THE SESSION 1880-81.

I.—DISEASES, ETC., OF THE NERVOUS SYSTEM.

PAGE

1. A remarkable case of chronic hydrocephalus
By W. A. Brailey, M.D. 1
2. External hydrocephalus By Walter Edmunds, M.D. 4
3. Tumour (and microscopic section) of optic tract from a case of diabetes insipidus
By Norman Moore, M.D. 5
4. Pyocephalus. Brain of a child aged five months
By Norman Moore, M.D. 6
5. Spinal cord showing dilatation of the central canal
By Norman Moore, M.D. 7
6. Tumour (glioma) of the spinal cord and medulla oblongata; dilatation of the lymphatics; large cavity occupying the position of the central canal (syringomyelus) [With Plates I and II]
By Thomas Whipham, M.B. 8
7. Paralysis of third, fifth, and sixth nerves of four years' duration, in a girl, aged fourteen, the subject of inherited syphilis (Living specimen)
By E. Nettleship 13
8. Enlargement of median nerve; congenital syphilis
By J. A. Ormerod, M.B. 14
9. Gummatous disease of brain, crainal bones and vertebræ (Card specimen)
Exhibited by Jonathan Hutchinson for Furneaux Jordan 15

Digitized by Google

II.—DISEASES, ETC., OF ORGANS OF RESPIRATION.

PAGE

1. Case of a nutshell impacted in the larynx; tracheotomy; membranous tracheitis, and purulent bronchitis; collapse of lungs By R. E. Carrington, M.D. 16
2. Chronic excavation of the lung, terminating in localised pneumothorax, with extensive opening into the lung By Samuel West, M.B. 21
3. A case of gangrene of the lung from thrombosis in pulmonary artery By B. G. Morison, M.B., C.M. 23
4. A case of excision of the anterior third of the tongue for epithelioma of its tip and sides, followed by gangrene of the lung By H. Royes Bell. 26
5. Two cases in which epithelioma recurred in the lung By Rickman J. Godlee 27
6. Cancer of the right lung with embolism in middle cerebral artery By Norman Moore, M.D. 32
7. Ulcer of bronchus (right) penetrating the pulmonary artery (Card specimen) Exhibited by Norman Moore, M.D. 33
8. Congenital cyst in larynx (Card specimen) Exhibited by John Abercrombie, M.D. 33

III.—DISEASES, ETC., OF THE ORGANS OF CIRCULATION.

1. Malformation of heart; great constriction or stenosis of the orifice of the pulmonary artery; aorta arising from both ventricles; defects in the fold of the foramen ovale; ductus arteriosus closed [With Plate III] By Thomas B. Peacock, M.D. 35
2. Atresia of the aortic aperture in an infant By Samuel G. Shattock 38
3. Malformation of the heart By Norman Moore, M.D. 39
4. Malformation of the heart By Nestor Tirard, M.B. 41

Digitized by Google

PAGE

5. Two cases of extreme stenosis of the tricuspid orifice
By Bedford Fenwick, M.D. 42

6. Heart with calcareous plates
By R. W. Burnett, M.D. 53

7. Rupture of the arch of the aorta from injury
By Jeremiah McCarthy 54

8. Syphilitic disease of the cerebral arteries [With Plates IV and V] By W. Anderson 55

9. Obstruction of the mesenteric artery and vein, followed by intestinal and peritoneal hæmorrhage, with rapidly fatal termination By Frederick Taylor, M.D. 61

10. Aneurysm of the anterior communicating artery of the circle of Willis By W. M. Ord, M.D. 65

11. Aneurysm of the left posterior communicating artery
By Samuel West, M.B. 66

12. Aneurysm of the pulmonary artery
By Samuel West, M.B. 67

13. Aneurysm of middle cerebral artery in a boy of twelve, rupturing into the descending cornu of the lateral ventricle By Samuel West, M.B. 69

14. Thrombosis of innominate vein contiguous with a pulmonary cavity By W. Wilberforce Smith, M.D. 70

15. Blood from a patient who died of diabetes
By Norman Moore, M.D. 72

16. Congenital imperfection of septum ventricorum, with ante-mortem thrombosis of right ventricle and pulmonary artery (Card specimen)
Exhibited by John Abercrombie, M.D. 73

17. Stenosis of tricuspid and mitral valves, with contraction of the aortic semilunar valves, in a boy fourteen years of age (Card specimen)
Exhibited by A. Boyce Barrow 74

18. A case of mitral and tricuspid stenosis, with concurrent disease of the aortic valves (Card specimen)
Exhibited by Robert E. Carrington, M.D. 75

19. Tricuspid and mitral stenosis (Card specimen)
Exhibited by P. Horrocks, M.D. 76

Digitized by Google

PAGE

20. Mucous tumour of heart (syphilitic gumma?) (Card specimen) Exhibited by S. G. SHATTOCK. 77
21. Aneurysmal dilatation and rupture of aortic valve (Card specimen)
Exhibited by SAMUEL WEST, M.B. (for LAWRENCE HUMPHRY, M.B.) 77
22. Calcareous degeneration of the aorta
Exhibited by R. W. BURNET, M.D. 78

IV. DISEASES, ETC., OF THE ORGANS OF DIGESTION.

1. Perforating ulcer of the stomach leading to fatal hæmatemesis thirty hours after birth
By JAMES F. GOODHART, M.D. 79
2. A case of reduction "en masse" of a strangulated inguinal hernia from separation of the neck of the sac [With Plate VI, fig. 1] By JEREMIAH MCCARTHY 80
3. Two cases of intestinal obstruction
By F. CHARLEWOOD TURNER, M.D. 82
4. Adenoid disease of the rectum (cancer) [With Plates VII to XVI] By W. HARRISON CRIPPS 87
5. Cystic disease of the liver, and of both kidneys [With Plate XVII] By P. A. PYE-SMITH, M.D. 112
6. Chronic dysentery and abscess of the liver, opened first by aspiration and then by direct incision, with antiseptic precautions. Death on the sixth day
By SIR JOSEPH FAYRER, M.D. 119
7. Abscess of the liver consequent upon dysentery contracted in England By W. HOWSHIP DICKINSON, M.D. 127
8. Abscess of liver in a child By NORMAN MOORE, M.D. 132
9. Cirrhosis of liver in a child By NORMAN MOORE, M.D. 132
10. Cirrhosis of liver in a child with congenital hydrocele
By SAMUEL OSBORN 133
11. Cicatrices in the liver, the result of suppurative pylephlebitis By JAMES F. GOODHART, M.D. 137

Digitized by Google

V. DISEASES, ETC., OF THE GENITO-URINARY ORGANS.

PAGE

1. Epithelioma of bladder, following removal of a calculus By N. Davies Colley 139
2. Case of villous polyp of the bladder By Frederick Treves 141
3. Case of sarcoma of the right kidney confined to the capsule By William H. Day, M.D. 142
4. Calcified fibroid of uterus By Norman Moore, M.D. 145
5. Large multilocular fibrocystic tumour of uterus By W. A. Meredith, M.B., C.M. 145
6. Proliferating cysts in the ovary of a seven months' fœtus [With Plate VI, fig. 2] By Alban Doran 147
7. Fibro-cyst of uterus (Card specimen) Exhibited by W. A. Meredith, M.B. 151

VI. DISEASES, ETC., OF THE OSSEOUS SYSTEM.

1. A case of congenital absence of fibula and two toes, and talipes equino-valgus. Living specimen By A. Pearce Gould, M.S. 152
2. Fracture of the coracoid process, followed by fibrous repair By Samuel G. Shattock 155
3. Comminuted fracture of the astragalus with subastragaloid dislocation of the foot outwards and backwards [With Plate XVIII] By Henry Morris 156
4. Fracture of the inner malleolus with partial dislocation of the foot by rotation around its antero-posteror axis By Henry Morris 158
5. Genu valgum [With Plate XIX] By Henry Morris 160
6. Acute necrosis of the tibia By W. Morrant Baker, for Dr. Gregory White 163
7. Ostitis of the femur By W. Morrant Baker 165
8. Ostitis deformans By Frederick Treves 167

Digitized by Google

PAGE

9. Sarcoma of the lower extremity of the femur extending into the knee-joint, and simulating destructive disease of the joint By Frederic S. Eve 169

10. Symmetrical exostoses of the inferior maxilla By Frederic S. Eve 170

11. Case of long retention of the ivory pegs in Dieffenbach's operation for pseudarthrosis [With Plate XX] By W. Anderson 170

12. Tubercular disease of synovial membranes and tubercular disease of joints [With Plates XXI, XXII, and XXIII] By John Croft 174

13. Case of tubercular disease of the elbow-joint By G. H. Makins 189

14. Congenital malformations of hand and feet (Card specimen) Exhibited by Sidney Coupland, M.D., for Mortimer Balding, M.D. 190

15. Disease of right shoulder and right hip-joints in an infant (Card specimen) Exhibited by John Abercrombie, M.D. 192

16. Sequestrum of clavicle (Card specimen) Exhibited by Jonathan Hutchinson for Macnaughton Jones, M.D. (of Cork) 192

17. Old outward dislocation of the patella (Card specimen) Exhibited by Charters J. Symonds 193

18. Parts of joints showing the changes characteristic of gout and rheumatic arthritis from the same patient (Card specimen) Exhibited by Jonathan Hutchinson 193

Digitized by Google

VII. MORBID GROWTHS.

PAGE

1. Dissection of a congenital hydrocele of the neck. [With Plate XXIV] By Frederick Treves 194
2. Congenital sacral tumour [With Plates XXV and XXVI] By Samuel G. Shattock 197
3. Congenital tumour containing fœtal structures, removed from the sacrum of a child. Exhibited by C. Macnamara 199
4. Dermoid tumour, probably growing from soft palate or base of skull [With Plate XXVII] By W. Hale White, M.D. 201
5. Congenital mucous polypus of umbilicus By A. Pearce Gould 204
6. Extra-renal growth [With Plate XXVIII] By John Abercrombie, M.D. 205
7. Fibro-cellular tumour removed from the interior of the knee-joint. By Rickman J. Godlee 207
8. Myeloid tumour of the head of the tibia By Jeremiah McCarthy 208
9. Round-celled sarcoma with hyaline degeneration (cylindroma) of the popliteal space [With Plate XXIX] By Henry T. Butlin 210
10. Squamous epithelioma of the upper jaw [With Plate XXIX] By Henry J. Butlin 212
11. Case of colloid cancer of peritoneum invading the spleen By W. M. Ord, M.D. 214
12. Cystic degeneration of breast [With Plate V, figs. 3 and 4] By C. Mansell Moullin, M.D. 215

Report. By Henry T. Butlin and James F. Goodhart, for *Committee on Morbid Growths* 217

13. On the connection between disease of the nipple and areola and tumours of the breast [With Plate XXX] By George Thin, M.D. 218
14. Cancer of the right pleura, following cancer of the right mamma successfully removed two years before By Samuel West, M.B. 227

Digitized by Google

PAGE

15. An epithelial ulcer in the leg with unusual history
By JONATHAN HUTCHINSON. 230

Report. By MARCUS BECK and RICKMAN J. GODLEE, for *Committee on Morbid Growths* 231

16. A specimen of mammary adeno-fibroma, containing an adjacent piece of carcinoma By RUSHTON PARKER 233

Report. By MARCUS BECK and RICKMAN J. GODLEE, for *Committee on Morbid Growths* 235

17. Hyaline adeno-myxoma of breast
By RUSHTON PARKER 236

18. Acinous adenoma of right breast (Card specimen)
Exhibited by RUSHTON PARKER 237

19. Tubular adenoma of left breast (Card specimen)
Exhibited by RUSHTON PARKER 238

20. Acinous adenoma of tip of nose (Card specimen)
Exhibited by RUSHTON PARKER 238

21. Tubular adenoma of root and dorsum of tongue—submucous (Card specimen)
Exhibited by RUSHTON PARKER 238

22. Columnar epithelioma of antrum of upper jaw (Card specimen) Exhibited by RUSHTON PARKER 239

23. Round-celled acinous epithelioma, or adenoma of upper jaw (Card Specimen)
Exhibited by RUSHTON PARKER 239

24. Odontoma of second lower left molar tooth (Card specimen) Exhibited by RUSHTON PARKER 240

25. Congenital fibro-cystic (nævoid ?) tumour of the cheek (Card specimen)
Exhibited by JONATHAN HUTCHINSON 240

26. Congenital tumour at the extremity of the finger of an infant (Card specimen)
Exhibited by JONATHAN HUTCHINSON 241

27. Congenital tumour on end of toe of an infant. (Card specimen) Exhibited by JONATHAN HUTCHINSON 241

28. Cartilage tumours in the bones of fingers and metacarpus (Card specimen)
Exhibited by JONATHAN HUTHINSON 241

Digitized by Google

PAGE

29. Sarcoma of clavicle (Card specimen)
Exhibited by JONATHAN HUTCHINSON, for H. MACNAUGHTON JONES, M.D. (of Cork) 242

30. Osteo-sarcoma of lower end of femur. (Card specimen)
Exhibited by JONATHAN HUTCHINSON, for H. MACNAUGHTON JONES, M.D. (of Cork) 242

31. Cancer of the mamma, following eczema of the nipple (Card specimen)
Exhibited by JONATHAN HUTCHINSON, for H. MACNAUGHTON JONES, M.D. (of Cork) 242

32. Fatty tumour from beneath scalp (Card specimen)
Exhibited by SYDNEY JONES 243

33. Fatty tumour removed from right arytæno-epiglottidean fold (Card specimen) Exhibited by SYDNEY JONES 243

34. Sarcoma of testis (recent) (Card specimen)
Exhibited by JOHN H. MORGAN 243

35. Epithelioma arising in an ulcer of the leg (Card specimen)
Exhibited by CHARTERS J. SYMONDS 244

36. An epulis containing masses of hyaline cartilage (fibro-enchondroma) (Card specimen)
Exhibited by H. A. LEDIARD, M.D. (of Carlisle) 244

VIII.—DISEASES OF THE SKIN.

1. Observations on the nature and affinities of molluscum contagiosum
By ALEX. MORISON, M.D., and BASIL G. MORISON, M.D. 245

2. The histology and pathology of molluscum contagiosum.
By H. RADCLIFFE CROCKER, M.D. 254

3. On the histology of the molluscum contagiosum of Bateman
By GEORGE THIN, M.D. 257

4. A case of abnormal pigmentation of the skin following jaundice. By JOHN CAVAFY, M.D. 258

Report. By JONATHAN HUTCHINSON, P. H. PYE-SMITH, and W. MORRANT BAKER for
Committee on Dr. Cavafy's case of abnormal pigmentation of the skin 260

Digitized by Google

PAGE

5. Circumscribed scleroderma affecting the face and scalp [With Plate XXXI] By W. Morrant Baker. 261
Report. By Jonathan Hutchinson, P. H. Pye-Smith, and John Cavafy, for
Committee appointed to examine Mr. Morrant Baker's case of scleroderma of the face and scalp 262
6. Case of scleroderma. By John Abercrombie, M.D. 266
7. A case of leucoderma. By James Startin 268
8. Case of congenital ichthyosis. By James Startin 268
9. A case of extensive lupus (living specimen) By Malcolm Morris 270
10. "Cheiro-pompholyx" (Card specimen) Exhibited by Jonathan Hutchinson for H. Mac-Naughton Jones M.D. (of Cork) 272

IX.—MISCELLANEOUS SPECIMENS.

1. A case of acute myositis of thigh By J. F. Payne, M.D., Hon. Sec., for C. J. Devis, Hereford 273
2. On a case of arrested development and growth of the right upper limb in man By Samuel G. Shattock 276
3. Two cases of truncated arms bearing at the ends fœtal hands voluntarily mobile By Richard Barwell 280
4. Case of unilateral hypertrophy of the head and face, involving bones and soft parts By Richard Barwell 282
5. Dissection of cleft palate, from the adult Exhibited by Samuel G. Shattock 284
6. Lymph scrotum, showing filaria *in situ* By P. Manson, M.D., of Amoy (Communicated by G. Thin, M.D.) 285
7. Ainhum By Jonathan Hutchinson for A. Crombie, M.D., of Dacca, India 302
8. Spontaneous disintegration of vesical calculi By William Ord, M.D. 304

Digitized by Google

PAGE

9. Case of hemiatrophia facialis (Living specimen) [With Plate XXXII] By J. F. PAYNE, M.D. 306
10. Vesical calculi (Card specimen) Exhibited for SURGEON-MAJOR CURRAN by F. TAYLOR, M.D. 310

X.—SPECIMENS FROM THE LOWER ANIMALS.

1. Vesical calculus from a dog By FREDERICK TREVES 311
2. The kidneys of a boar pig, showing dilatation and atrophy consequent on disease of the vesiculæ seminales Exhibited by JONATHAN HUTCHINSON 312

XI.—DISCUSSION ON THE PATHOLOGY OF RICKETS.

On November 16th, December 7th and 16th, 1880 Opened by C. HILTON FAGGE, M.D. 313

Digitized by Google

Digitized by Google

REPORTS OF THE COMMITTEE ON MORBID GROWTHS.

---

1. On C. M. Moullin's specimen of Cystic Degeneration of the Breast (H. T. Butlin and J. F. Goodhart) 217

2. On Jonathan Hutchinson's case of Tumour [Epithelial Ulcer] of the Leg (M. Beck and R. J. Godlee) . 231

3. On R. Parker's case of Adeno-fibroma and Carcinoma of the same Breast (M. Beck and R. J. Godlee) . 235

Digitized by Google

LIST OF PLATES.

	PAGE
I. Tumour of the Spinal Cord. (Dr. WHIPHAM.) (Page 8)	9
II. Ditto.	9
III. Malformation of Heart. (Dr. PEACOCK.) (Page 35)	35
IV. Syphilitic Disease of the Cerebral Arteries. (Mr. ANDERSON.) (Page 55) . . .	55
V. Figs. 1 and 2. Ditto. . . . Figs. 3 and 4. Cystic Degeneration of the breast. (Dr. MANSELL MOULLIN.) (Page 215)	55
VI. Fig. 1. Strangulated Inguinal Hernia. (Mr. MACCARTHY.) (Page 80) . . . Fig. 2. Cysts in the Ovary. (Mr. ALBAN DORAN.) (Page 147)	81
VII to XVI. Adenoid Disease of the Rectum. (Mr. W. H. CRIPPS.) (Page 87) . .	89
XVII. Cystic Disease of Liver and Kidneys. (Dr. PYE-SMITH.) (Page 112) . . .	113
XVIII. Fracture of the Astragalus. (Mr. H. MORRIS.) (Page 156)	157
XIX. Genu Valgum. (Mr. H. MORRIS.) (Page 160) .	161
XX. Long Retention of Ivory Pegs in Dieffenbach's Operation. (Mr. ANDERSON.) (Page 170)	171
XXI. to XXIII. Tubercular Disease of Joints. (Mr. CROFT.) (Page 174) . . .	175
XXIV. Congenital Hydrocele of the Neck. (Mr. TREVES.) (Page 194)	195
XXV. Congenital Sacral Tumour. (Mr. SHATTOCK.) (Page 197)	199
XXVI. Microscopical Structure of Tumour represented in Plate XXV	199

Digitized by Google

PAGE

XXVII. Dermoid Tumour of Soft Palate. (Dr. HALE WHITE.) (Page 201) . . . 201

XXVIII. Extra-renal Growth. (Dr. ABERCROMBIE). (Page 205). 207

XXIX. Figs. 1 to 3. Squamous Epithelioma of Upper Jaw. (Mr. BUTLIN.) (Page 212) . Figs. 4 to 7. Round-celled Sarcoma (or Cylindroma). (Mr. BUTLIN.) (Page 210) } 213

XXX. Disease of the Nipple in Relation to Mammary Tumours. (Dr. THIN.) (Page 218) . 219

XXXI. Circumscribed Scleroderma of the Face. (Mr. MORRANT BAKER.) (Page 261) . . 263

XXXII. Case of Hemiatrophia facialis. (Dr. PAYNE.) (Page 306) 307

XXXIII. Case of so-called Fœtal Rickets. (Dr. BARLOW.) (Page 364) 365

XXXIV. Case of Fœtal Rickets. (Mr. SHATTOCK.) (Page 369) 371

Digitized by Google

WOODCUTS.

PAGE

1. Case of adult hydrocephalus (Dr. Brailey) . . 2
2. Congenital absence of fibula (Mr. Pearce Gould) . 153
3. and 4. Congenital malformations of hand and foot (Dr. Coupland) 190
5. and 6. Congenital ichthyosis of hands and feet (Mr. Startin) 269
7. Unilateral hypertrophy of head (Mr. Barwell . . 282
8. Case of late rickets (Dr. Drewitt) . . . 388

Digitized by Google

REPORT.

SESSION 1880-81.

I. DISEASES, ETC., OF THE NERVOUS SYSTEM.

1. *A remarkable case of chronic hydrocephalus.*

By W. A. Brailey, M.D.

The patient was a female who died at the age of 53 years from acute pneumonia. She had been hydrocephalic since infancy. Her life was passed chiefly in public institutions, and for the last nine years she had been in a lunatic asylum. She had vomiting daily for several years, but this was much less frequent during the last few years of her life. Three years before death she had an epileptiform seizure, being convulsed and unconscious during several hours. Since that date she has had three or four less severe attacks of a similar character.

The bones of the extremities, as well as of the thorax, were small and imperfectly developed. The legs were quite unequal to support the body. She had no voluntary power of flexing them, but towards the close of her life the right gradually became contracted and flexed on the thigh. Her fingers presented the condition popularly known as "double-jointed." She had a lateral curvature of her spine.

As regards her mental capacity, she could converse and sing hymns, &c., and had a very fair amount of memory. She could sew and use her hands a little. She had a violent temper, and often got into a rage about trifles.

The horizontal circumference of the cranium measures 27 inches. The cranial bones are completely ossified. There are many Wormian bones. Except for the cyst noted below, the brain

Digitized by Google

nearly filled the cranial cavity, though it has since become shrunken in the process of hardening. The third and lateral ventricles are largely dilated. The commissures crossing the third ventricle are greatly elongated. The aqueduct of Sylvius is *not* occluded. Its anterior part is funnel-shaped, gradually tapering from its anterior end to its posterior portion, which is normal in size.

On the posterior part of the right side of the cranial floor, beneath the cerebellum, was found a closed sac, containing about two ounces of fluid. Its walls are made of a thin layer of fibrous tissue containing many connective-tissue corpuscles. It extends about one

WOODCUT 1.

inch across the middle line behind the foramen magnum, making a very distinct depression in the cranial floor, the bones being much thinned at that point. It is attached to the dura mater, but is apparently developed independently of it.

The opinion of the Society is requested as to the nature and origin of this cyst.

The principal points of interest in the case appear to be—

(1) The unusual longevity of the patient.
(2) The size of the cranium.
(3) Its complete ossification.
(4) The patency of the aqueduct of Sylvius.
(5) The presence of the cyst under the cerebellum.
(6) The amount of intelligence exhibited by the patient.

Digitized by Google

Remarks by Prof. Humphry on specimen of hydrocephalus in adult, with cyst beneath tentorium, exhibited by Dr. Brailey.

In cases of hydrocephalus the distended lateral ventricles expand the cranial cavity in all directions, except at the base, which, together with the face, preserves the usual size, or nearly so. The corpus callosum is carried upwards, and the septum lucidum is stretched. The falciform process of the dura mater is lengthened, enlarged, and carried upwards, so that the lower border forms a larger and higher arc than usual, and it is carried backwards as well as upwards. This causes a dragging upwards of the middle part of the tentorium, which may be only in front, and may be to such an extent that in a vertical section in the median plane it is seen ascending vertically from the Torcular Herophili to the point of entrance of the venæ Galeni, that is to say, the fourth sinus is vertical instead of horizontal. This is the case in a specimen from a child, lately placed in the Pathological Collection of the University of Cambridge. The middle part of the cerebellum is also raised above its proper level, and the hinder cerebral lobes enclosing the dilated hinder horns of the lateral ventricles extend behind the cerebellum and the tentorium, between the latter and the occipital bone. The third ventricle is dilated, and the aqueduct of Sylvius passes upwards, with a slight inclination forwards to it, from the fourth ventricle, which is of natural shape and size. The cerebellum being only of the ordinary dimensions, and being in the middle raised with the tentorium, a space or vacancy is left beneath and behind it, beneath the lateral sinuses. This space in the specimen referred to is occupied by loose connective tissue formed in an interval between the dura mater and the cranial layer of the arachnoid, which is thereby separated from the dura mater.

In the specimen before us similar changes appear to have taken place. The dragging of the falx upwards and backwards has drawn the tentorium upwards and increased the space in the cerebellar fossa, causing there a surplusage of space, which has been occupied, not in this instance by connective tissue formed on the arachnoid aspect of the dura mater, but by a cyst or cavity, which is not improbably a lymph-space, developed in and taking the place of such connective tissue. This, at least, seems to me the most probable explanation of the remarkable cavity seen beneath the tentorium. I at first thought it to be a dilatation and extension of

Digitized by Google

the fourth ventricle beneath the cerebellum, but it proved not to be so; and it is not of the nature of a meningocele, which it has been suggested that it may be. *April 5th*, 1881.

(The specimen has been presented to the Anatomical Museum of the Cambridge University, and has been dissected and prepared by Dr. BUSHELL ANNINGSON.)

---

2. *External hydrocephalus.*

By WALTER EDMUNDS, M.D.

EDWARD C—, aged 2½, was admitted into St. Thomas's Hospital February 9th, 1881, under the care of Dr. Stone.

The child was an idiot. He had never sat up, walked, or spoken. He very seldom cried, and did not swallow well.

He was blind. Mr. Nettleship was asked to examine his eyes. He found there was no perception of light, no marked ophthalmoscopic changes, but some doubtful pallor of the optic discs, the right being a little paler than the left. The pupils acted well to light.

One day while in hospital the child had, without any apparent cause, a convulsion, and the next day he died.

Post-mortem examination.—Body badly formed, but not ill-nourished; rickety; enlargement of the epiphyses, with beading of the ribs.

Forehead retreating, head somewhat conical and large, but not obviously hydrocephalic. Anterior fontanelle not closed by bone.

On removing the skull-cap, which was thickened, a large quantity of fluid (at least eight ounces) escaped from between the dura mater and the brain; the pia mater was œdematous; the brain exceedingly firm.

The hemispheres were very small and ill-developed, not filling the cranial cavity, but equal on the two sides; the occipital lobes did not cover the cerebellum. On section the ventricles were seen to be distinctly dilated. The optic thalami were very small, shrunken, and corrugated. Some meningitis of old standing. The corpora striata, cerebellum, and other parts of the brain were normal.

There was some consolidation in the upper lobe of the right lung,

Digitized by Google

but the other viscera were healthy. The optic nerves examined microscopically showed distinct inflammatory changes.

Family history—Father.—His forehead is retreating; he has on more than one occasion gone out of his mind, but he is intemperate.

Mother.—Healthy. Never any special difficulty in her labours. There have been several children, of whom only two are now living.

The elder, æt. 17, can neither read nor write, although he has been to school. He has a low receding forehead and a misshapen head, which is rather small than large.

Of the children who are dead, one, which lived to be 3½ years old, could never walk, and at 18 months lost its sight and the use of its arms and legs, and continued in that state till it died.

Another child never "took notice properly," and died of convulsions.

The specimen is preserved in the Museum of St. Thomas's Hospital. *May 3rd*, 1881.

---

3. *Tumour (and microscopic section) of optic tract from a case of diabetes insipidus.*

By Norman Moore, M.D.

The tumour is a glioma involving the optic tract on each side the chiasma and both optic nerves.

When fresh the external surface of the growth was reddish, and the section showed a firm reddish substance, with two small patches of pale degenerate tissue.

The tumour extends from half way along each optic tract to the optic foramen. It was of slightly greater circumference on the right than on the left side.

The only other morbid appearance in the brain was a very slight deposit of lymph on the under surface of the optic chiasma.

The microscopic section shows the characteristic structure of a glioma.

The patient was a man aged 34, who was in St. Bartholomew's Hospital from December 7th, 1880, to January 15th, 1881, under the care of Dr. Church. He was suffering from diabetes insipidus.

On admission.—He said he had been losing flesh for about nine

Digitized by Google

months. His sight was impaired, and ophthalmoscopic examination showed advanced white atrophy of the left optic nerve and great paleness of the right disc. His sight became worse, and on December 30th he was quite blind. He passed from thirteen to seven pints of urine daily, and it contained neither sugar nor albumen. For the last week of his life he was delirious, and for the last two days lay in a state of stupor.

Post mortem.—His kidneys were found free from disease, and there was no other lesion than the cerebral one.

Diabetes insipidus is confused by old writers, and occasionally to this day, with the polyuria of interstitial nephritis.

This case is shown by the *post mortem* not to have been one of renal disease. I examined the urine most carefully for sugar, and this was done by other competent observers on several occasions, and no sugar was ever found. The sp. gr. of the urine was 1004—1006.

Lancereaux, in a paper on diabetes in general, has mentioned some cases of injury of the skull in which there was diabetes. In some of these the diabetes was non-saccharine. I noted when reading his paper that the injury in most of the non-saccharine cases was in the anterior part of the skull.

Lancereaux does not point this out, but I think it worth remark in connection with this glioma of the optic tract associated with a non-saccharine diabetes. *May 17th*, 1881.

---

4. *Pyocephalus. Brain of a child aged five months.*

By Norman Moore, M.D.

The lining of the ventricle is universally injected and the ventricle much dilated.

Post mortem.—Both ventricles were distended with pus, an ounce and a half in each. The central canal of the cord contained pus, and so did the subarachnoid space. There was recent lymph around the roots of the nerves from the back part of the optic chiasma to the medulla, where it was thickest. No tubercle in the brain or on pia mater or in the body.

On September 25th I saw the child as an out-patient at the Metropolitan Free Hospital. It had then had a fit a week before,

Digitized by Google

but had otherwise been healthy. It had slight cervical opisthotonos. It was admitted under Dr. Church's care at St. Bartholomew's Hospital. It sucked well, and seemed no worse till October 8th, when it had several fits, the opisthotonos increased, and it died. Its temperature was at first just above normal, but rose to 101·2° three days before death and the night before was 103·4°

This was a case similar to the twenty-five recorded by Drs. Gee and Barlow in the 'St. Bartholomew's Hospital Reports' for 1878, and to that recorded by myself in the 'St. Bartholomew's Hospital Reports' for 1879. The extreme pyocephalus probably occurred when the temperature rose, the lesion during the first part of the disease being only some degree of meningitis about the medulla.

October 18th, 1880.

---

5. *Spinal cord showing dilatation of the central canal.*

By Norman Moore, M.D.

The cord is from a married woman, aged 22, who was a patient under the care of Dr. Andrew in St. Bartholomew's Hospital. Two years before her death she had some loss of power in her left arm, and this became progressively worse. Six months before death her right arm was similarly affected. Some months before death her voice became husky, and she ceased to be able to speak in a loud tone.

From the superior edge of the deltoid muscle upwards she had more or less complete anæsthesia; all her muscles seemed feeble, and on faradization there was hardly any reaction. She had no loss of power in her legs. Her breathing was always snoring. She had what seemed an epileptic fit and died, having been in the hospital a little over three months.

In the brain the pia mater seemed slightly adherent in parts. The lateral ventricles, iter, and fourth ventricle were distended with clear fluid.

In the cord the meninges were normal, but the cord itself, instead of being a cylinder, had become a mere tube filled with fluid. The cavity was not due to any breaking down of the cord, but to dilatation of the central canal. The dilatation extended

Digitized by Google

throughout the cord, but was very slightly greater in the upper part. The cavity readily admitted the little finger.

The other viscera were normal.

Abnormal cavities in the cord are rare, but have been described by Leyden, and by Dr. F. Taylor ('Path. Trans.,' vol. xxix) and others, but this is the largest cavity yet recorded with a complete vertebral canal, and differs from some of the others in being precisely conterminous with the walls of the central cavity.

October 18th, 1880.

---

6. *Tumour (glioma) of the spinal cord and medulla oblongata; dilatation of the lymphatics; large cavity occupying the position of the central canal (syringomyelus).*

By Thomas Whipham, M.B.

(With Plates I and II.)

John S—, aged 33, a bricklayer, was admitted into St. George's Hospital, under the care of Dr. Barclay, on October 29th, 1869.

He first felt numbness in both hands, his grasp became enfeebled, the right suffering more than the left, and he became an out-patient at St. George's, in December, 1868, under Dr. William Ogle. He had worked occasionally in white lead, and to this was attributed the symptoms of palsy which affected his hands. There was no history of venereal disease. Under galvanism he improved sufficiently to be able to work through January and February, 1869. In the beginning of March he became worse, suffering from pain and stiffness in the neck, with pain on motion. He then became an in-patient at the hospital in Queen Square, and remained there for four months. In July he left this hospital unimproved, was at home for six weeks, and then went to Bath.

Inability to walk was first noticed in April, 1869, and since that time he had gradually lost power in all his limbs.

On admission into St. George's, he was suffering from very decided paralysis of his arms and legs; he had no power in the right upper extremity, and had slight power of movement of the fingers of the left hand. He had very decided paralysis of the intercostal muscles and of both lower extremities; he could move the knees and the flexors of the feet, but had very little power in

Digitized by Google

Digitized by Google

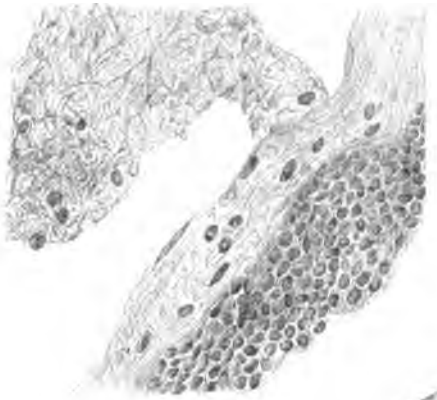

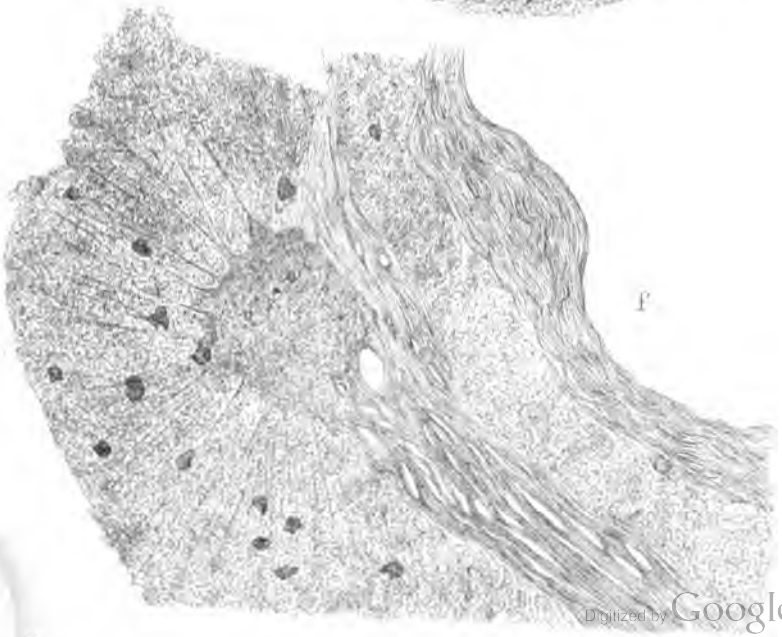

Digitized by Google

Digitized by Google

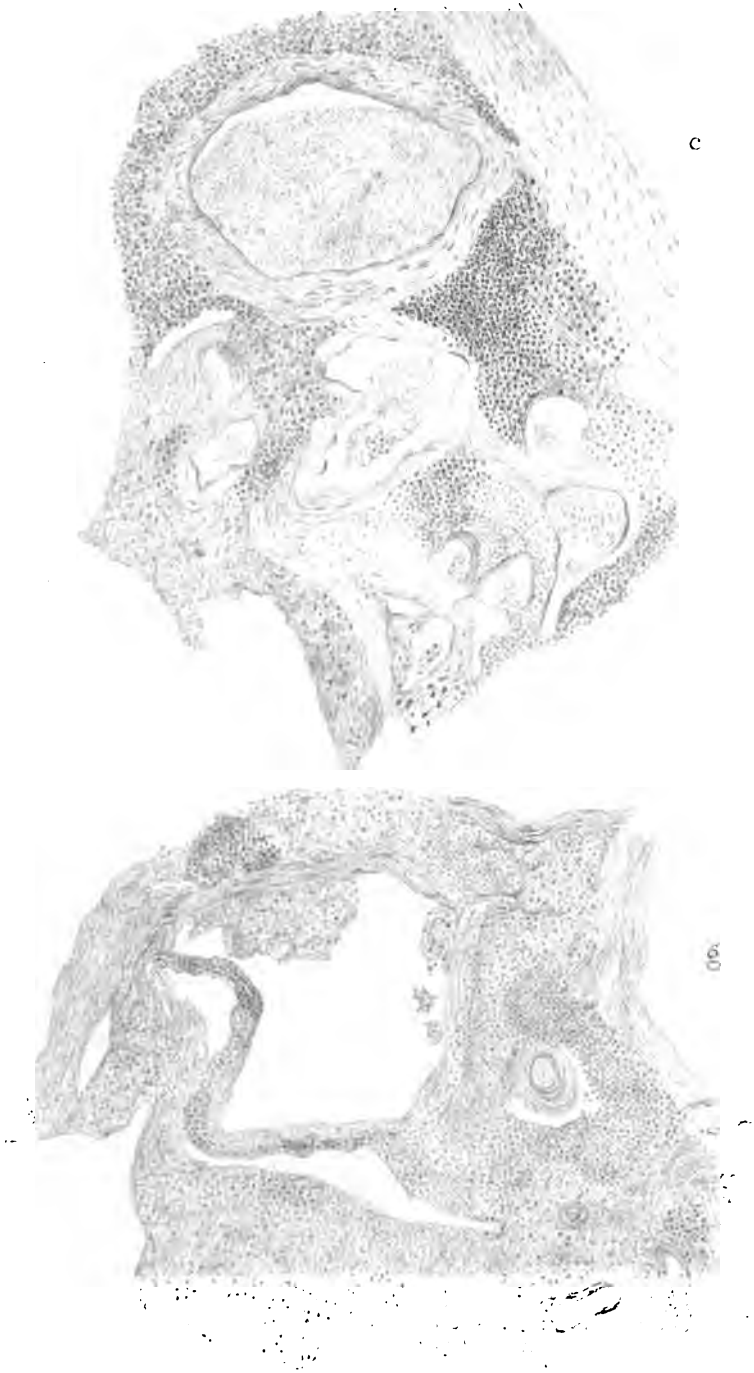

Digitized by Google

DESCRIPTION OF PLATES I & II.

Plates I and II illustrate Dr. Whipham's Case of Tumour (glioma) of the Spinal Cord and Medulla Oblongata; Dilatation of the Lymphatics; Large Cavity Occupying the Position of the Central Canal (Syringomyelus).

a, *b*. Tracings from sections through the entire thickness of the cord, showing the central cavity. (Natural size.)

a. Cervical region.

b. Dorsal ,,

c. From the cervical portion of the cord, showing at the upper part an artery, in the centre and to the right, dilated lymphatics with their contents coagulated. Around these vessels is the new growth. At the lower part of the drawing and to the left is some unchanged nerve tissue. (Magnified 70 diameters.)

d. Part of the central dilated lymphatic in *c*, more highly magnified.

e. Shows the fibrous walls bounding the dilated central canal; with deeply stained, semi-transparent homogeneous masses, racemose in form (probably serum) in the white matter beyond.

f. Shows alteration in the grey matter from pressure. In the centre of the drawing the anterior cornu; below it and to the right, the posterior cornu changed by pressure; on the left, white matter containing the racemose masses; on the right, the fibrous wall of the central cavity.

g. Shows a dilated lymphatic, the new growth invading its walls; at the lower part and to the left normal nerve tissue.

Digitized by Google

Digitized by Google

the extensors. Of the right hand the muscles were much wasted, especially the interossei (as in lead palsy), and the fingers were doubled on to the palm; the hand dropped when the forearm was held. The left hand was not dropped, but the fingers were clenched. Similarly the feet were turned inwards. Tickling one foot excited movement in the other; sensation was perfect, and he readily appreciated heat and cold. He had a certain amount of power in the sphincters. His sight was good; his urine natural.

Under perchloride of mercury he gained power at first and could retain his urine and fæces.

On November 16th his gums became spongy and the mercury was omitted. About this time a bedsore formed, which gradually enlarged. His intellect remained unaffected to the last. Two days before his death his breathing became embarrassed, cyanosis supervened, and he died on January 2nd, 1870, having previously lost all power over the lower extremities, with nearly total paralysis of his arms.

The above notes are taken from the records of the then medical registrar, Dr. Reginald E. Thompson.

Examination of the body twenty-four hours after death.

Externally.—The body was much emaciated; over the left hip-joint was a large bedsore, exposing the great trochanter; there was another over the right hip, and a third over the sacrum.

Lungs.—The lower part of the left lung was in a state of red hepatisation with here and there circumscribed patches where the pneumonia had reached the grey stage. The base of the right was much congested; the apex emphysematous. The bronchial mucous membrane was greatly congested, and the tubes contained rusty mucus.

Heart.—The right side was dilated.

Spleen.—The spleen was soft and pulpy.

Liver.—The liver was congested.

Kidneys.—The kidneys were finely granular; their capsules adherent.

Brain and meninges.—Natural.

Spinal cord.—There was a very remarkable condition of the spinal cord. The upper four inches of the cord, including the medulla oblongata, was, compared with the lower parts, greatly enlarged, and the theca much thickened and adherent. This enlargement was soft and a sense of fluctuation was evident to the finger.

Digitized by Google

After hardening in spirit this swelling was found to be due partly to infiltration of the substance of the cord by a new growth, and partly to the existence of one large cavity occupying the position of the central canal, and also to many smaller ones in the substance of the cord itself. The measurements of the larger cavity, which terminated in a *cul-de-sac* in the upper part of the medulla oblongata, were as follows: width in the antero-posterior direction $\frac{5}{16}$ inch; in the lateral direction half an inch.

Owing to the pressure caused by the disease the normal external appearances of the medulla were obliterated, *i. e.* no traces of the pyramids, olivary bodies, fissures, &c., could be discovered.

The inner wall of the cavities had a dense, white, glistening appearance, as if lined by membrane; their contents were a turbid dark fluid and a soft gelatinous mass, which only partly filled the larger cavity, and which was semi-transparent and of a reddish-brown colour.

A few drops of the gelatinous contents were examined microscopically, in the recent state, with the following result:—Numerous small cells were seen, for the most part round, though some were shrivelled, and presented an irregular outline. They were embedded in an homogeneous and granular stroma, or in places in an extremely delicate reticulum. Some of these cells were so small as scarcely to exceed the size of the red blood-corpuscles.

Throughout the whole length of the cord was an oval cavity occupying the position of the central canal, commencing, as has been stated, with the enlargement in the medulla oblongata. In the lower dorsal region this cavity measured $\frac{3}{16}$ inch in the lateral and $\frac{1}{8}$ inch in the antero-posterior direction, and the contents presented naked-eye appearances similar to those found in the cavities in the upper part. Transverse sections were made of the cervical (enlarged) portion, and also of the lower dorsal region. The former was found to be occupied by an extensive new growth, consisting of small cells embedded in a granular homogeneous matrix: in some few places a delicate reticulum could be made out. This growth was abundantly supplied with blood-vessels, which in many places were of large size; the cells were round or oval in shape, and of uniform size, rather larger than leucocytes. Here and there the cells showed a tendency to assume a linear arrangement, and under these circumstances they were more distinctly elongated than in other parts of the tumour.

Digitized by Google

The most remarkable feature of this portion of the cord was an extraordinary dilatation of the lymphatics, whose walls were thickened, and in many places infiltrated with the new growth, and whose contents were coagulated lymph, in which a few lymph cells were embedded (figs. *c* and *g*). The normal structure of the cord was in this situation almost entirely destroyed.

In the lower dorsal region the following appearances were noted: —The inner surface of the cavity, which involved the whole length of the cord, had the appearance of a dense, white, and glistening membrane; and this was shown by the microscope to consist entirely of fibrous tissue; more externally the white matter of the cord was natural, save only that numerous semi-transparent homogeneous masses, racemose in form, which became deeply tinted with hæmatoxylin (probably serous exudation), were embedded in its substance (fig. *e*). No traces of the normal epithelium of the central canal could be detected, either here or in the cervical region, and, save that the cavity occupied its position, it bore no resemblance to the central canal of the spinal cord. The fibrous wall bounding the cavity was somewhat sinuous in outline.

In the sections of this lower dorsal region the anterior horns were seen, one on each side of the anterior extremity of the cavity (which was more or less oval in shape, the length of the oval being in the antero-posterior direction). The horns were widely separated by nerve tissue, 'on the stretch,' and also in part by the fibrous walls of the central cavity. They were, moreover, flattened laterally from pressure, their inner parts more especially. The ganglion cells were very few in number, were reduced in size, and greatly altered in shape. Here and there one presented a more or less polar appearance, but the majority were irregularly triangular or linear in form, as though from the effects of pressure.

In the posterior horns the nerve tissue bore more evident traces of pressure, and was arranged, somewhat after the manner of fibrous tissue, in curved lines, following the outlines of the central cavity (fig. *f*). No ganglion cells could be found in this situation. Empty spaces, oval or linear, separated the nerve tissue in the thus altered posterior horn. In the white matter of the posterior columns and, indeed, of all parts of the cord, the homogeneous racemose masses mentioned above abounded; otherwise no change was evident in the outer portions of the cord.

The exact size of the cord, showing the central cavity also, is

Digitized by Google

represented in figs. *a* and *b*, the sketches having been traced from mounted sections.

Remarks.—This case appears to furnish an explanation of the cause of some of these cavities in the spinal cord, of which several are on record. Dr. Frederick Taylor ('Path. Soc. Trans.,' vol. xix, p. 21) narrates a case in which a somewhat similar condition (possibly congenital) was found in the cord of a child. In his case, however, the cord was free from new growth. He alludes to the various theories which have been advanced as to their causation, viz. that they may be due;—

1. To softening of a new growth in or around the central canal.
2. To hypertrophy and subsequent softening of the ordinary tissue surrounding the central canal.
3. To inflammatory changes.

A probable explanation of the present case is that the new growth, which primarily involved the medulla oblongata and cervical region of the cord, had made its way into and had dilated the central cavity.

The question, then, arises as to whether the cavity found in the lower parts of the cord was due to the same cause. I think it may be assumed that this was the case, for the contents of the cavity, in all parts of the cord were precisely similar in appearance. If so, the excavation of the lower portions of the cord would seem to be due to the fact that the growth had made its way into the central canal in the cervical region, and had gradually extended downwards, producing by its pressure dilatation of the central canal, destruction of its epithelium, and alteration of the structure of the cord.

It must be remarked that in sections of the dorsal region no traces of the new growth could be detected in the substance of the cord. Seeing, however, that the contents of this cavity in the lower parts were to the naked eye exactly similar to those found in the cervical region, it would seem more than probable that the cavity was due to dilatation of the central canal by the new growth.

The term syringomyelus has been suggested to express a condition of the spinal cord in which a large cavity is found in the position of the central canal. The expression is a convenient one, inasmuch as it involves no theory as to the origin of these cavities.

March 3rd, 1881.

Digitized by Google

7. *Paralysis of third, fifth, and sixth nerves of four years' duration, in a girl, aged fourteen, the subject of inherited syphilis.* (*Living specimen.*)

By E. NETTLESHIP.

THIS patient, Bessie C—, aged 14, is the eldest of a family consisting of five children and several miscarriages. There is a history of secondary syphilis in her father seven or eight years before her birth. Her mother died a year ago in childbed, and the patient's early history is defective. Her father gives no history of fits or other cerebral symptoms; she had measles when four years old, and has always been considered delicate. When about six years old she was blind of both eyes (interstitial keratitis). Her sight appears to have been good until then. According to her account, about four years ago her right forehead, cheek, and eyeball became numbed, and have remained the same ever since. She has also had some abscesses about the left lower jaw, and has lost the greater part of the bony septum of the nose. No history of orbital inflammation.

Present condition.—She is undergrown, but intelligent; frontal eminences prominent and square; skin fine, complexion sallow. Bridge of nose sunken; there is a large hole in the septum, and some carious bone far back in the nasal cavity. Left upper central incisor notched, right tooth wanting; lower incisors wanting; one of the first molars shows a crumpled grinding surface, but without absence of enamel, the other first molars are carious. Very slight deafness; several scars under the left lower jaw and in front of the ear. Remains of old kerato-iritis and abundant old choroiditis disseminata.

There is partial numbness of the right forehead, cheek, and side of nose, and of the eyelids, conjunctiva, and cornea. She can feel, but less distinctly than on the other side. The numbness appears greatest on the eyeball itself. Complete paralysis of the external and superior recti, and paresis of the inferior and internal recti and levator palpebræ; superior oblique probably paralysed. There is a transverse patch of opacity on the cornea, probably the result of exposure. The right eye is much less prominent than the left, but it is not clear, whether this is due to difference in size, or to protrusion of the left. T. n. in each eye.

Digitized by Google

The condition of sight is accounted for by the state of the cornea, iris, &c., and is much worse in the right than in the left; with the left she sees $\frac{2}{40}$ and 1 J. The refraction in the left (more prominent eye) is slightly hypermetropic; in the right it cannot be ascertained owing to the corneal opacity. *October 19th*, 1880.

---

8. *Enlargement of median nerve; congenital syphilis.*

By J. A. Ormerod, M.B.

The patient is a married woman, aged 23. Her general health appears good. The median nerve of the left side, rather more than half way up the upper arm, is thickened. The tumour is fusiform in shape, as thick or thicker than a large quill, tender to pressure; handling it causes numbness down the arm.

The muscles rising from the internal condyle of the humerus and those of the ball of the thumb are wasted, and have lost their farado-contractility. She can perform the motions of pronation, flexion of the wrist, fingers, and thumb, but less readily than with the other hand. The movements of the index finger are particularly hampered, and she cannot flex the last joint of the thumb.

There is anæsthesia in the two distal joints of the index and middle fingers, and in the last joint of the thumb. In October last the skin on the distal joint of the index finger was red and shining, and presented a small patch of ulceration, but these appearances have now gone.

The history is as follows:—Five years age she had bad pain in the left upper arm, worse at night, which, however, passed off without further effect. Two and a half years ago severe pain began again, developing in about a week, and causing numbness down the arm. After this followed the paralysis, wasting, and anæsthesia.

The patient is also the subject of congenital syphilis. She has well-marked pegtop incisors, very hazy corneæ, and is deaf, principally with the left ear. As the tuning-fork, whether in the air or upon the cranium, is heard with the right ear only, I presume that either the labyrinth or the auditory nerve has suffered on the left side. The optic nerves present no sign of neuritis or atrophy.

Digitized by Google

I would suggest that the nervous affection is in some way connected with the congenital syphilis, and that upon the following grounds:

First. The absence of any other cause, such as injury, chill, gout, &c. There is no history or symptom pointing to anæsthetic leprosy.

Secondly. The fact that the ulcer has healed under the admistration of iodide of potassium.

Thirdly. The statement of the patient that the deafness either began or was greatly aggravated in the twelve months preceding the outbreak of the nervous disease. *January 4th*, 1881.

---

9. *Gummatous disease of brain, cranial bones and vertebræ. (Card specimen).*

Exhibited by JONATHAN HUTCHINSON, for FURNEAUX JORDAN.

A MAN, about 45, came into the Queen's Hospital with a clear history of former syphilis. Above the centre and a little to the right of the frontal bone was a disc of exposed dead bone.

He was much wasted, and had recently become paraplegic and subject to complete retention of urine. His thought and speech were markedly sluggish, but no other nerve symptoms were present. He sank from exhaustion. After death there were found, as seen in the specimens, gummy nodules in the brain on its surface in close proximity to the necrosed bone; in the diploë also, under the affected bone, was a gummy nodule; smaller nodules were seated in the bone around. In the dorsal portion of the cord were other gummy nodules, and also in the bodies of the vertebræ opposite the affected part of the cord. There were patches of softening in the cord near the nodules.

It should be added, that in the skull only the outer table was necrosed; the corresponding diploë and inner table were replaced by gummy material. *May 17th*, 1881.

Digitized by Google

II. DISEASES, ETC., OF ORGANS OF RESPIRATION.

1. *Case of a nutshell impacted in the larynx; tracheotomy; membranous tracheitis, and purulent bronchitis; collapse of lungs.*

By R. E. Carrington, M.D.

The child T. B— was admitted into Mary Ward, Guy's Hospital, on April 6th, 1881, under the care of Dr. Moxon. Mr. Jacobson was subsequently called in on account of the surgical bearing the case presented. By the kind permission of these gentlemen I am able to bring it before the Society.

The boy appeared to be a healthy little fellow, and was well nourished. This was his first illness.

On April 16th, after the autopsy, a careful personal investigation of the child's surroundings was made by Mr. Bartlett, the clinical clerk. He found that the child's sister was then very feverish, with a quick pulse and a bad cough; from this last symptom, however, she had suffered ever since an attack of pertussis, which she contracted about this time a year ago. He again visited her on April 19th, and then he found her fairly well, playing about, with a good appetite, and suffering from nothing except the cough. Beyond this no other child nor adult in the house has been ill, neither has there, to the best of the parents' knowledge, been any similar affection to that from which their child has died in the neighbourhood—neither croup, diphtheria, scarlet fever, measles, nor smallpox.

The sanitary condition of the house was also investigated. The drains were all found clear and well flushed, and the place was not damp.

The history that was given on the admission of the boy was, that he was well until the evening of April 5th, when "he seemed

Digitized by Google

to have a cold," and this was somewhat relieved by poultices. Between 9 and 10 on the morning of April 6th, croupy breathing supervened, but the child was up and about all day, and took his food well and freely.

His breathing again became bad at 4 p.m., and he was admitted in Guy's Hospital between 6 and 7 p.m. The history was thus distinctly of a gradual onset. On inquiry after the *post-mortem* examination, it was found that the child had had some nuts given to him, which he had eaten on the evening of April 4th, one day, before the onset of symptoms, and two before coming into the hospital.

On admission the following condition was found:—The patient was breathing with difficulty, restless, and with a fretful expression of countenance. He lay chiefly on his back taking, however, notice of his surroundings, and playing with his toys. He was very irritable during the clinical examination.

The skin was warm and moist, and without eruption of any kind. The nails were somewhat blue. The complexion waxy. The tongue was furred; no membrane was detected on any part of the tongue, fauces, tonsils, or pharynx. There was no glandular enlargement. Both inspiration and expiration were stridulous, and there was sucking in of the intercostal spaces. The lungs appeared to be healthy.

At 7 p.m., April 6th, the temperature was 101·8°, the pulse 160, and the respirations were 52.

At 8.30 p.m., under Mr. Jacobson's superintendence, tracheotomy was performed by the house-surgeon (Mr. Saunders). The operation afforded relief for a short time, but dyspnœa again supervened. He coughed occasionally but not frequently, but raised nothing. The difficulty of breathing was chiefly inspiratory, the episternal region and intercostal spaces being sucked in, and the nares dilated. Respiration was very loud hurried and crowing. The heart's action was very rapid, the pulse very feeble and difficult to count, the number being 160.

	Temp.	Pulse.	Resp.
11.30 p.m. .	100·4	142	42
1.30 a.m. .	100·6	160	46

Progress of the Case.

April 7th, 11 a.m.—He was breathing quickly. Moist sounds

Digitized by Google

were now detected at the lower part of the chest, especially on the left side both in front and behind, and on the right side behind.

The pulse was 166, the temperature 100·4°, and the respirations were 42.

	Temp.	Pulse.	Resp.
2 p.m. . .	102·4	170	40
4 p.m. . .	102·4	172	48

At 4 p.m. the patient was much quieter and even apathetic. The finger nails and lips were very blue. Respiration was more laboured.

Mr. Jacobson now ordered poultices to the chest.

At 5 p.m. the tube was removed and the tracheal opening slightly enlarged. Two pieces of membranous substance now came away. After this the child breathed more quietly.

	Temp.	Pulse.	Resp.
6 p.m. . .	101	150	56
12·15 a.m. . .	100	166	42
1·30 a.m. . .	100·6	156	56

8th, 11.15 a.m.—Respiration easier but still hurried. The lips and nails were not quite so blue. The child lay semi-comatose, but occasionally started up, and kicked off the bed clothes. Auscultation detected no abnormal sounds. Inspiration and expiration followed one another in rapid succession, the former being slightly the longer.

1 p.m.—Temp. 101°, respiration 60.

The patient again became cyanosed. He drank freely. The excreta were passed in bed. On listening to the bases no crepitations were audible, the other parts were not examined.

4 p.m.—The child was very restless at times, rolling over in bed, and becoming very blue, then he would lie down and become semi-comatose. Now and then he ground his teeth and bit his tongue. He was also sick, and after vomiting on one occasion, a piece of fleshy membrane was removed from the mouth. At times there was a slight convulsion.

At 6.30 the patient died without struggling or gasping, but was apparently slowly asphyxiated.

The autopsy was made by myself, twenty hours after death.

The lower lobes of both lungs were extensively collapsed, but the tissue was still crepitant. The upper portions were healthy. There

Digitized by Google

were no signs of pneumonia. Both pleuræ were healthy. No membrane was found on the fauces, tonsils, or in the pharynx.

The glottis, looked at from above, before opening the larynx, was perfectly natural; there was no swelling of the arytæno-epiglottidean folds or surrounding parts. The tracheal wound was about three quarters of an inch in length, somewhat ragged from the second incision. The trachea and larynx were then opened up from behind. The interior of the larynx, as low down as the glottis, appeared perfectly healthy. The vocal cords were normal, On the right side of the larynx, about half an inch below the right cord, was found a piece of nutshell about one quarter of an inch in diameter, flattened, with jagged irregular edges. It was by no means firmly impacted, but readily came away by a touch of the probe, disclosing beneath a small ulcer about one-eighth of an inch in diameter. The nutshell was surrounded by, and embedded in, viscid mucus. It lay as it were under cover of the right side of the glottis, and had, laryngoscopic examination been possible in so young a patient, it would not, I am confident, have been discovered, neither was it visible from the tracheal wound. It did not seem that the shell was the focus of the disease found lower down, for from the point of impaction as far as the lower end of the tracheal incision the interior of the tube was simply reddened.

Commencing, however, at this latter point, the trachea as far as its bifurcation was coated with yellowish ashen-grey false membrane. The coating was not very thick, nor very consistent, but it was shreddy, and easily detached. I have no hesitation in describing the inflammation as being distinctly and undoubtedly membranous. The coating was, I have said, not very thick nor consistent, but I could undoubtedly peel off membrane, and there was certainly as much as may be found in many cases of undoubted diptheria. I may add that the specimen was seen by Dr. Goodhart who concurred in my account. The membrane gradually shaded off below into thick muco-pus, with which both the bronchi and larger bronchial tubes were copiously filled; it appeared, however, not to have spread to the smaller ramifications, at least as far as could be ascertained by squeezing a freshly cut surface at the periphery of the lung.

With the exception that the liver was full of blood, all the other organs were quite healthy.

I have thought this case worthy of the attention of the Society,

Digitized by Google

both on account of the clinical history, and also because of its bearing, I venture to think, on the much vexed diphtheria-croup controversy.

The clinical point, upon which, however, I do not intend to dwell, is the history of gradual onset, as far as could be ascertained. The child ate the nuts on the evening of April 4th, and it was not until after a lapse of at least twenty-four hours that anything was noticed. There was certainly nothing in the nature of a sudden paroxysm of dyspnœa. A sudden onset is certainly laid down as one of the criteria in the diagnosis of a foreign body in the air-passages. It was certainly so in two cases recorded by Dr. Gee in the 'St. Bartholomew's Hospital Reports,' vol. xvi; but the present case would seem to show at least, that this symptom is not always to be expected. Doubtless the nature, size, form, and position of the body will determine its absence or presence in any particular case.

I venture, however, to report the case as an instance of membranous inflammation of the trachea not due to diphtheria. I have detailed the negative points in the course of the history, and it would be tedious now to recapitulate them. The only point in favour of diphtheritic origin is the illness of the patient's sister, but when seen by Mr. Bartlett, she was certainly affected, neither with croup, diphtheria, nor any exanthem, and it is pretty certain that her illness was simply an attack of bronchitis or broncho-pneumonia, from which she had been suffering for many months prior to her brother's fatal attack, and that on his second visit, with exception of the cough, she was well of the exacerbation which he had discovered on his first. What the cause of the formation of the membrane was, I am in doubt. It certainly did not seem to start from the impacted body, on account of the zone of comparatively healthy tissue between it and the false membrane, whilst at the same time the commencement was exactly localised at the lower end of the tracheal incision. The question arises of infection from without, or from the tube itself. With regard to the former, there were neither croup nor diphtheria in the ward at the time, neither had there been for a very long time before, if at all; for the ward is one in which these cases are not admitted in the usual way. As to the latter possibility, I, for my part, cannot allow it; I have no doubt that the tube was scrupulously clean. Further, in reference to this point, there is a small though unimpeachable group of cases of membranous laryngitis and tracheitis

Digitized by Google

following traumatic causes to which allusion will be presently made, and it seems to me to be absurd and improbable to say that all of them can be accounted for by unclean instruments.

The suggestion I would venture to make is, that the irritation of the foreign body set up paroxysmal spasm of the glottis, leading to collapse of the lungs, and that the irritation of the tracheal wound, perhaps increased by the second incision, caused the membranous inflammation, which undoubtedly travelled from above downwards.

In the 'Guy's Hospital Reports' for 1877, Dr. Fagge has recorded sixteen cases of membranous inflammation of the air-passages due to traumatic causes, viz. scalds by hot water, foreign body, cut throat, and tracheotomy; or secondarily, to disease of the air-passages. I may here mention that the *post-mortem* examination of the tracheotomy case was made by the President, and that he suggested that the tracheal wound seemed to be the focus of inflammation in the report he made of that autopsy.

The case of cut throat was very similar in the distribution of the membrane to the one under consideration. In the Report of the Diphtheria-Croup Committee, another case is recorded as due to the accidental introduction of eau-de-Cologne into the air-passages. These cases, however, are but a small proportion of the instances of membranous laryngitis and pharyngitis due to other causes, notably diphtheria. This then is my justification for troubling the Society with the present case. *April 19th*, 1881.

---

2. *Chronic excavation of the lung, terminating in localised pneumothorax, with extensive opening into the lung.*

By Samuel West, M.B.

E. L—, a youth of 22 years of age, was admitted into Victoria Park Hospital in December. He was one of a family of thirteen, of whom none had weak chests, and had been in good health up to five months before admission; when, after having been for some little time out of work and in want, he began to be troubled with a cough, abundant expectoration, which was occasionally blood-streaked, and pain in the left side. Since then he

Digitized by Google

had rapidly lost strength and flesh, and had suffered for the last month from sleep sweats.

On admission, the diagnosis was made of a large cavity at the left apex, and considerable destruction of lung, probably another large cavity, at the base.

A few days later, after having been fairly well in the interval, he was seized with severe pain in the left side, and with dyspnœa, which was considerable for twenty-four hours and then became less marked. He at the same time spat up a large quantity of purulent matter, and continued to do so for some days. The physical signs remained as before at the apex, but changed at the base and in the axilla. Here the percussion, which had been impaired, became drumlike (tympanitic), except at the base behind where it was still impaired. The vocal vibrations were less than on the right side, and the vocal resonance was very loud and direct and the respiration loud, almost roaring, and intensely amphoric. No bell or metallic sounds; no succussion. The cardiac dulness was considerably diminished, but seemed to reach a little to the right of the sternum. The diagnosis lay between a very large excavation of the base of the left lung and a localised pneumothorax. But such intense amphoric breathing and vocal resonance, in pneumothorax, could only be produced when the opening into the lung was very large, and the communication between the pneumothorax and a large bronchus was direct. This is a condition so uncommon in pneumothorax, that it was felt that the more probable diagnosis was of a large excavation of the lung, the dyspnœa being due probably to the temporary occlusion of the bronchus, and the accumulation of pus in the cavity. No change in the physical signs occurred, but the patient gradually sunk; and *post mortem*, the pathological conditions were as follows:

The diaphragm was found, on opening the abdomen, to reach slightly lower than usual.

The heart was slightly displaced to the right side, and the pericardium contained about six ounces of clear serous fluid.

The left side of the thorax was contracted, and the left pleural cavity completely obliterated, except at the lower part from the mid-axillary line forwards to the pericardium and at the corresponding part of the diaphragm. Here was a localised pneumothorax containing about four ounces of chocolate-coloured fluid. The margin of the lung was adherent over the pericardium, and about

Digitized by Google

three inches from it was an irregularly oval opening about three inches by two inches, the edges of which were in places sloughing. This led directly into a large trabeculated cavity in the upper and anterior part of the lower lobe. This lobe on section was found to have another large cavity in the upper and posterior part, and what remained was airless, partly from collapse and partly from consolidation, in the form of firm yellow (caseous) nodules scattered thickly throughout (probably peribronchial in origin).

The right lung was emphysematous and congested, especially in the lower lobe, with numerous small pigmented peribronchial thickenings. In the middle lobe were some caseous patches, these were absent elsewhere.

The other organs were healthy.

The disease of the lung was, I believe, of much older date than the history of only three months' illness would seem to indicate. These cases of chronic excavation are most insidious, progressing slowly, often without producing any symptoms at all, it may be for many years, and then terminating suddenly either by the rupture of an aneurysm or the ulceration of a vessel—as in two cases I brought before the Society last year—or by the occurrence of bronchitis or an acute inflammatory affection of the opposite lung. The termination, as in this case, by pneumothorax, and especially one with so extensive an opening into the cavity, is very uncommon. The diagnosis, it is clear, between such a localised pneumothorax in free communication with a large bronchus through a wide opening in the lung and a large lung cavity, is always difficult and sometimes impossible, for the physical conditions are the same. *March 15th*, 1881.

---

3. *A case of gangrene of the lung from thrombosis in pulmonary artery.*

By B. G. Morison, M.B., C.M.

The case occurred in the practice of my friend Dr. Reid, of Canonbury.

The patient, A. C—, came under treatment only a few days before

Digitized by Google

death. The symptoms of gangrene of the lung were then well marked. The odour of his breath was very fetid, and perceptible outside of his room as well as in it. This excessive fœtor came on five days before death. There was a history of cough for a year previously, but the patient had persisted in going about, and only took to bed a week before he died. I should add that though breathing was rather laboured for some days, no convulsion or loss of consciousness preceded death. There was also a family history of "chest disease."

Post-mortem examination, performed twenty-four hours after death, showed: On the right side of the chest tough pleural adhesions, binding the lung to the chest wall, and especially firm at the apex and base of the lung and at the back part.

The *right lung* was not shrunk. On section it showed a series of ragged phthisical cavities, occupying the upper half. From these there welled out on pressure a large quantity of pale, greenish, pultaceous matter, not at all like ordinary muco-purulent secretion, and having a very offensive smell. The rest of the lung was soft, of grey-green colour, and at the base beginning to break down. There was no engorgement with blood, and no tubercles or broncho-pneumonic masses were seen, probably from the stage of degeneration being too far advanced.

The *left lung* was not adherent to the chest wall, and was brightly congested. Small, irregular, caseating nodules, of broncho-pneumonic origin, were scattered through the lower half. There was no sign of gangrene on this side.

The *pericardium* was normal, as was also the *heart*, except that in shape it was as broad as long, and the right ventricular wall was slightly thicker than the left, and healthier looking; the left ventricle on section appeared paler than the right, the wall of which was ruddy in colour, as seen on section. All the cavities contained clots; those on the right side for the greater part recent and dark; that on the left chiefly fibrinous, and consisting of a band half to three quarters of an inch in width, and continued from the left auricle through the mitral and aortic valves into the aorta.

On cutting the great vessels close to the heart a quantity of dark partly clotted blood was seen to escape from each, veins and arteries alike.

A microscopical examination was made of some of the greenish

Digitized by Google

pultaceous discharge from the gangrenous cavities, and the following appearances were noted:

1. Granular *débris*, either in the form of small rounded masses—evidently degenerated cells—or as an extended sheet, containing the rounded masses, and due probably to degeneration of the epithelial floor of an alveolus, or of a cast of it.

2. Some fibrous material with fibres splitting like those of yellow elastic tissue, or shreds of a fibrous character, with granular cells adjacent.

The *pulmonary artery* in the right lung was dissected and laid open; its walls were perfectly healthy. It was found to contain a fibrinous thrombus, unattached. This subdivided and ramified even into the smaller arteries, the smaller prolongations being lost ultimately on the confines of the gangrenous cavities. The terminal twigs appeared pale and fibrinous. The trunk at the mouth of the artery was partly composed of recent partly of fibrinous blood-clot. There was no embolic impaction in the pulmonary trunk or its branches. The whole, when dissected, was much shrunk from the action of methylated spirit, in which the lung was preserved. The pulmonary veins were unobstructed. A bronchial artery, dissected out at the exit of the bronchus from the lung, was not obstructed.

A microscopic section of the right lung showed the condition in it to be one of broncho-pneumonia, passing into caseation and cavity formation, with considerable pleural thickening and increase of interstitial connective tissue.

A section of the thrombus, about the mouth of the pulmonary artery, showed the clot to be recent and firmly contracted.

Remarks.—The cause of the thrombosis in this case does not seem to have been deficient cardiac power, not, at least, in so far as the right ventricle is concerned, for that was shown to be hypertrophic. But most probably the state of the pulmonary capillaries, obstructed as they must have been at various points by pressure of caseous products and of interstitial infiltration, furnishes the true explanation of the origin of the lesion. The more purely fibrinous character of the small branches of the clot, as compared with the trunk of it, and the slow supervention of death after symptoms of gangrene had existed for nearly a week, point to the small vessels and capillaries near the lung cavities as the earliest seat of coagulation. The fibrinous clot on the left side of the heart also suggests a secondary agent in a condition of blood which favours coagulation from excess

Digitized by Google

of colourless corpuscles. But the diseased condition of the small terminal twigs of pulmonary and bronchial arteries together, which has been alluded to, is probably the chief cause of the stagnation of blood in this case. *March 15th*, 1881.

---

4. *A case of excision of the anterior third of the tongue for epithelioma of its tip and sides, followed by gangrene of the lung.*

By H. Royes Bell.

Henry D—, æt. 60, was admitted into King's College Hospital on the 24th February, 1881, under Mr. H. Royes Bell's care. The tip and both sides of the tongue are invaded by a cauliflower-like, overhanging mass of epithelioma, which made its appearance for the first time six months ago.

The front portion, about one third, of the tongue was removed through the mouth by means of an ordinary écraseur, a wire being used to encircle the tongue. This portion of the organ is shown as well as the rest of the tongue, the stump of which has healed. Two glands about the size of large peas were removed at the *post mortem* from the floor of the mouth.

The man was operated on on February 26th, and had secondary hæmorrhage on March 6th, and on several subsequent occasions, in all six attacks, losing about four to six ounces of blood each time.

He was convalescent, with the exception of slight bronchitis, and about the ward, when it was noticed on March 14th that his breath was offensive. This symptom increased to such an extent that he became a nuisance to the patients in the ward, so he was transferred to a medical ward.

He expectorated a quantity of blood-stained mucus, which was but slightly offensive to the smell.

He died on March 21st.

A *post-mortem* examination showed emphysema of both lungs, with old pleuritic adhesions. The *right lung* was very firmly adherent to the chest-wall at one point, and on separating it the finger entered a sloughing cavity, and gave vent to a quantity of fetid gas. This large sloughing cavity was formed by a mass of

Digitized by Google

gangrenous lung of a triangular shape, and about the size of the palm of one's hand, which occupied the middle portion of the upper lobe of the right lung. At the point where the lung was adherent to the pleura there was a thick yellow layer of membrane lining the margin of the sloughing mass. The base of the lung was solid from inflammation.

The left lung was emphysematous, but otherwise healthy. The other organs of the body examined were found to be healthy. Microscopical sections from the cicatrized stump of the tongue and from a small lymphatic gland from the floor of the mouth were free from epithelial growth. *April 5th*, 1881.

---

5. *Two cases in which epithelioma recurred in the lung.*

By Rickman J. Godlee.

My reason for bringing these two cases before the Society is, because we have at present so few on record in which squamous epithelioma has occurred as a recurrence in the lung. I venture to think that this is not such a rare occurrence as is supposed, and that if surgeons up and down the country appreciated the fact of its supposed rarity, we should soon have many other instances on record. The cases it will be seen are also neither of them without interest on account of the actual microscopical structure of each.

Epithelioma of tongue with secondary growths in various situations, including the lungs.

Henry G—, æt. 56, a tailor, became afflicted with epithelioma of the left side of the tongue, which ran a usual course of some chronicity. There was no history of syphilis.

He was first seen in January, 1880, and he had then a small, hollow, epitheliomatous ulcer on the left side of the tongue, on its under surface, involving the floor of the mouth, with very hard edges. Several glands were enlarged on the left side of the neck. The patient was very much emaciated.

In the course of a few weeks the glands in the neck became

Digitized by Google

inflamed, and many more were involved at the lower part of the anterior and posterior triangles; as a result of which deglutition and respiration became extremely difficult.

On February 18th he was admitted to the hospital. There was then a red brawny swelling at the lower part of the neck, and over the upper part of the sternum, which presented in its lower part a distinct sense of fluctuation. The skin in this region contained innumerable very minute nodules of new growth, which were much more apparent when the swelling had somewhat subsided after an incision had been made in the fluctuating point. This incision was made on the supposition that suppuration might possibly have occurred in the growth; but the result was the evacuation of a clear fluid only. Lint and collodion were applied over the incision. The patient, who was excessively ill, lingered a few days and died on February 27th.

At the *post mortem* it was found that a very large number of minute nodules of the growth existed in the skin covering the left half of the thorax and abdomen. The mass at the root of the neck had perforated the manubrium sterni, and the bone was broken down into a fragmentary detritus, which had given a crackling feeling during life; the central portion of this mass was soft and contained an opaque serous fluid.

The lower part of this mass was continuous with a similar one in the anterior mediastinum. The outer part was continuous with the growth in the posterior triangle and side of the neck, which had also directly involved the apex of the left lung. This mass in the neck did not consist of isolated glands, but of an enormous spreading growth involving all the surrounding tissues, and encasing the great vessels. The left innominate and left internal jugular veins were completely obstructed by old clot, into the interior of which the growth was spreading; the right internal jugular also contained some old clot in its lower portions.

As to the *lungs*, subserous growths of the size of a pea were scattered over both, and numerous other independent nodules were found in the interior; and, in addition, the apex of the left lung was directly invaded, as stated above. The pulmonary arteries were slit up, but no emboli were found.

Most of the other viscera were invaded in a similar way. Thus, nodules were found on the surface and in the substance of the *liver*, in the cortex of the *kidney*, and in the *heart*. The suprarenal cap-

Digitized by Google

sules were infiltrated with the growth, and a few nodules were found in the subserous tissue of the *diaphragm*.

The *brain*, the *pancreas*, and the *spleen* contained nothing; the stomach and intestines were not examined.

In reference to the microscopical examination of the tumour, it must be pointed out in this case, as in that which I reported in vol. xxvii of our 'Transactions,' p. 253, that though no one, on carefully examining any one of the specimens, could possibly doubt that it is an epithelioma, still it does not conform exactly, except in one situation, and, strange to say, this is the kidney, with the ordinary structure of epithelioma, such as we usually meet with in the tongue. It is made up of a mass of epithelial cells, arranged more or less indefinitely, and with but little intervening stroma, exhibiting frequently an imperfect development of globes, and in some places well-marked ones, but, as far as I have seen, showing nowhere the crenated edges to the cells, which are so frequently observed in tumours of this kind. This description applies to all the positions in which the growth occurs, except in the kidney and the suprarenal capsule; the former shows a development of epithelioma as typical as the youngest student of histology could desire to see, and the structure of that which has invaded the suprarenal capsule, though not so typical, is much more characteristic of the disease than that which is found elsewhere.

These facts appear to me to be only an illustration of the great law that we find exemplified by all classes of tumours: viz. that the more a new growth departs in its structure from a normal tissue the greater is its malignancy. I need not dwell on the manner in which the sarcomas and the adenoids follow this law; and in the same way a well-marked epithelioma, which, after all, is only one step further down the scale of new growths than a wart or corn, shows but little tendency to involve distant organs but when, as in these cases, the structure is imperfect and rudimentary—that is, when either the connective-tissue element is greatly in excess, or the epithelial element shows a wide departure from the normal type—we find the growth disseminated far and wide throughout the body.

Another highly interesting feature about the growth in this case must also be mentioned. Just as the large mass over the manubrium sterni had broken down in the interior into an irregular cystic cavity, so had the process repeated itself, even in the most

Digitized by Google

minute tumours that were found elsewhere. This, as far as we observed, was without exception; even the smallest tumours in the kidney or on the surface of the diaphragm, showing this remarkable tendency to softening in the interior.

Squamous epithelioma of the bladder with secondary growths only in the left lung.

Ebenezer J—, æt. 78, was admitted under my care into hospital on March 30th, 1880. He appeared inordinately old, being almost literally wasted to a skeleton, with a shining skin and very great anæmia. He had been suffering with a difficulty in emptying his bladder for some time, but for the last few weeks before admission the urine had simply dribbled away. The prostate was not markedly enlarged, but a hard, ill-defined swelling was noticed on the right side of the abdominal wall, above Poupart's ligament, part of which swelling was evidently inflammatory.

An English gum-elastic catheter when introduced met at first with an obstruction in the penile portion of the urethra, and then passed with the greatest readiness over a rough track for a long distance; but a small amount of grumous, yellow, stinking stuff alone made its escape. Supposing the instrument to lie in the bladder, but blocked, I directed the house-surgeon to repeat the process, and wash out with a little quinine solution in the evening. The injection however, did not return. Next day the patient died.

At the antopsy, on opening the bladder, a large tumour, three inches in circumference, was found occupying the upper and posterior wall. The edges overlapped the surrounding mucous membrane for a considerable distance, and appeared to have preserved it from the chronic cystitis, signs of which were well marked elsewhere. The surface of the growth was remarkably ragged, and presented a number of irregular fungus-like projections into the cavity of the bladder, which also contained considerable loose masses of the growth and smaller *débris*.

From the middle of the tumour an opening passed into a ragged cavity, full of thick, stinking pus, in the cellular tissue of the pelvis, round which there had been a good deal of inflammation, the result of which had caused the tumour felt in the groin, and round which some peritonitis had occurred, and spread to the rest of the abdominal cavity. A false passage, of old date, occupied the position

Digitized by Google

at which an obstruction to the catheter was noticed. It seemed uncertain whether the catheter had entered the false passage or the cavity in the tumour on the right of the bladder.

The right ureter seemed to pass into the tumour, but the urine had not putrefied in the pelvis of either kidney.

The only secondary growth in this case consisted in a patch at the posterior and lower part of the left lung. It looked like a patch of pneumonia surrounding or involved by minute whitish masses of the new growth, which were breaking down at the lower part into what had the appearance of suppurating cavities.

The glands by the side of the abdominal aorta were not larger than usual, and, though hard, did not appear to have been involved by the growth.

The microscopical structure of the tumour of the bladder shows, in the deeper parts, an irregular collection of epithelial cells, not unlike that described in the last case, but, if the term is allowable, more rampant, with cells varying more in size, and an imperfect development of globes. In other parts there are gigantic globes and huge processes of epithelial growth, covered by a layer of horny epithelium. In the lung a beautiful epithelial structure is seen in many places, taking almost identically the appearance of the deeper layers of the skin, but in parts containing the enormous globes or irregular masses of horny epithelium which were seen in the bladder. Patches of this structure are found scattered through the pneumonic part of the lung.

Horny epithelium in the lung must be very uncommon. The position of the recurrence, and the fact that no glands were enlarged, suggests embolism as the cause, but I have no facts to support this surmise. *November 2nd*, 1880.

Digitized by Google

6. *Cancer of the right lung with embolism in middle cerebral artery.*

By Norman Moore, M.D.

Microscopic specimen showing a section of the new growth in the lung.

The section shows numerous bands of fibrous tissue, with alveoli containing epithelial cells. In some parts of the section these are seen to be columnar. The new growth is clearly of glandular origin, and probably began in the glandular crypts of the mucous membrane of the bronchi.

From a woman, æt. 56 years, under the care of Dr. Gee in St. Bartholomew's Hospital. The body was greatly wasted. During life diagnosis of cancer of lung was made from the fact that paracentesis yielded a blood-stained exudation, and that there were definite physical signs of pressure on the right bronchus, with enlarged and hard cervical glands. Shortly before death aphasia and right hemiplegia occurred.

Post mortem.—The right lung only was affected. Its surface showed numerous hard patches of whitish and tough new growth. This penetrated the lung for some little distance, and was continuous with a similar and very dense growth which spread into the lung from the root, pressing upon the first and other branches of the bronchus. On the costal pleura there was no growth. The pulmonary vessels seemed everywhere entire.

The mediastinal and cervical glands were very hard, enlarged, and infiltrated with new growth.

No new growth was found elsewhere. The breasts seemed normal, and so did the œsophagus, stomach, and intestines, including rectum. The peritoneum was normal.

The left frontal lobe of the brain showed a large patch of softening due to an embolus, which was found in the left middle cerebral artery, about one inch from the outer margin of the fissure of Sylvius.

A microscopic section showed the embolus to consist of fibrin only.

The microscopic structure of the cancer of the lung forbids the

Digitized by Google

supposition that the new growth began in the lymphatic glands, and from the general direction of the mass from the root to the periphery of the lung, it seems the most probable hypothesis that the new growth began in the glands of the bronchial mucous membrane, so that it may be spoken of as one of the uncommon examples of primary cancer of the lung.

November 2nd, 1880.

---

7. *Ulcer of bronchus (right) penetrating the pulmonary artery.* (*Card specimen.*)

Exhibited by NORMAN MOORE, M.D.

FROM a man, aged 24, who died of a profuse hæmoptysis. He had copious hæmoptysis on January 1st, 1881, followed by febrile symptoms, and on January 9th, had a more profuse hæmoptysis and died. His stomach, as well as his bronchi, was filled with blood. An eroded surface, as large as a shilling, is to be seen in upper part of the right bronchus. This ulcer has opened into the pulmonary artery. In the centre of the right lung was a cavity of walnut size, and near the apex a small cavity filled with cretaceous matter. Neither communicated with the bronchial ulcer. There is no tubercle of the larynx, and the unaffected tracheal rings seem healthy. A careful search was made for a foreign body but none was found. Other viscera healthy.

The ulcer looks as if originally due to a foreign body. If not due to this, an isolated tuberculous ulceration may have taken place at this point. *January 18th*, 1881.

8. *Congenital cyst in larynx.* (*Card specimen.*)

Exhibited by John ABERCROMBIE, M.D.

THE specimen shows a small tense cyst, rather larger than a hempseed, arising from the crico-thyroid membrane in the median line. Before the larynx was opened the glottis appeared to be blocked up by it.

Digitized by Google

There was slight emphysema of both lungs; the other viscera presented nothing noteworthy.

The child, a female, was fourteen days old at time of death. It was the eighth child, born at full time after a tedious labour. From its birth it had always had difficulty of breathing, and had never been able to cry.

May 3rd, 1881.

Digitized by Google

Digitized by Google

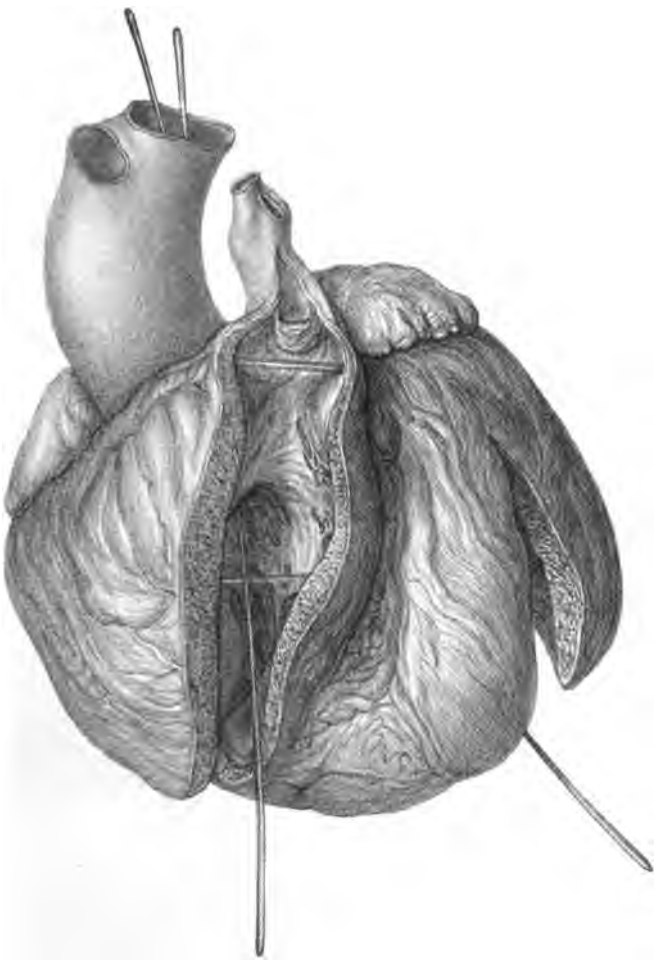

Burgess, del et lith

West Newman & Co imp

Digitized by Google

DESCRIPTION OF PLATE III.

This Plate illustrates Dr. Peacock's Case of Malformation of the Heart; Showing Constriction of the Orifice of the Pulmonary Artery; the Aorta arising from Both Ventricles; the Ductus arteriosus closed.

Digitized by Google

Digitized by Google

III. DISEASES, ETC., OF THE ORGANS OF CIRCULATION.

1. *Malformation of heart; great constriction or stenosis of the orifice of the pulmonary artery; aorta arising from both ventricles; defects in the fold of the foramen ovale; ductus arteriosus closed.*

By Thos. B. Peacock, M.D.

[With Plate III.]

The child which was the subject of this malformation was first seen by me at St. Thomas's Hospital in October, 1874. It was then six weeks old, and presented slight cyanosis. I saw it again in the spring of 1876, and the signs of malformation of the heart were then very marked. The lips, hands, and feet were very livid, the ends of the fingers and toes were clubbed, and the nails incurvated. The cyanosis was probably present from birth, but it first attracted decided attention when the child was nine days old. It had gradually become more marked since that time. The head was disproportionately large, and there was some inequality between the two sides. The jugular veins were greatly distended, and there was a systolic murmur heard in the region of the heart. The scrotum and inguinal regions were very livid, and in places excoriated. The temperature in the axilla was 98·6°, that of the ward being 57°. The child was stated to be very easily chilled, so that it required to be very carefully protected against the cold. Its digestion was also very difficult, and great attention was needed in feeding it, and when the food did not agree, the breathing became difficult, and there was violent beating at the heart and increased lividity. On August 25th, 1876, the child was again seen by me at my own house. The eruption on the skin had subsided under the use of warm baths, but the cyanosis was very marked. There was a loud systolic murmur in the pulmonary artery, which was not

Digitized by Google

heard in the course of the aorta, nor at the apex. The temperature in the axilla was 97·2°, in the hand 99·6°, that of the room being 65°. After this time I did not see the child again till the commencement of its last illness in August of the present year (1880). In the interval it had passed favorably through measles and whooping-cough, and had had attacks of croup and of jaundice.

The last illness of the child commenced on August 8th with earache and restlessness, followed by loss of power in the right hand. In the afternoon of the 9th he had violent shaking of the right arm and hand, and the following morning of the right leg also, with twitching of the right side of the face, and the right arm and leg were powerless afterwards. On the evening of the 12th the temperature was 101°; on the 22nd he had a general convulsive fit, followed by partial stupor; on the 23rd he recovered consciousness and could speak, though he did not articulate distinctly; on the 24th he had a second attack of convulsions, after which he was entirely unconscious, and he gradually sank till he died, at 11 p.m. on the same day. He was six years and nine days old at the time of death. During the child's illness it was attended by Dr. Bateman and Dr. Glover, of Islington.

The *post-mortem* examination took place at the child's residence on the 27th, and was made by Mr. King, the senior clinical assistant at the Victoria Park Hospital, in the presence of Dr. Glover and myself. There was much difficulty in obtaining permission to examine the body, and the examination was restricted to the heart. The organ was of large size for the age of the subject: it weighed four ounces and three quarters avoirdupois. From the heat of the weather and the time which had elapsed since death, the organ was very flaccid. The aorta was situated further to the right than usual, and the ascending portion was of large size. The pulmonary artery, on the contrary, was very small, and its coats thin, like those of a vein. The orifice was very small, admitting only of the passage of a cylinder measuring seven Paris lines (15·75 mm.) in circumference. There was only one valve at the orifice, and that was much thickened. The ventricles, but especially the right, were large, and their walls thick. The septum of the ventricles was deficient at the upper part, so that the aorta communicated with both cavities. The right auricle was very much dilated. The foramen ovale was closed, but there were several large openings in the fold. The ductus arteriosus was impervious.

Digitized by Google

The malformation of the heart in which the pulmonary artery is constricted and the septum of the ventricles defective, so that the aorta communicates with both ventricles, of which this case affords an instance, was first described by Sandifort in 1777,[1] and a considerable number of cases of the kind have since been placed on record in this country, France, Germany, and the United States. Indeed, as stated by Dr. Farre in 1814, it is the most common kind of deviation from the natural conformation of the heart. I have myself described four cases, and in 1866 I had no difficulty in collecting reference to upwards of sixty published cases. When the child was first seen at St. Thomas's Hospital, from there being a loud murmur in the course of the pulmonary artery, it was thought most probable that it was a case of pulmonary stenosis, and, as in cases where the pulmonary artery or its orifice is much constricted there is generally imperfection in the septum of the ventricles, it was supposed that the case was one of the combined form of defect. During the last illness, however, the murmur at the heart did not exist, and no precise diagnosis could therefore be formed, though it was thought most probable that it would prove to be a case of pulmonary stenosis with an aperture in the intraventricular septum.

The duration of life in malformations of this description varies considerably, being mainly influenced by the degree of impediment to the circulation resulting from the cardiac defect.

In my own cases the patients survived to the ages of two years and five months, six years and a half, nine years, and nineteen years, death being in the last instance due to choleraic diarrhœa during the cholera epidemic in 1854. Of 45 published cases, 5 proved fatal under three years of age, 13 between three and seven, 12 between seven and twelve, 7 between twelve and eighteen; 2 lived to the age of twenty-one, 1 to twenty-two, 1 to twenty-three, 3 to twenty-five, and 1 to thirty-nine.

The death of the patients is, in the largest proportion of these cases, as in the present instance, caused by cerebral disease. Two of my previously published cases died in attacks of convulsions. It would have been interesting to have ascertained the precise seat and nature of the brain disease in the case, but permission was with difficulty obtained for the examination of the body, and examination of the heart only was allowed.

[1] 'Observationes Anatomico-pathologicæ,' Lugd. Bat., 1777.

Digitized by Google

Though during life the temperature, as in such cases generally, was below the average, it will be seen that it rose during the child's last illness to 101°. In a cyanotic child, whose case is reported in the 'Pathological Transactions,' the temperature rose during a fatal attack of measles to 104°.

Cases in which the patients survived to twenty years of age and upwards.

1. *Bertody* and *Dunglison*, quoted in "Dublin Journal," 1845, from 'Phil. Med. Ex.' In a cyanotic female, æt. 21. Pulmonary artery slightly contracted.

2. *Gintrac*, 'Sur la cyanose, obs.' 45, p. 164. In a cyanotic man of 21. Pulmonary artery very small, and its coats thin. The orifice without semilunar valves, but closed by a membrane divided into two portions.

3. *Leadam, Farre*, on 'Malformations of the Heart,' 1814, p. 37. In a cyanotic man 22 years of age, subject to difficulty of breathing on exertion. Pulmonary artery contracted to half its natural size, and semilunar valves covered with vegetations.

4. *Marshall*, 'Lond. Med. Gaz.,' vol. vi, 1830, p. 886. In a cyanotic man of 23. Pulmonary valves were shrivelled, and the artery above them very much contracted.

5. *Louis*, 'Arch. Gén. de Méd.,' 1838, obs. 9, p. 331. The pulmonary orifice as greatly contracted. In a female of 25.

6. *Dalrymple*, 'Path. Trans.,' 1846—47, 1847—48, p. 58. In a female of 25. Subject to derangement of the circulation. Pulmonary valves thickened.

7. *Tommasini*, quoted by *Bouillaud*, 'Maladies du Cœur.,' obs. 183, vol. ii, p. 674. In a female of 25, who was livid in the latter period of life. Foramen ovale enclosed and R. A. V. Ap. narrowed.

8. *Bouillaud*, 'Mém. de l'Academie de Méd.,' 1862—63, p. 777. In a female of 29, with great defect in the sep. vent. See also *Vulpian*, 'Bulletin de la Soc. Anat. de Paris,' 2ème serie, t. xiii, 1868, p. 79. In a cyanotic female of 52 *Behier*, 'Bulletin de la Soc. Anat. de Paris,' t. xiv, 1869, p. 171. Narrowing of pulmonary artery. In a cyanotic man of 24.

Nov. 16th, 1880.

---

2. *Atresia of the aortic aperture in an infant.*

By Samuel G. Shattock.

The aortic aperture, as viewed from the left ventricle, is completely closed by a smooth fibrous diaphragm, which presents a minute central pit.

Digitized by Google

On the opposite aspect the partition is trilocular, and evidently formed by the adherent aortic valves.

The coronary arteries arise as usual.

The ascending portion of the aortic arch is considerably diminished in calibre. The cavity of the left ventricle is unnaturally small, scarcely more than large enough to hold a full-sized pea; its wall is 1·5 centimètre in thickness.

The right side of the heart and pulmonary artery are disproportionately large. The ductus arteriosus shows no sign of closure. The foramen ovale is patent.

The child's mother states that she had rheumatic fever when three or four years of age,—has had no symptoms of rheumatism since. The child was the first, and preceded by no miscarriages. Cyanosis was observed when the child was nine days old; death occurred on the 25th day. There was no evidence of congenital syphilis.

Only three cases of aortic atresia are referred to by Dr. Peacock,[1] whilst over twenty are given of obliteration of the orifice or trunk of the pulmonary artery. One of the first kind is that reported by Mr. Canton, in the Society's 'Transactions,' 1848–49, 1849–50, vol. ii, p. 38.

The arteries of the head and upper limbs were doubtless filled through the pulmonary artery by the ductus arteriosus, as in the other cases recorded. *May 3rd*, 1881.

(From a patient under the care of Dr. Wilson Fox.)

---

3. *Malformation of the heart.*

By Norman Moore, M.D.

Heart of a patient of Dr. Andrew's, who died in St. Bartholomew's Hospital. She was cyanosed. A præsystolic thrill was felt, and a systolic and a præsystolic murmur were audible all over the chest wall. At the age of seven the patient had had measles, and dated her heart trouble from that time. She had had several attacks of rheumatic fever, and was aged seventeen at the time of death.

[1] 'On Malformations of the Human Heart.' Second Edition, p. 94.

Digitized by Google

The external peculiarities of the heart are:

1. The enormous dilatation of both auricles.
2. The enormous dilatation of the right ventricle.
3. The moderate dilatation of the left ventricle.
4. The bifid character of the apex, which is nearly as great as that of the dugong's heart.

The right auricle is dilated and hypertrophied, and the left auricle to a somewhat less degree. The foramen ovale is completely closed. The orifice of the coronary sinus (which is dilated) normal. The tricuspid valve consists of a single large cusp, with two musculi papillares and other cords arising from the septum ventriculorum. The septum auriculorum does not meet the septum ventriculorum, and there is a large opening below it, but above the flaps of the mitral and tricuspid valves, one part of each of which is attached to the septum ventriculorum, just below this opening.

Thus, the auricles are in communication with one another, and each auricle with both ventricles.

The valve of the coronary sinus is a very slightly raised crescentic fold.

On the auricular surface there is no thickening around the attachment of the tricuspid; for the rest, the endocardium of the right auricle above the valve is everywhere normal.

The upper edge of the abnormal opening is quite smooth and clean, and vertical on the right side, but on the left is a small shelving projection towards the left, and quite horizontal.

Both flaps of the mitral and the inner part of the tricuspid are attached to the lower edge of the opening. The mitral flaps are partly folded, thickened, and slightly roughened. There are no endocardial thickenings on the outer wall of either ventricle, but on the left side, below the abnormal opening, is a little shading-off opacity.

Both flaps of the mitral are more horizontal than in a normal heart, and, instead of being attached to the posterior edge of the septum ventriculorum, are attached to its middle point.

This form of malformation, in which, while the foramen ovale is closed, the base of the auricular septum is incomplete, is rare, two or three cases only being on record.

The puckering of the mitral and the growths upon it show that endocarditis had taken place in the malformed heart after birth.

It is worthy of remark that in this case, as in many of true mal-

Digitized by Google

formation, as distinguished from the results of early endocarditis, another congenital malformation was discovered, namely, an omphalo-mesaraic diverticulum from the ileum.

March 3rd, 1881.

---

4. *Malformation of the heart.*

By Nestor Tirard, M.B.

The specimen exhibited was obtained from a female child, aged five months, seen at the Evelina Hospital for Children. Its main peculiarity consisted in the number of abnormalities present. The foramen ovale was only partially closed (about two thirds) by a thin membrane with sharply defined margins. There were four pulmonary valves, and these were thickened and presented numerous recent small granulations. The tricuspid valves were similarly affected by recent endocarditis. The right ventricle was considerably dilated and hypertrophied, the wall being nearly the same thickness as that of the left ventricle. The pulmonary artery was much expanded up to its bifurcation. There were only two aortic valves, both coronary arteries starting from behind the anterior valve. There was also an opening in the septum between the ventricles, immediately below the aortic valves. The mitral valve was normal.

The *post mortem* having been somewhat hurriedly performed in a poor lodging, the aorta was cut across just before the union with the ductus arteriosus. A portion of the ductus attached to the pulmonary artery was patent.

The child was brought to the hospital with sickness and diarrhœa. There was then no cyanosis. It was only after a loud diffused systolic murmur had been heard that the mother stated that the child's chest "worked" when she cried. Before death, however, the breathing became more distressed and there was slight cyanosis.

May 17th, 1881.

Digitized by Google

5. *Two cases of extreme stenosis of the tricuspid orifice.*

By Bedford Fenwick, M.D.

The patient from whom this first specimen was obtained was an unmarried female, aged 29, a domestic servant. Her previous history is extremely interesting, and it appears to me important also. She enjoyed fairly good health till she was eighteen years of age. She then suffered from an attack of acute rheumatism, from which she seemed to recover perfectly, and then continued in her usual health for nearly four years. Then one day, while carrying a heavy child, she was suddenly seized with a pain in the left side and great dyspnœa. She came as an out-patient to the London Hospital, was "told only to rest, took some medicine, and gradually the pain disappeared." From that time, however, she suffered from some dyspnœa on exertion. Five years after this, in 1878, she was admitted into the hospital for jaundice, and it was then noticed that there was a præsystolic murmur localised at the apex, and a faint systolic "whiff" audible at the base.

During this year she suffered from a second attack of acute rheumatism. The following year, 1879, she was admitted with a third attack of that disease, and it was now noted that the præsystolic murmur at the apex was rough and loud, and that, moreover, there was a loud harsh systolic murmur at the base, other cardiac signs remaining much the same.

Finally, at the beginning of the next year, 1880, she was again admitted. It was now found that the above-mentioned physical signs still persisted, but that in addition the præsystolic murmur, instead of being as heretofore distinctly localised at the apex, which throughout showed its impulse one inch and a half below and external to the left nipple, was now audible also over a large area, and very distinctly at the margin of the ensiform cartilage. The area of cardiac dulness was laterally increased, extending to the right edge of the sternum, and pulsation was strong and diffused over the whole of this area. There was a well-marked thrill, sensible at the apex and in the fourth left interspace. The main clinical features were cyanosis, great dyspnœa, cough, distension of jugulars; pulse feeble and very slow (42), intermittent and irregular;

Digitized by Google

temperature subnormal; urine varying from 50 oz. to 20 oz. per diem.

The autopsy revealed capillary bronchitis of the lower lobe of the right *lung;* great increase in the size of the *heart*, the left ventricle and auricle and the right auricle being much dilated. The tricuspid, mitral, and aortic orifices all much thickened and contracted. The tricuspid orifice measured in circumference only two inches. The mitral orifice 1⅛ inch, and the aortic only 1¼ inch.

The *liver* large and "nutmeg." Spleen and kidneys much congested.

The second specimen was obtained from an unmarried female, aged 26, a domestic servant. Three years ago she suffered from a severe attack of acute rheumatism. Till then she had always enjoyed fairly good health, but from that time she suffered from dyspnœa, cough, and palpitation, and these symptoms gradually and steadily increased in severity. When admitted she was cyanosed, and there was great general œdema and ascites in addition to the above clinical features. Percussion of the chest revealed that the area of cardiac dulness was considerably increased and square-shaped, measuring 4 inches × 4 inches and extending to the right margin of the sternum; the point of impulse was just below the left nipple and on the nipple line. A well-marked præsystolic thrill was felt over the greater part of the cardiac area, and chiefly it was noted to the right of the nipple; a loud præsystolic bruit was heard, loudest to the right of the nipple, but audible also to the left, and it was remarked by Dr. Samuel Fenwick that the point of greatest intensity of sound shifted from side to side, never being equally loud over both sides of the heart at the same time. Occasionally there was a tumultuous cardiac action, and then pulsation was visible over the whole of the left chest. The radial pulse was small and quick (96) and fairly regular. The urine contained a little albumen and was very scanty, varying in quantity from 10 oz. to 18 oz. per diem. The temperature was normal. There was much distension of the jugular veins. The autopsy showed that the body was well nourished; much œdema and ascites.

The *peritoneum* much thickened. Bands of lymph extended in all directions, forming loculi, each of which was filled with fluid.

Lungs almost carnified by the pressure of pleuritic fluid.

Liver enlarged, "nutmeg." Capsule much thickened. Typical "heart" *spleen.*

Digitized by Google

Kidneys greatly congested.

Stomach and *intestines* chronically congested.

Heart, much enlarged, weighed (after being in spirit for some days) 17 oz. The auricles much dilated, especially the right. Ventricles dilated and hypertrophied. The aortic valves thickened. The mitral valve contracted to a narrow ovoid slit, $\frac{1}{3}$rd inch in length by about $\frac{1}{4}$ inch in breadth, and with greatly thickened edges. The tricuspid orifice greatly altered, the edges of its valves being so united that they were converted into a kind of curtain stretched between the right auricle and the right ventricle. In the centre of this curtain there was a small, almost circular, opening $\frac{3}{4}$ths inch in length, $\frac{1}{4}$ inch in breadth, and having a circumference of only $1\frac{1}{4}$ inch.

Valvular disease of the right side of the heart is so rarely found that many authorities disclaim all personal knowledge of it, and even express their disbelief in its acquired existence. Dr. Flint[1] terms tricuspid stenosis a "rare curiosity," and Niemeyer[2] remarks that it is "extraordinarily rare." Furthermore, two of the greatest living authorities on cardiac disease, Dr. Peacock in England and Prof. Rosenstein in Holland, consider that the disease is one of congenital origin. Dr. Peacock[3] refers at length to this in his classical lectures on valvular diseases, and in the 'Transactions' of this Society he says,[4] "It has been the subject of discussion whether these cases (tricuspid stenosis) should be regarded as the results of disease before or after birth. *I am inclined to believe the former to be the correct view.*" Prof. Rosenstein[5] remarks, "When it (tricuspid stenosis) does occur it dates from fœtal life.

Finding that facts do not support these dicta, I bring these facts forward. They consist in an abstract of 46 cases of the disease recorded in European and American literature since 1825. Of these, 3 occurred last year in the London Hospital, and, curiously enough, were all under the care of Dr. Samuel Fenwick. Seven cases have been recorded in the 'Transactions' of this Society, and 8 in that of the kindred society of Dublin.

[1] 'Diseases of the Heart,' p. 240.
[2] 'Practical Medicine,' vol. i, p. 860.
[3] 'Valvular Diseases of the Heart,' p. 24.
[4] 'Pathological Society's Transactions,' vol. v, p. 67.
[5] Von Ziemssen's 'Cyclopædia of Medicine,' vol. vi, p. 150.

Digitized by Google

Consequently I think we may consider that the disease is *not* so "extraordinarily rare."

I venture to believe the following facts show most conclusively that tricuspid stenosis is generally, if not always, a disease acquired in after life, and but very rarely, perhaps never, when found in adults, one of congenital or intra-uterine origin.

The cases are shown in the appended table, and I will briefly discuss their results in the order there followed.

1. *Sex.*—Out of the 46 cases *no less than* 41 *were females and only* 5 *were males.* I think it will be admitted that this is a most extraordinary fact. These cases are in no possible sense "selected." They have been collected from many sources, separately recorded by many observers, as the references column shows. They extend over a period of fifty-five years. They are all I could find. I venture to believe that this one fact, if it even stood alone and unsupported, is almost a death blow to the congenital theory. Will it be asserted that the female is more subject to cardiac changes than the male? Poetically it may be true, but medical facts do not support the doctrine. In the ten years from 1871 to 1880 there were 31 cases of all kinds of congenital malformation of the heart exhibited before this Society, and of these 17 belonged to males and only 14 to females. Nor is it true in adult life. Out of 157 cases of all kinds of heart disease treated in one year in the wards of the London Hospital 88 were males and only 69 were females, or almost exactly 4 men to every 3 women. Therefore, it seems to me that this one fact is an almost conclusive proof that tricuspid stenosis does *not* "date from fœtal life."

2. *Age.*—The youngest age at death for women was seventeen, for men twenty-one. The oldest age at death for women was fifty-eight, for men sixty-four. The average length of life in the female cases was thirty-one, in the male thirty-six years. Dr. Peacock has recorded a case in vol. v of these 'Transactions' which, be it noted, only lived seven months.

3. *Previous history.*—From birth this child suffered from lividity and dyspnœa, and became almost black, I believe, occasionally in attacks of hooping-cough.

Of these 46 cases in only 1 solitary instance is it noted (No. 18) that the patient was subject to "darkness of the surface" from an early age. In no other case was any lividity observed, or at least noted, and in most cases it is distinctly remarked that the patient's

Digitized by Google

previous health had been good. Surely it will not be asserted that tricuspid stenosis is conducive to health or long life, or even that it will not produce most marked results, or even that the stenosis can exist for long before these results become apparent. In this connection it is interesting to observe the march of the disease in the first case I have just recorded. First, she has good health till she suffers from an attack of acute rheumatism. After some years attention is directed to her heart, and, presumably, it is found only slightly diseased. Five years afterwards she is found to have mitral stenosis and commencing disease of the aortic orifice. This by the next year, and after another attack of acute rheumatism, is found to have progressed into a state of stenosis. Finally, in another year a fresh attack of acute rheumatism has exhibited fresh inflammatory power, and she is now found to have the tricuspid orifice stenosed also. Is there here a trace of a fact to support the theory of a congenital origin?

Finally, in 23 of these 46 cases there was a well-marked history of antecedent acute or subacute rheumatism. I venture to consider this fact a fresh link in the chain of my evidence, for out of a total of 304 cases of all kinds of heart disease (in none of which a congenital origin was expected), I find that in 152, or exactly one half, an antecedent history of rheumatism was noted. Do not these facts, one and all, point to the belief that the disease is acquired in after life?

4, *Size of tricuspid.*—Of these cases—

The orifice admitted three fingers in	1	case.
The orifice admitted two fingers in	8	cases.
The orifice admitted one finger in	20	„
The orifice admitted only the tip of one finger in	8	„
The size was not accurately stated in	9	„
	46	„

Twenty-eight cases, therefore, whose ages varied from twenty to sixty-four years, and in whom the stenosis may be fairly described as extreme, had lived most of these years in comparatively good health, certainly without exhibiting any one of those symptoms which characterised the case of Dr. Peacock's, to which I have before alluded, and which, cyanosed and in suffering, lived only seven months, and finally was actually found to possess a tricuspid

Digitized by Google

orifice absolutely larger than that found in any one of these 28 adults, its circumference being "24 lines."

5. *Size of the mitral orifice.*—In every case the mitral orifice was found to be greatly thickened and contracted, and in nearly every case this contraction was greater in degree than that of the tricuspid.

6. *Concurrent cardiac changes.*—In nearly every case the right auricle was dilated, and generally to an extreme degree. In 25 cases out of the 46 the aortic valves are noted as diseased, in 13 the valves being thickened and incompetent, and in 12 the orifice was stenosed.

Such are the facts I derive from these collated cases. They teach several new lessons. I only desire here to draw six conclusions.

1. Tricuspid stenosis is not "extraordinarily rare."

2. It is more common by far in women than in men, perhaps in the proportion of 7 or 8 to 1.

3. It is always associated with stenosis of the mitral orifice.

4. In about 25 per cent. of cases the aortic orifice is also stenosed.

5. In almost exactly 50 per cent. there is an antecedent history of acute or subacute rheumatism.

6. Tricuspid stenosis, when found in adults, is due to acquired disease, and very rarely, perhaps never, of congenital origin.

January 18*th*, 1881.

Digitized by Google

Tricuspid Stenosis.—Tabulated Summary of Cases

No.	Sex.	Age.	Rheumatic or other previous History.	Weight of Heart.	Size of the Tricuspid Orifice.	Size of the Mitral Orifice.	Concurrent Cardiac Changes.	References.
1	M.	37	Acute rheumatism at 15 years of age.	14 oz.	Barely admitting two small fingers.	Contracted to a like extent.	Aortic valves much thickened; ventricles much hypertrophied; auricles dilated and hypertrophied.	Dr. Quain, 'Pathological Society's Trans.,' vol. i, p. 219.
2	F.	42	No rheumatic history.	Not noted.	Admitting the middle finger.	Admitting only the point of the little finger.	Great dilatation of the right auricle, and dilatation with hypertrophy of the right ventricle.	Dr. Hope, 'Diseases of the Heart.'
3	F.	37	No rheumatic history.	Not noted.	Only admitted one finger.	Only admitted one finger.	Aortic valves disorganised and incompetent; dilatation and hypertrophy of all cavities, especially the right auricle.	Mr. Pollock, 'Pathological Society's Trans.,' vol. ii, p. 194.
4	F.	37	No rheumatic history.	9 oz.	$\frac{3}{4}$ths inch × $\frac{3}{4}$ths inch in diameter; 21 lines in circumference.	$\frac{3}{4}$ths inch × $\frac{1}{4}$ inch in diameter; less than 2 inches in circumference.	Right auricle aneurismal, measuring 3 inches by 2 inches; aortic orifice thickened and stenosed, measuring 3 inches in circumference.	Mr. Pye-Smith, ibid., vol. iii, p. 283.
5	F.	20	No rheumatic history.	25 oz.	7 × 6 lines in diameter.	5 × 5 lines in diameter.	Dilatation and hypertrophy of all cavities, especially the right auricle; aortic valves diseased.	Dr. Stokes, 'Dublin Pathological Society's Transactions,' 1862.
6	F.	23	Not noted.	Not noted.	Only admitting the point of the index-finger.	Contracted to an equal extent.	Right auricle much dilated and hypertrophied; aortic valves incompetent.	Dr. Little, ibid., 1867.

Digitized by Google

7	M.	37	Acute rheumatism 6 years previously.	Not noted.	Only admitting the forefinger beyond the first joint.	Admitted the tips of the two first fingers.	Right auricle greatly dilated.	Dr. Balthazar Foster, 'Clinical Medicine,' 1868.
8	F.	26	No rheumatic history.	19½ oz.	Only admitting the tips of two fingers.	Only admitting the point of the index-finger.	Right auricle "normal" in size; left auricle greatly dilated; aortic orifice much contracted.	Dr. Hayden, 'Dublin Pathological Society's Transactions,' 1869.
9	F.	26	Acute rheumatism 14 months previously.	10½ oz.	Only admitting the tip of the index-finger.	Only admitting the tip of the little finger.	Right auricle greatly dilated; left auricle also dilated.	Dr. Cryan, ibid., 1870.
10	F.	Young.	Not noted.	Not noted.	Only admitting one finger.	Only admitting the end of the little finger.	Not noted.	Dr. Flint, 'Diseases of the Heart.'
11	M.	23	Acute rheumatism at 9 and at 13 years of age.	17½ oz.	Only admitting the tip of the middle finger.	Only admitting the tip of the index-finger.	Both auricles much dilated.	Dr. Hayden, 'Dublin Pathological Society's Transactions,' 1871.
12	F.	27	Acute rheumatism 6 years previously.	11 oz.	Only admitting the index-finger.	Only admitting the point of the little finger.	Right auricle much dilated.	Dr. Cryan, ibid., 1872.
13	F.	25	No rheumatic history; measles badly at 16, never quite well afterwards.	11 oz.	Only admitting the point of the middle finger.	Only the point of the index-finger.	Both auricles, especially the right, much dilated.	Dr. Hayden, ibid., 1874.
14	F.	38	Three attacks of acute rheumatism.	Not noted.	Not admitting the points of two fingers.	Admitting only the forefinger.	Right auricle greatly dilated.	Dr. Haldane, 'Edinburgh Medical Journal, vol. x.
15	F.	30	Acute rheumatism at 12 and at 24 years of age.	Not noted.	Only admitting the point of the forefinger.	Only admitting the point of the little finger.	Right auricle excessively dilated; aortic orifice contracted as small as the mitral.	Dr. Haldane, ibid.

Digitized by Google

No.	Sex.	Age.	Rheumatic or other previous History.	Weight of Heart.	Size of the Tricuspid Orifice.	Size of the Mitral Orifice.	Concurrent Cardiac Changes.	References.
16	F.	33	With a history of rheumatism.	11½ oz.	Only allowing one finger to pass.	¼ inch long × ⅛th inch wide.	Right auricle much dilated.	Dr. Simpson, 'British Medical Journ., May, 1868.
17	F.	21	Acute rheumatism at 13 and at 19 years of age.	8½ oz.	Contracted to a narrow crescentic slit.	Contracted as the tricuspid, but to a greater degree.	Not noted.	Dr. Simpson, ibid.
18	F.	19	No rheumatic history.	Not noted.	Contracted, rigid, and in places ossified.	Sufficient to admit the tip of the little finger.	Not noted.	Mr. Burns, quoted by Dr. Peacock.
19	F.	32	Acute rheumatism at 19 and at 30 years of age.	Not noted.	Having a circumference of about 15 lines.	Similarly contracted.	Aortic valves thickened and incompetent.	Dr. Peacock, 'Valvular Diseases,' p. 28.
20	F.	18	Acute rheumatism 18 months previously.	13½ oz.	Much contracted.	Exceedingly contracted.	All the cavities dilated and hypertrophied.	Dr. Peacock, ibid.
21	F.	43	No rheumatic history.	13 oz.	Of a half-moon shape, nearly 1 inch in length, and ½ an inch in width.	About ⅔rds inch × ½ inch.	Right auricle somewhat, left auricle enormously dilated.	Dr. Greenfield, 'Pathological Soc. Trans.,' 1876.
22	F.	42	No rheumatic history.	Not noted.	Just admitting the little finger.	Not admitting the end of the little finger.	Right auricle considerably dilated and hypertrophied.	Mr. Pearce Gould, ibid., 1877.
23	F.	37	Acute rheumatism at 21 and at 26 years of age.	24 oz.	⅛ths inch in diameter.	⅜ths inch in diameter.	Right auricle considerably dilated.	Dr. Ewart, ibid., 1878.
24	F.	37	No rheumatic history.	Not noted.	Stenosed.	Stenosed.	Aortic orifice contracted and roughened; right auricle much dilated.	Dr. Pearson Irvine, ibid., 1880.

Digitized by Google

25	F.	17	Very hard life, no rheumatic history.	11 oz.	Admitted two fingers.	Scarcely admitted the point of the little finger.	Right cavities dilated; left cavities dilated and hypertrophied.	Dr. Goodhart, 'British Medical Journ.,' Sept. 23rd, 1871.
26	F.	33	Not noted.	Not noted.	About two fingers' size.	About that of two fingers.	Aortic valves thickened and opaque; both auricles exceedingly dilated.	'Pathological Catalogue R. C. S. Museum,' No. 1542.
27	F.	40	Not noted.	Not noted.	A small, contracted, circular aperture.	Semilunar fissure barely admitting the handle of a scalpel.	Aortic aperture barely admitted tip of index-finger; both auricles dilated; left ventricle hypertrophied.	Dr. Jennings, 'Dublin Pathological Society's Transactions,' 1866.
28	F.	22	No rheumatic history.	Not noted.	Considerably contracted.	Considerably contracted.	Aortic valves much thickened and contracted.	M. Luton, 'Bulletin d. l. Société Anatom.,' 1858.
29	M.	21	One attack of acute rheumatism.	Not noted.	Admitted two fingers.	Admitted two fingers.	All cavities, especially the right auricle, greatly dilated.	M. Duroziez, 'Gazette des Hôpitaux,' 1868, pp. 310—315.
30	F.	44	One attack of acute rheumatism.	Not noted.	Admitted two fingers.	Only admitted the end of the little finger.	Aortic orifice insufficient.	M. Duroziez, ibid.
31	F.	46	No rheumatic history.	Not noted.	Admitted two fingers.	Only admitted one finger.	Aortic orifice stenosed and incompetent.	M. Duroziez, ibid.
32	F.	37	No rheumatic history.	Not noted.	Admitted two fingers.	Only admitted the little finger.	Aortic slightly incompetent.	M. Duroziez, ibid.
33	F.	40	One attack of acute rheumatism.	Not noted.	Only admitted one finger.	Only allowed a large quill to pass.	Aortic orifice contracted and incompetent; left auricle dilated.	M. Duroziez, ibid.
34	F.	58	No rheumatic history.	Not noted.	Admitted one finger.	Admitted one finger.	Aortic valves incompetent.	M. Duroziez, ibid.
35	F.	27	Repeated rheumatic pains.	Not noted.	Only admitted the point of the index-finger.	Not quite so small as the tricuspid.	Not noted.	M. Duroziez, ibid.
36	F.	36	No rheumatic history.	Not noted.	Only admitting one finger.	Hardly admitting the end of the little finger.	Aortic orifice much contracted.	M. Duroziez, ibid.

Digitized by Google

No.	Sex.	Age.	Rheumatic or other previous History.	Weight of Heart.	Size of the Tricuspid Orifice.	Size of the Mitral Orifice.	Concurrent Cardiac Changes.	References.
37	M.	64	Repeat. rheumatic pains; never an acute attack.	Not noted.	Only admitted one finger.	Only admitted one finger.	Not noted.	M. Duroziez, ibid.
38	F.	29	No rheumatic history.	Not noted.	Admitted two fingers to the first joint.	Only admitted the end of the index-finger.	Right auricle greatly dilated.	M. Duroziez, ibid.
39	F.	36	Several attacks of acute rheumatism.	Not noted.	Only admitted one finger.	Only admitted a quill.	Not noted.	M. Duroziez, 'Gazette des Hôpitaux,' 1869, p. 423.
40	F.	30	No rheumatic history.	Not noted.	Very considerable contraction.	Very considerable contraction.	Stenosis of the aortic orifice; heart hypertrophied.	M. Duroziez, ibid.
41	F.	23	No rheumatic history.	Not noted.	Very pronounced contraction.	As the tricuspid.	Aortic orifice thickened and contracted.	M. Duroziez, ibid.
42	F.	21	Hist. of acute rheumatism.	Not noted.	Only admitted one finger.	Greatly contracted.	Aortic valves incompetent.	M. Duroziez, 'L'Union Médicale,' No. 4. 1878.
43	F.	24	Two attacks of acute rheumatism.	22 oz.	Only admitted three fingers.	Only admitted three fingers.	Aortic valves thickened and incompetent; right auricle enormously dilated, measuring 3½ inches × 4 inches.	'London Hospital Medical Register,' 1874. Females, No. 1184.
44	F.	48	Hist. of acute rheumatism.	Not noted.	Much contracted.	Much contracted.	Recent pericarditis; aortic valves thickened and incompetent.	'London Hospital Medical Register,' 1880. Females, No. 300.
45	F.	29	Acute rheumatism at 18, at 27, and at 28 yrs. of age.	Not noted.	Only admitted one finger; circumference 2 inches.	Only admitted tip of the index-finger; circumference 1⅝ths inch.	Dilatation of the right auricle; contraction of the aortic orifice, circumference only 1¼ inch.	Ibid. Females, No. 187.
46	F.	26	Acute rheumatism 3 years ago.	17 oz.	⅝ths inch in length; ¼ inch in breadth; 1¼ inch in circumference.	Greatly thickened edges; ½rd inch in length, about ¼ inch in breadth.	Thickening of aortic valves; dilatation and hypertrophy of all cavities, especially right auricle.	Ibid. Females, No. 398.

Digitized by Google

6. *Heart with calcareous plates.*

By R. W. Burnet, M.D.

The specimen was removed from the body of a woman, aged 34. When first seen, September, 1880, four months before her death, she complained of weakness, of swelling of the abdomen and legs, and of cough. On examination there was found ascites with some anasarca, and bronchitis with congestion at the bases of the lungs. The condition of the heart attracted special notice. On placing the hand over the præcordial region, a rasping sensation was felt, synchronous with the systole of the ventricles; the place of impulse was slightly lower and nearer the middle line than normal; the area of cardiac dulness was not increased. On auscultation, there was heard a click preceding and running into the first sound; it was most distinct at the sternum over the fourth costal cartilage. There was also a murmur with the first sound at the base. The pulse was regular but small and feeble. Three weeks later the heart's action became very irregular; the first sound was markedly reduplicated, and was followed by a murmur when the patient held her breath.

About three weeks before patient's death, an increase in the cardiac dulness was first noted, conical in shape, with the apex at the manubrium sterni; the heart's action was still more irregular, and towards the apex a distinct to-and-fro friction sound was heard. A few days before death it was noted that the pulse was 130, weak, frequent, and irregular. After this there was little change in the physical signs.

Post-mortem.—The lungs showed bronchitis with collapse at bases. Liver showed fibroid induration. There was chronic peritonitis.

Heart.—Acute and chronic pericarditis; fresh lymph, more especially over anterior part of right ventricle. Heart not enlarged. In and below the auriculo-ventricular sulcus, four separate calcareous plates, involving almost the entire circumference of the heart. The two largest lie posteriorly, and are from two to three square inches in surface, occupying the posterior surfaces of the right and left ventricles respectively. On the anterior surface of

Digitized by Google

the right ventricle, and in relation with the recently effused lymph, is a somewhat smaller plate, and on the anterior surface of the left ventricle, near the auriculo-ventricular ring, an irregular triangular nodule about a square inch in surface. All these plates project at points in the region of the ring into the cavity of the ventricle, and this is more especially so in the left ventricle, hampering the posterior flap of the mitral valve. The septum and apex are free. The aortic valve and the aortic flap of the mitral valve are absolutely free and healthy. These plates do not in the least come in relation with the normal fibro-cartilage lying behind the aortic orifice.

Judging by appearances, the aortic and mitral valves had been competent until within a short period of death. The right heart is considerably more involved than the left, and this would explain the lung mischief. *April* 18*th*, 1881.

---

7. *Rupture of the arch of the aorta from injury.*

By Jeremiah McCarthy.

A girl, aged 12, was admitted into the London Hospital in a state of collapse. It was said that a pony had knocked her down and trodden on her chest. No fracture or injury could be detected. She never rallied, and died fourteen hours after admission.

At the *post-mortem* examination it was found that there was no fracture, but that the posterior mediastinum was full of blood; a small aperture was discovered in the posterior aspect of the descending portion of the arch of the aorta. The middle and internal coats presented a sharply defined transverse opening, and the external coat was detached to a slight extent, and was perforated by a small irregular hole.

The head of the third left rib was unusually prominent, and the prominence became more marked on pressure upon the anterior extremity of the rib. It is probable that the anterior wall of the chest had been pressed back, and the aorta thus squeezed against this projection, and the rupture so produced. *Oct.* 12*th*, 1880.

Digitized by Google

Digitized by Google

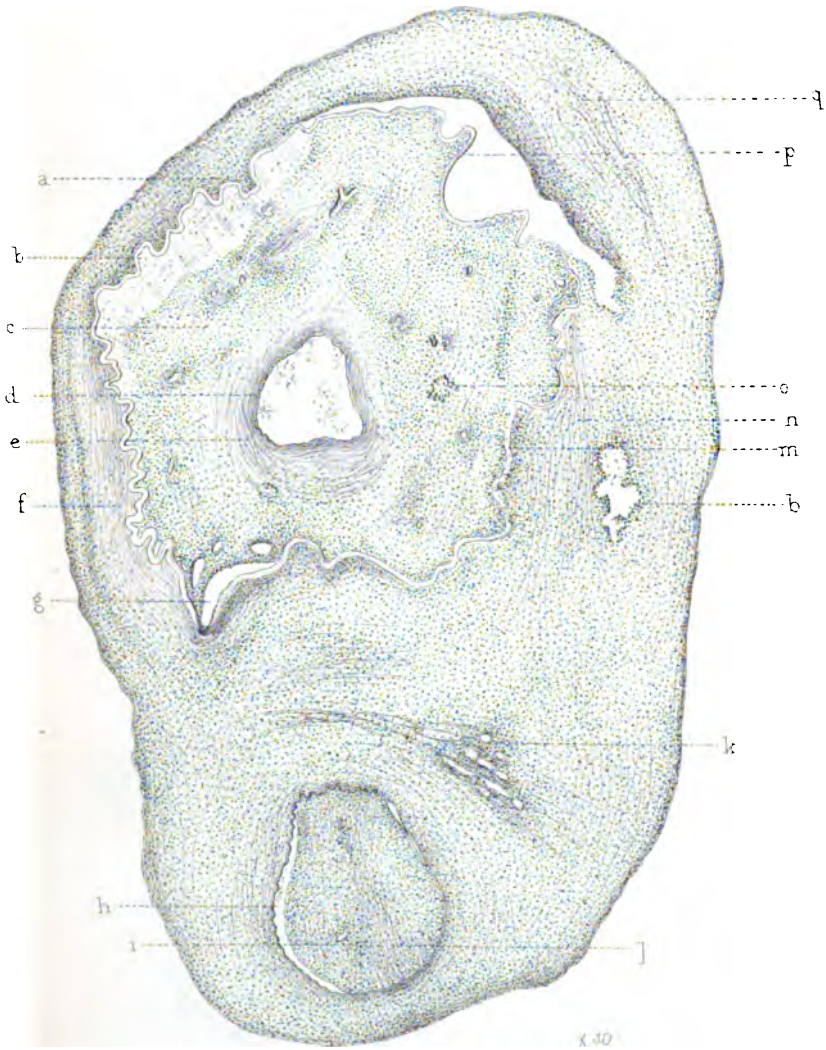

Digitized by Google

DESCRIPTION OF PLATE IV.

Illustrating Mr. Anderson's Case of Syphilitic Disease of Basilar Artery.

a. Degenerated adventitia and muscularis.

b. Membrana fenestrata, here obliquely cut.

c. External cellular portion of intima neoplasm.

d. New membrana fenestrata with endothelium.

e. Internal fibrous portion of intima neoplasm.

f. Remains of muscular tissue.

g. Fissure left by separation of neoplasm from membrana fenestrata, probably artificial.

h. Fissure containing blood-corpuscles.

i. Cell-growth filling canal of small artery.

j. Arrangement of spindle cells radiating from the point at which the new growth adheres most strongly to the wall of the vessel.

k. Thin-walled vessels of neoplasm.

l. Area of disintegration.

m. Membrana fenestrata here indistinct.

n. Group of spindle cells.

o. Pigmentary deposit.

p. Membrana fenestrata detached from diseased muscularis.

q. Bands of fibrous tissue.

Digitized by Google

Digitized by Google

Digitized by Google

Fig. 1

Fig. 2

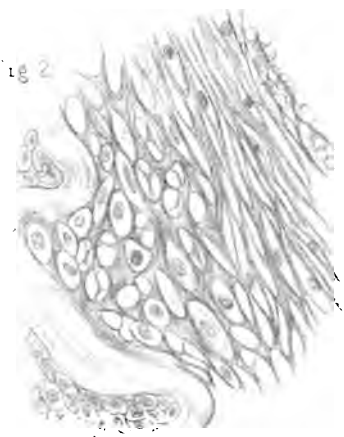

Fig. 3

Fig. 4

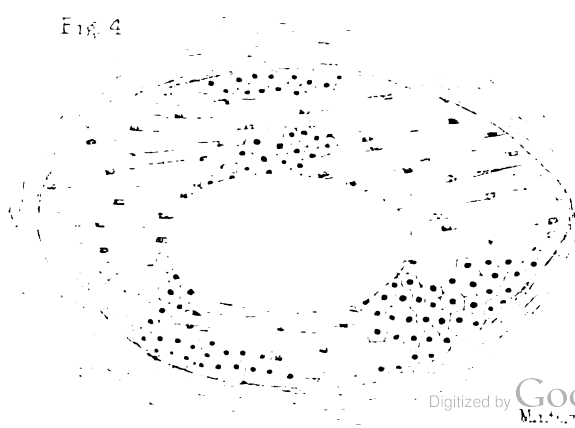

Digitized by Google

DESCRIPTION OF PLATE V.

Figs. 1 and 2 illustrate Mr. Anderson's Case of Syphilitic Disease of Cerebral Arteries.

Figs. 3 and 4 Mr. Mansell Moullin's Case of Cystic Tumour of the Breast.

*FIG. 1.—*a*. New cell growth in contact with membrana fenestrata, the sinuous band crossing the middle of the sketch.
b. Fibrillated bands enclosing flattened cells merging into *c*.
c. Fibrinous network separating linear groups of red corpuscles.
d, *e*. Red and white corpuscles of clot occupying lumen of vessel.
g, *h*. Cell growth occupying position of membrana media and adventitia.

FIG. 2.—*a*. Blood corpuscles of coagulum (on the right).
b. Fibrinous laminæ.
c. Intercellular meshwork continuous with fibrinous laminæ.
d. Cells occupying interspaces of network.
e. Membrana fenestrata.

In an adjacent portion of the wall of the vessel the corpuscles of the clot were separated from the membrana fenestrata only by a double or triple row of cells produced by proliferation of the endothelium.

FIGS. 3 and 4.—Sections through two small cysts showing character of basement membrane, the epithelial lining being in great measure detached.

---

* The letters to these figures have been accidentally omitted, but the context will make it clear what is meant.

Digitized by Google

Digitized by Google

8. *Syphilitic disease of the cerebral arteries.*

By W. Anderson.

[With Plates IV and V.]

The following case is, in most respects, a fairly typical example of syphilitic disease of the cerebral arteries, but it is distinguished by the development of certain clinical features hitherto unrecorded in connection with the lesion.

The patient, a naval instructor, contracted a hard chancre at the age of twenty-nine. He was treated in the usual manner, and after the subsidence of the early secondary symptoms he remained, to all appearance, in perfectly good health during four years. At the end of this time he began to complain of headache and impairment of memory. Any mental effort if prolonged beyond a few minutes induced a dull pain in one or other temple, with a distressing sense of mental confusion, but cessation of work always brought relief, and ordinary muscular exertion appeared to have a beneficial influence. His condition, after fluctuating slightly for about a year and a half, began to get worse, the headaches became more severe and prolonged, his manner became reserved and suspicious, and his intellectual powers showed signs of diminution. Various plans of treatment, including the use of specifics, were tried, but produced no decided results.

During the whole period there was a complete absence of other manifestations of disease.

Two years after the commencement of the headaches, and six years from the date of the chancre, he was suddenly attacked by partial paralysis of the muscles supplied by the lower branches of the left facial nerve. The seizure was associated with confusion of ideas, but there was no absolute loss of consciousness. His manner became surly and reticent, and it was noticed that the movements of the left upper and lower extremities were slightly impaired. He complained only of a deep dull pain in the right side of the head.

Six days after the facial paralysis he escaped the vigilance of his attendant and walked to his bath-room, where he was shortly afterwards found in a condition of partial insensibility, with almost complete hemiplegia on the left side, associated with rigidity of the para-

Digitized by Google

lysed limbs. A kind of automatic consciousness gradually deepened into coma, and for a time death seemed imminent from failure of respiration and circulation. He, however, rallied, and at the end of three days was out of immediate danger. His symptoms then improved rapidly; the mind became clear, the pain in the right side of the head gradually subsided, and the paralysed muscles lost their rigidity and began to regain their power.

On the fourteenth day after the hemiplegic attack he was able to make free use of his limbs, although the strength of the affected side was not fully restored, and he appeared mentally and physically convalescent. In the evening he fell into a sound and apparently healthy sleep. At 6 o'clock on the following morning he was found in a state of relapse—semi-unconscious, with renewed rigidity and paralysis of the left arm and leg. No improvement occurred during the day, and at 6 p.m. he had an involuntary action of the bowels. At 8.45 he was still able to answer simple questions if roused, but when left undisturbed he neither spoke nor took any notice of his surroundings. The pupils were dilated, deglutition difficult, respiration moaning and laboured. He complained of burning pain in the *right* arm, and slight clonic spasms were now noticed in the limbs of the previously unaffected side. The temperature in the axilla was 100·2° Fahr. About 10 p.m. he suddenly sprang up in the bed with a look of terror, and crying out "What—what's the matter?" fell into a state of violent tetanic opisthotonos. The jaws were tightly closed, respiration was suspended, and the face became livid and swollen. After a few moments a remission occurred, but some general tonic spasm persisted, and the respirations were stertorous. The superficial vessels of the head were intensely congested, and the skin was hot and perspiring. There was profound unconsciousness from the moment of onset of the tetanus.

In this condition, interrupted only by periodic paroxysms, he passed the night. The temperature continued to rise, reaching, at 2 a.m., 104·5° Fahr. (in the axilla), and at 4.30, 105·6°. At 6 a.m. the thermometer registered 108·4°: strength had then begun to fail, and a few minutes later a final convulsion set in, the face suddenly became ghastly, and the heart's action ceased. The temperature five minutes after death was 108·8°.

On the following day a *post-mortem* examination was made. The permission, however, limited the autopsy to the cranial cavity.

Digitized by Google

The body was well nourished and muscular, and presented no marks of disease. Rigor mortis strongly marked.

On removing the calvaria the aspect of the dura mater was normal. The vessels were moderately full.

The brain was firm, its surface normal in appearance, except over an irregular area of about a square inch, involving the posterior and internal part of the island of Reil and the adjacent portion of the temporo-sphenoidal lobe. This area was somewhat darker in colour than the rest of the surface, and was minutely pitted; it was soft to the touch and tended on gentle traction to separate from the tissues beneath as a kind of rotten pellicle of about a line in thickness. Cerebral nerves intact. No gummatous formations.

On section the cerebral substance generally presented nothing unusual. The vessels were nearly empty. Neither blood extravasations, local hyperæmia, nor inflammatory products were visible.

The intraventricular and subarachnoid fluid was normal in appearance and quantity.

The basilar artery for an extent of about seven lines showed a dense nodular thickening of its coats. Its narrowed canal was occupied by a recent coagulum.

The right internal carotid artery was obstructed by a partially decolorised clot at its bifurcation into anterior and middle cerebral; the coagulum extended into the latter vessel but not into the former. The coats of the middle cerebral artery were thickened, but less so than those of the basilar, and the lumen was obstructed by coagulum as far as the apex of the island of Reil, and for some distance along the posterior branch running between the central and temporo-sphenoidal lobes.

The left anterior cerebral artery contained a recent clot, but its walls appeared to be in a normal condition.

The other vessels presented nothing for notice.

The microscopical appearances of the diseased vessels were as follows:—Basilar artery: the whole of the coats were more or less affected. The tunica intima, the seat of the principal changes, was thickened to the extent of $\frac{1}{20}$th of an inch at the expense of the lumen, its external limit was marked by the membrana fenestrata, and on its inner aspect was developed a new and complete elastic lamina and endothelium. The tissue between the two fenestrated membranes had the usual characters of syphilitic new growths, its stroma formed a tough coarse network with meshes elongated in

Digitized by Google

the direction of the circumference of the vessel, and predominated largely in the inner third of the diseased coat; the cells were relatively abundant in the remaining two thirds, and were there chiefly of round or oval form and arranged in linear groups of three or four, while in the inner third they were comparatively scanty and of fusiform and angular outline. The neoplasm was richly supplied with capillaries and larger vessels; of the latter, two varieties could be distinguished, one in which the lumen was surrounded by a circular arrangement of fusiform cells in three or four layers, in the other the walls were represented only by a single layer of flattened cells. Many of the vessels of the first set were in course of obliteration by proliferation of the circumferential cells,[1] a process recalling the progressive narrowing of the Haversian canals in syphilitic ostitis, but in the arterial disease the vascular obstruction appears to be compensated for by the concurrent formation of new blood channels, and the nutrition of the tissue is preserved.

The old membrana fenestrata (which, according to the observations of Heubner, should be considered as part of the internal tunic) was thick and well-defined except at one point in its circumference, where it had almost disappeared. Its cohesion with the structures on its outer side was so slight that in all the preparations wide gaps of separation appeared; the detachment in most cases probably resulted from manipulation, but in some sections taken from a smaller specimen similar clefts were occupied by blood-corpuscles, and had been evidently channels of circulation during life.

The structures of the middle and outer tunics were for the most part replaced by new material, but in some situations a considerable thickness of muscular fibre persisted. The coats were irregularly thickened by a cell growth resembling that of the intima except in being very poor in vessels and in presenting areæ of disintegration. In one part of the adventitia the thickening depended principally upon an accumulation of bands of fibrous tissue.

Blended with the basilar artery was a diseased and obliterated vessel of a little less than half its diameter. The outer tunics of the two arteries had coalesced in the course of extension of the morbid growth, and a good deal of new tissue had been produced at the line of adhesion. The tissues of the adventitia and media of the smaller vessel were entirely replaced by new growth; the

[1] Dr. Greenfield has already called attention to this condition in other syphilitic growths ('Trans. Path. Soc.,' vol. xxviii).

Digitized by Google

membrana fenestrata was thinned and irregularly plicated, and in one place had disappeared, and internal to it was a vascularised cell growth which completely obliterated the canal. The elements of the latter tissue resembled those of the external portion of the intima growth in the basilar, but the proportion of fusiform cells was greater, and a peculiar arrangement of these, a radiation from the point at which the membrana fenestrata was least distinct, conveyed an impression that the growth was secondary to a thrombosis and corresponded to the ordinary intima proliferation occurring after ligature. In one situation the neoplasm was separated from the membrana fenestrata by a chink, into which blood had penetrated.

In the middle cerebral artery the pathological changes in the walls were principally localised in the outer and middle tunics and closely resembled those seen in the corresponding coats of the basilar artery; the alterations of the intima were for the most part only incipient, and it is difficult to say whether they were secondary to the thrombosis or had preceded it.

The arterial channel was occupied by a recent coagulum, the marginal parts of which were undergoing changes and merged without any line of demarcation into the structures of the proliferating intima. The central portion of the coagulum presented a simple tesselation of corpuscles, but near its periphery appeared a network of fibrinous material, which enclosed linear groups of the corpuscles in its elongated meshes; still more externally the fibrinous substance became increased and began to assume the aspect of fibrous tissue, the meshes at the same time became reduced to fusiform spaces, which were occupied by nucleated cells; finally, where the changes in the intima were most advanced the cells and intercellular substance gradually developed into a tissue resembling the syphilitic growth, but this metamorphosis was limited to about a fifth of the circumference of the walls, while in the remaining extent the intima was represented by a double or triple layer of rounded cells embedded in the vacuoles of a fibrillated intercellular substance. An apparent transition was noticed between the large round or oval cells in contact with the membrana fenestrata and the white corpuscles of the coagulum.

As in the case of the basilar artery, the middle cerebral was accompanied by a smaller obliterated vessel, the adventitia of which was blended with the outer coat of the main trunk.

Digitized by Google

Two distinct processes are probably represented by the vascular changes described; one, seen in the diseased basilar artery, of progressive concentric contraction of the lumen by a specific proliferation of the cells of the intima; the other, shown in the obliterated vessels attached to the two large arteries, of an irregular non-specific intima growth consecutive to a thrombosis of the canal. In the case of the middle cerebral artery it is difficult to say whether the cell growth from the intima preceded and caused the coagulation, or whether it was merely a secondary phenomenon, but the morbid appearances in the middle and outer coats seemed to be of much older date than those internal to the elastic lamina.

The condition of the basilar artery is identical with that described by Heubner ('Die luetische Erkrankung des Hirnarterien'), and affords a satisfactory explanation of the symptoms preceding the attack of facial paralysis. The pathological process, however, is not peculiar to syphilis, but may result also from other causes of vascular irritation; thus, a case of obliterative arteritis with precisely similar anatomical features is recorded by Dr. Winiwarter ('V. Langenbeck's Archives,' 1879), as a result of frost-bite, and Friedländer, in 1876 ('Centralblatt für Medic. Wissenschaften,' No. 4), describes a gradual narrowing and obliteration of arteries dependent upon common local irritation, such as that of tumour growth in the adjacent parts.

The appearances of obliterative arteritis may be closely simulated by processes consecutive to thrombosis. Dr. Fritz Raab ('Pitha-Billroth's Handbuch,' 1 Abth., S. 185) gives, in illustration of the development of the cicatrix in blood-vessels after ligature, some drawings which might be taken for satisfactory representations of the changes in the syphilitic disease; and Weber, in the same volume, relates two cases in which arteries obliterated by thrombosis were rendered pervious by the formation in the obstructing material of new vessels with distinct walls.

The formation of a new membrana fenestrata and endothelium, so well marked in the present case, is also represented in fig. 1 of Heubner's plates; and in one of the drawings illustrating Dr. Greenfield's paper in vol. xxviii of the 'Pathological Society's Transactions,' a thin elastic lamina is seen embedded in the midst of the neoplasm. The formation of this structure probably corresponds to periods of repair by which nature has endeavoured to restore the normal lining of the blood channel, but if the source of irritation remain,

Digitized by Google

the new endothelium behaves like the original intima and produces a renewed growth. In Heubner's figure commencing proliferation of the endothelium of the new intima is distinctly seen, and had this progressed further, the appearances would have become the same as in Dr. Greenfield's case.

The revelations of the *post-mortem* examination in the present case fully accounted for the symptoms up to a certain point. The headache excited only by mental effort coincided with the gradual narrowing of the calibre of the basilar artery, which prevented the free influx of blood demanded for active brain function. The impaired memory, &c., can be explained by the same cause. The final paralysis and subsequent well-marked hemiplegic attack are attributable to the plugging of the middle cerebral artery. It is, however, far more difficult to interpret the closing scene of *coma*, *tetanus*, and *hyperpyrexia*. The only explanation suggested by the autopsy was in the obstruction of the left anterior cerebral and of the narrowed basilar by new coagula, a condition which would obviously lead to great brain anæmia, with complex irregularities of the blood currents that were able to circulate. Dr. Heubner adopts a similar theory—narrowing or thrombosis of a great number of arteries—to account for the occurrence of general convulsions in three of the cases collected by him, but these attacks differed widely from the complication now referred to.

May 17th, 1881.

---

9. *Obstruction of the mesenteric artery and vein, followed by intestinal and peritoneal hæmorrhage, with rapidly fatal termination.*

By Frederick Taylor, M.D.

The history of this case is necessarily imperfect. The patient was never seen by a medical man, and for the short notes here given I am indebted to Dr. Sharpe, of Norwood, who was attending another child in the same house at the time, and had an account of the illness from the parents. A delicate child, five years old, was

Digitized by Google

suddenly seized one afternoon with "pain in the stomach" and vomiting, which continued for some hours, and the pain was very severe. It appears that the child presented some signs of illness on the morning of the day preceding, but to what extent and of what nature is not known. The sudden symptoms were attributed by the parents at the time to some strawberries which the child had eaten. There was some remission of the severe pain towards the evening, and the child slept a little on going to bed. The pains came on again violently during the night, when the child "screamed out, became delirious, and threw herself about." The pain continued all night with occasional violent paroxysms; towards morning she became faint and exhausted, and sank into a state of collapse, in which she died about 7 a.m.

I made the *post-mortem* examination fifty-eight hours after death. The weather was hot and stormy, and the body was moderately decomposed. There was green staining over the chest, back, and abdomen, and air in the subcutaneous tissue. The child was thin, but not emaciated. The abdomen was much distended. The peritoneum contained a quantity of dark fluid blood, which I estimated at from eight to ten fluid ounces. It was distributed all over, collecting only in the fossæ, and in no one more than another. The stomach contained a little air, and was pale in colour; on opening it there were some acid-smelling milky contents, similar to what had been seen oozing from the mouth. The mucous membrane was pale, not congested nor inflamed, nor ulcerated.

The small intestines formed a compact mass of dark blood-red colour, and the coils were uniformly but not excessively distended. This mass seemed to move about on the mesentery as on a sort of pedicle, and the pedicle seemed to have an edge towards the left side, so that it gave the impression that there was a twist in the mesentery, such as would convert a flat piece of cloth into a cord. On the right side was a band from the colon, near its hepatic flexure, passing obliquely downwards and inwards to the mesentery, and under this band, which was thin and filamentous, lay a portion of the small intestine, so that it would have been quite possible for a strangulation to have occurred at this spot. Indeed, above it the duodenum and eight or ten inches of jejunum were pale and healthy-looking; below it, began the deep red congested portion of the bowel, which continued to be of this deep colour till within three inches of the cæcum. I had already moved the mass of intestines

Digitized by Google

once or twice from side to side, but I do not think I had at all altered the relations of the parts before I carefully traced the bowel from end to end. They were then as follows:—From the termination of the duodenum the bowel was traced over the spine to the right side, where it passed under the band described, then to the left and upwards, and then gradually downwards, and so in a circular manner (like the hands of a clock) to the cæcum in its normal position. From this it would appear that the greater part of the intestine was in its normal position and relations, but that a loop, consisting of the first one and a half or two feet of jejunum, was turned over to the right side, and held there, though loosely, by the fibrous band. The corresponding mesentery was necessarily folded in front of the rest of the mesentery on a vertical hinge-line, forming the sharp edge already mentioned, and in the substance of the mesentery along this edge was felt a hard mass, elongated, and about the thickness of a small pencil. Further examination showed that this was intimately connected with the main trunk of the superior mesenteric artery, which, indeed, was completely obstructed at this point. On dissecting out these parts it appears that the mesenteric artery is perfectly normal for one inch, in which length it gives three lateral branches; it then becomes completely lost in an irregular shaped mass of tissue three quarters of an inch long, semi-cartilaginous above, and fibrous below. Other lateral branches come off from what remains of artery wall in this fibrous mass, but I have failed to find continuation of the artery or the branches immediately below. The superior mesenteric vein, however, I traced below right up to the seat of obstruction, where it also terminates abruptly by adhesion of its walls to a small thrombus. The mesenteric vein above is healthy, but I had destroyed its connection with the obstructing mass before tracing it out. The mesentery was much thickened, and contained numerous, rather large, fleshy glands. There was no caseous degeneration in these, but they presented on section a number of minute pin-point cavities, like the brain in the so-called *état criblé*. The intestines, on being slit open, were found to contain blood like that in the peritoneum, and the quantity within the bowel must have been equal to that outside. The mucous membrane was swollen, partly, perhaps, from decomposition. Peyer's patches were swollen here and there, and the solitary follicles were very prominent. A few strawberry seeds floated in the blood. The cæcum and colon were

Digitized by Google

pale, not congested like the jejunum and ileum, but I unfortunately omitted to open the large intestine to observe its contents. They were to all appearance healthy. The liver was pale; the spleen large and soft, with many Malpighian corpuscles. The kidneys were much decomposed but apparently healthy, and the heart, lungs, and larynx were normal. The brain and spinal cord were not examined.

The above is, no doubt, an unusual case. The symptoms were so acute that a suspicion of poisoning was entertained, but the conditions found *post mortem* were quite sufficient to explain the rapid death by natural means. The appearance of the small intestine at once suggested internal strangulation, and this appeared to be confirmed by finding a band lying across the jejunum just at the commencement of the reddened bowel. But the form of strangulation which it simulated was that in which a loop of bowel passes through an aperture or ring, and is constricted at two points in its length —internal hernia. This, however, was clearly not the case; the bowel was perfectly free at the lower end of the congested portion, and the band at the upper part lay quite loosely over it.

There can be no doubt, I think, that the condition of the bowel and the hæmorrhage were related to the obstruction in the mesenteric vessels. I at first attributed the symptoms to the closure of the artery, considering the known effects of arterial embolism in the production of hæmorrhage, and the fact that the length of intestine from which bleeding took place, internally and externally, corresponded with the branches of the superior mesenteric artery which were cut off by the obstruction. The upper branches, which were free, supply the duodenum, the first part of the jejunum, and the large intestine, and these were quite healthy. In reference to the part taken by the vein in causing the hæmorrhage, it should be mentioned that a case was shown before this Society by Dr. Fagge, and published in vol. xxvii of the 'Transactions,' which in many points resembles mine. The patient was seized with violent abdominal pain and vomiting, followed by collapse and death in twelve hours. At the post mortem, nearly half of the small intestine was intensely congested (resembling, as in my case, the results of internal strangulation), and the portal and superior mesenteric veins were filled with thrombus.

It is possible, therefore, in my case, that the venous obstruction was a sufficient cause, and it has been objected to my first reading

Digitized by Google

of the case, that the anastomoses of the branches of the superior mesenteric artery are sufficiently numerous and free to obviate the consequences of obstruction of its trunk. The curious displacement of the upper loop of the jejunum, and the band of adhesion by which it was confined, must have been the result of former inflammation. The mass involving the vessels may have developed at the same time, or may have been more intimately related to the numerous enlarged glands in the mesentery.

January 4th, 1881.

---

10. *Aneurysm of the anterior communicating artery of the circle of Willis.*

By W. M. Ord, M.D.

L. H—, aged 50; female; married; admitted to St. Thomas's Hospital, 20th February, 1881. A widow, mother of a large family. On her road to church that morning she had fallen suddenly on her face, and was at once seized with convulsions, which lasted, as far as can be ascertained, about a quarter of an hour.

When examined by a medical man she was unconscious and was breathing stertorously. She was then taken to the hospital, a distance of five miles.

When admitted, she was still breathing stertorously, and was totally unconscious; the pupils were contracted and insensible to light; the limbs were flaccid; sphincters paralysed. The temperature was normal. She remained in much the same state till the next day, when the breathing became quickened, the face became darkly flushed, and the temperature rose to 102° F. During the morning convulsions recurred affecting both sides of the body. The temperature rose to 103° F. subsequently, and the coma deepening, she died about 4 o'clock in the afternoon.

At the *post-mortem* examination, made the next day, a large effusion of blood was found on the surface of the brain beneath the arachnoid, more especially on the anterior lobes, also on the surface of the corpus callosum. At the base of the brain a large

Digitized by Google

quantity of clot was found in the meshes of the sub-arachnoid tissue in the interpeduncular space. The arteries of the circle of Willis and the basilar artery were much degenerated, and presented rings of calcareous matter in their walls. The source of hæmorrhage was found to be an aneurysm of the size of a large pea, in the situation of, and to all appearance arising in, the anterior communicating artery. There was no blood in the ventricles; a small quantity of clot was found between the folds of the velum interpositum.

On subsequent dissection two other aneurysms were found; one, in the right middle cerebral artery, about an inch from its commencement, another, much smaller, on the right anterior cerebral artery. The blood effused through the rupture of the first-mentioned aneurysm had evidently gradually found its way over the surface of the brain; first from below upwards, then from before backwards, and had extended deeply between the convolutions of the anterior part of the brain.

In the heart, the left ventricle was much hypertrophied, the valves were normal, the aorta was atheromatous; the kidneys were small, and in a state of fairly advanced granular contraction; they presented no deposits of urate of soda. There was no gouty deposit in the toe-joints. *May 3rd*, 1881.

---

11. *Aneurysm of the left posterior communicating artery.*

By Samuel West, M.B.

The patient was a woman, aged 40, who was brought into the Royal Free Hospital in a state of unconsciousness, from which she never rallied. The case presented the ordinary features of apoplexy, and the woman died in about half an hour after admission. She had been observed to become giddy in the street, to totter with difficulty to a doorstep, upon which she sat down, and then to fall over. When picked up she was found to be insensible.

Her friends stated that for some few months she had complained of occasional headache and giddiness, though the attacks were only of short duration.

Digitized by Google

On opening the head the brain was found covered with blood lying in the meshes of the pia mater. The effusion was most marked at the base, but had spread thence in all directions, upwards over the convolutions, and forwards, but chiefly backwards, covering the whole cerebellum and medulla and filling the fourth ventricle. The iter a tertio ad quartum ventriculum was of the usual size and empty of blood. Dissection disclosed a small sacculated aneurysm about half an inch long and a quarter of an inch wide, attached by a narrow pedicle to the outer side of the left posterior communicating artery. The walls were remarkably thin, in no part atheromatous, and the rupture was of considerable relative size. Elsewhere the vessels were healthy. There was no morbus cordis, no history of syphilis, and no trace of disease in the other organs.

May 17th, 1881.

---

12. *Aneurysm of the pulmonary artery.*

By Samuel West, M.B.

Case 1.—The patient, a man of 45, though a heavy drinker, had been in good health until, on one day (about two weeks before admission), after running quickly for some distance, he was seized with hæmoptysis, and since then any exertion had brought on a fresh attack. He was admitted into the Royal Free Hospital, where he had several attacks of obstinate hæmoptysis, accompanied on each occasion by a rise in temperature. Remedies failed to check the hæmorrhage, and the patient died of exhaustion.

On *post-mortem* examination the right lung was found slightly emphysematous, with a little peribronchial thickening, but otherwise healthy. The left lung was in a similar condition, except in the upper part of the lower lobe. This felt firm and hard, and on section two cavities were found with firm pigmented fibrous walls, large enough to hold about three drachms of fluid. The one contained some blood-stained fluid, the other some recently coagulated blood, but was almost completely filled by a firm solid mass, which

Digitized by Google

proved, on dissection, to be a laminated clot, decolorised, and of old date, in the centre of which was an aneurysm of the size of a small cherry, from which a probe passed, at a distance of only half an inch, directly into one of the main trunks of the pulmonary artery.

The kidneys and liver were a little firm on section, but the other organs were quite healthy.

CASE 2.—This patient, a man aged 27, was admitted for phthisis into the Chest Hospital, Victoria Park, with the history that he had been in good health until three months before, when he began to be troubled by cough, and to lose flesh and strength. Four years before he had suffered from an attack of hæmoptysis, which had invalided him for six weeks. He had also had a slight return of hæmoptysis three weeks before his admission. After being in the hospital for ten days the patient died suddenly of profuse hæmoptysis.

At the *post-mortem* examination the right lung was emphysematous (? hypertrophied), and reached an inch and a half to the left of the mid-sternal line opposite the third rib. The left lung was greatly contracted, the upper lobe being converted into one large cavity with thick trabeculated walls, the pleura being much thickened over it. In the lower lobe were several smaller, but in other respects similar, cavities, the lesion between containing air. In one of these in the apex of the lower lobe, about half an inch in diameter, was an aneurysm completely filling the cavity, in the middle of which was a ragged aperture the seat of rupture.

The other organs were healthy.

These two cases illustrate what is, I believe, the rule in cases of pulmonary aneurysms, that the lung changes which precede, and no doubt cause, the vascular change, are insidious, chronic, local, and usually unilateral. *May 17th*, 1881.

Digitized by Google

13. *Aneurysm of middle cerebral artery in a boy of twelve, rupturing into the descending cornu of the lateral ventricle.*

By Samuel West, M.B.

The patient, a boy of 12 years of age, was admitted into the Chest Hospital, Victoria Park, with disease of the heart (mitral incompetence). At eight years of age he had had scarlet fever and dropsy, and afterwards some joint pains, which may have been rheumatic. For two years he had been troubled with dyspnœa. Four days after admission he was suddenly seized with headache and vomiting. Shortly afterwards became drowsy and had several fits, though none of them were severe. No paralysis was detected, but the drowsiness gradually deepened into coma, and the boy died about twenty-four hours after the commencement of the head symptoms.

On the *post-mortem* examination all the loose tissue at the base of the brain was found distended with blood, which tracked in all directions upwards towards the surface of the brain, and downwards along the medulla and cord, and on both surfaces of the cerebellum. All the ventricles (the fourth inclusive) were filled with recent blood-clot. The source of the hæmorrhage was an aneurysm of the left middle cerebral, of the size of a small pea, about one inch from its origin. The walls of the vessel here were very atheromatous and brittle, although elsewhere they were perfectly healthy. The aneurysm had contracted dense adhesions all round, and had ruptured into the tip of the descending cornu of the left lateral ventricle. The blood had filled both the lateral ventricles, and had then spread by the transverse fissure to the exterior of the brain, chiefly along the base, around the crura cerebri, over the cerebellum, and round the crura cerebelli to the fourth ventricle. The iter a tertio ad quartum ventriculum was of the usual size and empty of blood. There was no evidence of embolism in the diseased artery.

The pericardium was universally adherent, and the mitral valve much thickened and covered with numerous recent vegetations.

The other organs were healthy. *May 17th*, 1881.

Digitized by Google

14. *Thrombosis of innominate vein contiguous with a pulmonary cavity.*

By W. Wilberforce Smith, M.D.

Mrs. A—, aged 42 at time of death; had been in poor health for ten years, since her sixth confinement; had lost flesh, and suffered from frequent coughs.

In March, 1880, eight months before death, she had a transient attack of dropsy, which is said to have commenced in one arm, not on the same side as the vein occluded at the time of death, but on the left side, and afterwards to have shifted to the legs. From this she recovered in a few weeks under the use of digitalis.

Her fatal illness commenced four weeks before death, during which I had several opportunities of examining her. There was œdema of the right arm, and this was so abruptly circumscribed about two inches below the shoulder as at first sight to suggest the idea of some pressure fraudulently produced. But there were also signs of œdema all over the right lung. The right external jugular vein was distended; the right hand, also the face and neck, were livid; the lips purple. The supra-clavicular region on the affected side was depressed and deficient in resonance. In the infra-clavicular region there was diminished resonance, most distinct at the outer and inner portions of the first intercostal space, corresponding, as it turned out *post mortem*, to the course of the great veins in that situation.

The urine was slightly albuminous, sp. gr. 1017.

The only lesion capable of accounting for the signs observed seemed to be some obstruction of the innominate vein. This, however, did not appear to explain the œdema of the lung, and on looking up the anatomy of the venous supply I could only conclude that the obstruction, whatever its nature, extended low enough to obstruct the vena azygos at its discharge into the vena cava. A diagnosis was made accordingly.

Her state remained little altered until the day of her death, when she became exhausted after being moved for the arrangement of her bed, and died a few hours later.

The *autopsy* was performed under the valuable superintendence of Dr. Coupland.

Digitized by Google

The face and lips remained livid, the subcutaneous tissue and organs generally were overcharged with dark blood. The anasarca, persisting after death, affected especially the right arm and right side of thorax; the front of the chest pitted on pressure on the right side, but not on the left. The right pleural cavity contained several pints of translucent fluid recently effused, and there was slight ascites.

The right vena innominata, as seen in the specimen, was occluded by a firmly adherent and partly organised clot. It extended downwards for a short distance into the superior vena cava, and outwards into the commencement of the subclavian vein. The walls of the first part of the subclavian were thickened, and the calibre of the vessel much narrowed at its junction with the jugular. Beyond this firm adherent clot a recent dark-coloured clot extended along the course of the jugular and subclavian veins.

The tissues generally round the seat of obstruction were thickened, so that much difficulty was experienced in dissecting them out, and the contiguous pleura was extremely thick and firmly adherent to the apex of the lung. This part of the lung had been converted into a cavity of old date the size of two walnuts. Except this cavity the lungs were free from signs of phthisical disease. This lung was emphysematous and greatly engorged, its lower lobe collapsed from compression by the fluid effusion. The opposite lung was also everywhere emphysematous.

The heart was dilated and enlarged; the right side was filled with dark blood, and contained, amongst the columnæ carneæ, two or three smooth old clots the size of orange pips. The mitral valve was thickened.

The liver was coarsely granular on the surface, engorged with blood and cirrhotic.

The kidneys were engorged, toughened, moderately granular, but of full size; their capsules adherent.

Remarks.—The course of events in this case is perhaps fairly comprehensible. First, respiratory affections extending over ten years giving rise to emphysema of the lungs and dilatation of the heart; in the right lung to a cavity at the apex. Associated with this cavity there was an unusual degree of thickening of the pleura, and Dr. Coupland suggested that the inflammatory process extending by contiguity had led to the thickening of the walls of the subclavian vein in its first part.

The thrombosis, which proved fatal, would be favoured, firstly, by

Digitized by Google

this state of the vein, and secondly, by dilatation of the heart impeding the venous current.

In any case, the occurrence of thrombosis with occlusion of the innominate vein in contiguity with an apical cavity is, so far as I can learn, of such rarity as to be worth recording.

January 18*th*, 1881.

---

15. *Blood from a patient who died of diabetes.*

By Norman Moore, M.D.

The specimen shows a layer of fat on the surface of the clot. The blood from the heart, brain, and all parts of the body as it flowed out was of the colour of raspberry juice. It was nowhere firmly clotted.

When the serum had separated on the *post-mortem* table it was of a white colour and looked like a thin layer of skimmed milk.

The pink colour suggested a possible change in the oxyhæmoglobin, so I made a spectroscopic examination of the blood and compared its spectrum with that of specimen of normal oxyhæmoglobin which Dr. Russell had prepared. The two dark lines of the normal oxyhæmoglobin were precisely continuous with those in the spectrum of the abnormal blood.

Under the microscope the blood showed a normal number of red corpuscles, a good many white corpuscles, and a large quantity of fat granules.

When a specimen of the blood was allowed to stand in a test tube for some hours a thick layer of fat was to be seen on the surface.

The patient was a man, aged 18 years, under the care of Dr. Church, in St. Bartholomew's Hospital. He was obliged to give up work from weakness last January, and had then had diabetes for some time. He was very feeble when admitted into St. Bartholomew's, and lived three weeks. He passed about five and a half pints of urine daily, and its usual specific gravity was 1040.

For some hours before death he passed no urine at all, and was

Digitized by Google

insensible. He had gradually passed into this state after some mental distress. He had no true acetonæmia. *Post-mortem* there was about half a pint of urine in his bladder.

Sanders and Hamilton, 'Edinburgh Medical Journal,' July, 1879 (as quoted by Gamgee), p. 170, "Physiological Chemistry," have described pink blood and creamy serum in some cases of diabetes.

Dr. Gamgee himself describes the blood from two cases of diabetic coma, and mentions the milky serum, but does not describe the peculiar raspberry-juice tint observable in the blood of which I show a specimen.

Dr. Klein informs me that some fifty guinea-pigs of his died one day of an epidemic disorder, the nature of which he was not able to determine, and that their blood presented exactly the appearance I have described.

My case shows that this blood change is not restricted to cases of diabetes in which acetonæmia occurs.

November 2nd, 1880.

---

16. *Congenital imperfection of septum ventriculorum, with ante-mortem thrombosis of right ventricle and pulmonary artery.* (*Card specimen.*)

Exhibited by JOHN ABERCROMBIE, M.D.

THIS specimen was taken from the body of a child, aged 3½ years, who died at the Hospital for Sick Children, Great Ormond Street.

The right ventricle contains a moderately firm, decolorised clot, about the size of a small walnut, which is continued into the pulmonary artery. The cavity of the right ventricle seems to consist of two tolerably distinct portions, the lower part is the cavity of the ventricle proper, the upper part is the conus arteriosus, which is distinctly constricted where it joins the ventricle, and at this point there is found a semicircular fibrous band, to which numerous minute calcareous vegetations are attached, and to these the clot is firmly adherent.

The conus arteriosus is a little dilated; the clot is not adherent to its walls, except at the points above indicated.

At the upper part of the septum ventriculorum there is a communication between the ventricles the size of a threepenny piece.

The pulmonary orifice is narrowed. There are three sigmoid

Digitized by Google

cusps; the posterior of these is roughened on its ventricular aspect, and here the clot is very adherent. The clot is firmly adherent to the walls of the pulmonary artery, and almost occludes both its branches; it is prolonged into both lungs.

Mitral orifice natural. Left auricle natural.

The aorta is dilated and arises from both ventricles, its valves are a little thickened, and it shows some atheroma.

Ductus arteriosus obliterated.

Heart weighed 5½ oz.

Upper lobe of left lung much collapsed, lower lobe contains two large infarcts.

Submucous hæmorrhages in alimentary canal.

Other viscera natural.

The child was admitted with marked cyanosis and dyspnœa. A loud systolic murmur was heard midway between the lower end of the sternum and nipple, inaudible behind. Six weeks before death he had scarlatina of a severe type. During the last week of life there was high fever, with great dyspnœa. His breathing was more laboured, and the cyanosis much increased during the twelve hours immediately preceding his death.

February 1*st*, 1881.

17. *Stenosis of tricuspid and mitral valves, with contraction of the aortic semilunar valves, in a boy fourteen years of age.* (*Card specimen.*)

Exhibited by A. Boyce Barrow.

He had rheumatic fever two years ago, with which he was laid up for twelve months. Six months ago he had a second attack, and has been an invalid since.

He was admitted into King's College Hospital, under the care of Dr. Duffin, January 6th, 1881, complaining of pain in the chest, cough, and shortness of breath. On physical examination of the heart the following signs were noted:—Heart's action very rapid, impulse strong, and a presystolic thrill can be felt; area of cardiac dulness increased to the right of the sternum; a presystolic and systolic bruit can be heard at the apex and in the axilla; no bruit at the base at this time. Pulse very small and soft. Subsequently (end of February) a double bruit was heard at the base. The symptoms increased and he died April 1st.

Post-mortem examination.—General anasarca. Face cyanotic, and superficial veins of body generally distended.

All internal organs congested.

Heart increased in size, weighs 13 oz. Both ventricles take part

Digitized by Google

in forming the apex. All its cavities are distended with blood, for the most part clotted and decolorised, those of the right side more than the left.

Right ventricle much dilated; the tricuspid valves are perfectly united together, thickened, and contracted, leaving a circular orifice admitting only the little finger. A few vegetations are seen on its auricular aspect.

Left ventricle somewhat dilated and hypertrophied; mitral curtains completely united together, leaving a button-hole orifice which admits the handle of a scalpel. On its auricular aspect calcareous plates are seen to lie in the substance of the curtain, and vegetations cover the margin.

The aortic valves are short, thick, and covered by recent vegetations.

Auricles are both hypertrophied and dilated. Hypertrophy of the left is very marked.

May 3rd, 1881.

18. *A case of mitral and tricuspid stenosis, with concurrent disease of the aortic valves.* (*Card specimen.*)

Exhibited by ROBERT E. CARRINGTON, M.D.

THE organ weighed 24 oz. It nevertheless retained its normal form. The pericardium was adherent by fine filmy lymph. The membrane stripped off readily, leaving a non-glistening surface, with here and there flakes of lymph.

The muscular fibres of both right and left ventricles exhibited a marked degree of the so-called "tabby cat" striation. This was most obvious in the muscular papillares of the mitral valves, but by no means confined to them, the walls being also affected. The streaked appearance was also presented in patches on the outer surface of the left ventricle. Section of the wall at these points showed that the degeneration reached right through. It was, however, most extensive on the inner surface, whilst at the centre there was a minor degree of it, and on the outer surface the amount of disease increased again. Although it was probable that the degeneration had passed from within outwards, yet this point was doubtful, and the more extensive amount at the outer surface than at the central part of the wall might perhaps be attributed to the inflamed pericardium.

All the cavities of the organ were greatly hypertrophied and dilated. The endocardium of the left auricle was especially thickened and opaque, whilst in the left ventricle, below the left anterior and the posterior aortic cusps, were also two white thick patches, probably indicating regurgitation. The aortic valves, tested

Digitized by Google

by a stream of water, held it remarkably well. It was extremely doubtful whether the disease was primary in the aortic or mitral valves, or whether it was concurrent in both. In each case it was very old. The cusps of the latter were extensively thickened, puckered, and calcareous, the chordæ tendineæ were matted together and thick, and the tips of the musculi papillares fibrous. The orifice was much contracted, and would just admit two fingers. Looked at from above it was remarkably "button-holed," whilst from below it was funnel-shaped. The cusps of the aortic valve were, as to the characters of the disease, in the same condition as the mitral. No recent vegetations were present on either. There was further a considerable amount of tricuspid stenosis; the valve would just admit three fingers. The cusps were thickened and puckered to a considerable degree, but the disease here was evidently more recent, and there was no calcareous change. The aorta was quite healthy and perfectly elastic. *May 17th*, 1881.

19. *Tricuspid and mitral stenosis.* (*Card specimen.*)

Exhibited by P. Horrocks, M.D.

The specimen was removed from the body of a young woman, aged 23. She gave the following history:

Rheumatic fever in 1866. Scarlet fever in 1869. Rheumatic fever (second attack) in 1870, on which occasion she was examined, and the report states that she had a thrill, and presystolic and systolic bruits at apex. Never well since first attack of rheumatic fever. Œdema of legs came on last few months and she died on the 26th February, 1881. Jaundice came on a few days before death. Dr. Hilton Fagge, under whose care she was at Guy's, was unable to make out any tricuspid presystolic bruit.

Post mortem.—Heart 12½ oz. and adherent pericardium. Left auricle enormously dilated and very thin. Mitral, button-hole, admitting only little finger. Tricuspid, button hole, admitting tips of two fingers. Both these valves much thickened, fibrous patches being seen also in musculi papillares. No recent vegetations. Aortic valves healthy. Nutmeg liver. Hard spleen. Kidneys a little swollen. Lungs congested, otherwise healthy.

March 3rd, 1881.

Digitized by Google

20. *Mucous tumour of heart (syphilitic gumma ?). (Card specimen.)*

Exhibited by S. G. SHATTOCK.

THE heart of an infant in connection with the right ventricle of which there has been formed a small circumscribed, slightly nodular and granulated ovoidal tumour, about a centimètre in its chief diameter, which slightly overhangs its base and projects into the ventricle from the anterior wall immediately below the corresponding cusp of the pulmonary valve, the inferior side of which it also involves.

Histology.—A net-work of delicate connective tissue in the meshes of which lie large many-branching granular nucleated cells, of which the processes form a secondary closer reticulum.[1]

The other organs were healthy.

From a child congenitally syphilitic.

January 4th, 1880.

21. *Aneurysmal dilatation and rupture of aortic valve. (Card specimen.)*

Exhibited by SAMUEL WEST, M.B. (for LAWRENCE HUMPHRY, M.D.).

SEMILUNAR valves, only two in number. The adjacent ends of the original anterior and left posterior valves have apparently broken away their attachment to aorta. The large valve thus formed is atheromatous and sacculated, and is protruded towards the ventricle. This saccule has burst and is perforated in several places. Opposite the centre of the valve on the wall of the aorta is a whitish seam, probably indicating the line along which the edges of the valves were formerly attached. The orifices of the two coronary arteries both open behind the same valve. The other valve is of large size and thickened. A few patches of atheroma on the aorta above the valves. *March 15th*, 1881.

[1] The appearances are as well or better explained on the supposition that the substance around the nuclei is intercellular, coagulated and shrunken by the reagents—the tumour then consisting of connective tissue, and round and oval corpuscles lying in an abundant intercellular substance, as in another form of myxoma.

Digitized by Google

22. *Calcareous degeneration of the aorta.*

Exhibited by R. W. BURNET, M.D.

THE calcareous deposit commences just above the semilunar valves, leaving them free, and gradually diminishes, as seen in the second specimen. The coats at the bifurcation were healthy.

The patient was a comparatively young man, aged 40. There was no history of syphilis or alcoholism.

No murmur was heard while the patient was under observation in the hospital. *January 4th*, 1881.

Digitized by Google

IV. DISEASES, ETC., OF THE ORGANS OF DIGESTION.

1. *Perforating ulcer of the stomach leading to fatal hæmatemesis thirty hours after birth.*

By James F. Goodhart, M.D.

This case can hardly be considered other than a curiosity. Mr. Cock, one of the senior students and late resident obstetric assistant at Guy's Hospital, was called to see a new-born infant vomiting blood, from which it died thirty hours after birth. It was apparently well-formed and healthy, though a possibility of congenital syphilis existed. The stomach was distended by blood-clot, and on turning this out, a small oval ulcer about ⅛ in. long was seen at the cardiac end and close to the greater curvature. The edge of the ulcer was peculiarly sharp and raised from the surrounding mucous membrane, it might almost be said to be knife-edged, and it was firm in texture and pink or vascular in appearance. In the bottom of the ulcer was a dark speck which, under a lens, proved to be an open vessel, a branch of an artery running along the greater curvature.

The remainder of the stomach was healthy.

In his work on 'Diseases of the Stomach,' Dr. Wilson Fox alludes to only one similar case, and that a doubtful one; and I cannot find that Lebert even alludes to such a condition. But ulceration of the stomach in infants at birth has been described by many writers on diseases of children—Rilliet and Barthez, Billard, Vogel, Henoch—and has been so described in connection with melæna neonatorum.

These ulcers have been ascribed to many causes, such as sudden interference with what has been till birth an habitual route for the blood: incomplete development of the respiratory organs;

Digitized by Google

thrombosis in the umbilical veins; and lastly, the ubiquitous bacteria.

How far any one of these was a potent cause in this particular case I am unable to say, as I saw nothing but the stomach, and this, having a due regard for the rarity of the specimen and the needs of our museum, I did not feel at liberty to examine thoroughly, that is, destructively in which sense alone could any examination have proved instructive.

May, 17th, 1881.

---

2. *A case of reduction "en masse" of a strangulated inguinal hernia from separation of the neck of the sac.*

[With Plate VI, fig. 1.]

By JEREMIAH MCCARTHY.

A MAN, aged 61, was admitted in the London Hospital in December, 1880, with a strangulated inguinal hernia on the right side. He stated that the rupture had existed for many years, and that he had always been able himself to reduce it completely. This time it had been down for three days, and he had not been able to reduce it, and had been sick. Taxis had been tried by a surgeon outside the hospital, and also by the house surgeon on duty on his admission, ineffectually. I was then sent for, and found the patient free from any urgent symptom. He had a large inguinal hernia about the size of a cocoa-nut, very tense and tender, and probably altogether formed of bowel. The patient was very obstinate and refused any treatment whatever. No further attempt to reduce it was made, and directions were given for the application of an ice bag. The following morning the house surgeon reduced it. He said that it slipped up very easily, and that he had merely to put his finger upon it to reduce it. In the afternoon, as the patient still vomited on taking any food, I examined him carefully and found the scrotal sac quite empty. Above Poupart's ligament, however, there was a slight fulness which gurgled on pressure. I wished to make an exploratory examination to ensure that all was right, but the

Digitized by Google

Digitized by Google

Fig. II.

Fig. I.

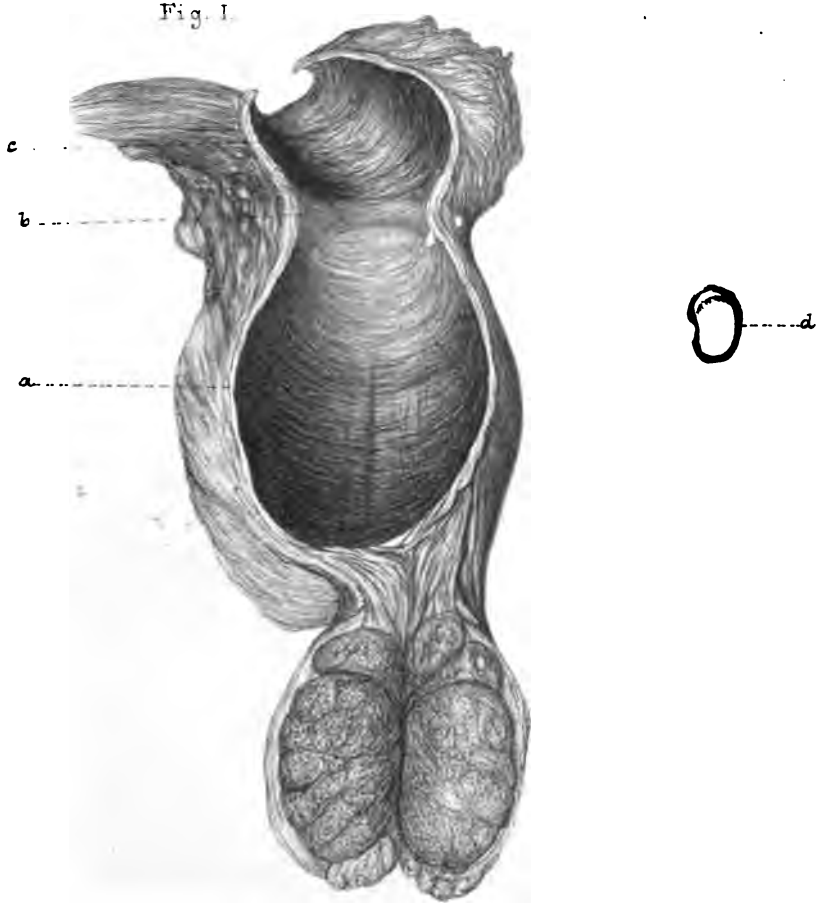

E. Burgess lith.

Digitized by Google

West Newman & C° imp

DESCRIPTION OF PLATE VI.

Fig. 1 shows the Hernial Sac from Mr. McCarthy's Case of Reduction *en masse*.

a. The portion of sac lodged in scrotum.

b. Constricted portion of same, lodged in very short inguinal canal and simulating neck of sac.

c. Portion of sac projecting upwards and backwards into abdominal cavity.

d. Detached "neck" of sac, which was found strangulating intestine. This was slightly curved on itself, so that when laid upon the table the upper margin was on a higher level than the rest, and cast a shadow on the paper beneath.

Fig. 2 illustrates Mr. Alban Doran's Case of Proliferating Cysts in the Ovary of a Seven Months' Fœtus.

FIG. 2.—Proliferating cysts in a fœtal ovary. From a micro-photograph by Mr. Francis Fowke. Two of the cysts are shown, as magnified by a 2-inch objective. The right-hand cyst measures $\frac{1}{16}$ inch in its long diameter. No Graafian follicles can be seen, but numerous enlarged vessels are exposed by section, and between the cysts, towards the free border of the ovary, lie a collection of small cystic or tubular bodies, which under a higher power are found to be lined with an epithelium similar to that which invests the growths in the large cysts.

Digitized by Google

Digitized by Google

patient refused to consent, declaring that all was quite right, and that he was very comfortable.

The next day the patient's sickness and obstinacy continued. On the third day he declared himself ready to undergo any operation that I might propose. On examination, however, I could find nothing to justify operative interference. The scrotal sac was empty. and the inguinal canal quite free. The fulness had disappeared and there was evidently peritonitis sufficient to account for the sickness. On the fourth day he died.

At the *post-mortem* examination the hernial sac was found to consist of two portions. The part lodged in the scrotum was empty and normal; above this was a constriction corresponding to the very short inguinal canal; above this the remainder of the sac projected into the abdominal cavity, and in shape resembled the bowl of an egg cup. The margin was rough and irregular, and was directed upward and backwards. The walls of this portion of the sac were so rigid from chronic inflammation as to maintain the sac patent although empty. The intestines were thickly coated with lymph. In the left hypochondriac region was a loop of intestine about a foot in length, gangrenous, and very tightly constricted by a fibrous ring, which was smooth at the upper margin and rough below. This ring was very evidently the detached margin of the upper part of the sac.

It is probable that the man had, in reducing his hernia from time to time, gradually produced a partial invagination of the sac into the abdominal cavity, and that from chronic inflammation this invagination had become persistent. The neck of the sac would therefore no longer correspond to the internal inguinal ring. Thus, in the final attempt at taxis, pressure would be exercised on the unsupported neck of the sac, and so the separation occurred. The detached ring no doubt is composed chiefly or perhaps altogether of organised products of inflammation, but none the less formed the upper limit of the sac and the obstacle to the reduction of the bowel. In this sense I have termed it the neck of the sac.

February 1*st*, 1881.

Digitized by Google

3. *Two cases of intestinal obstruction.*

By F. Charlewood Turner, M.D.

Case 1.—The specimen exhibited consists of the cæcum and adjacent parts of the ileum and colon, showing an unusual form of intussusception of the lower part of the ileum, the extremity of which projects through the ileo-cæcal valve into the cæcum. It shows also ulceration and perforation of the cæcum, which caused death from peritonitis.

The specimen was taken from the body of a boy, aged 11, who was admitted under my care into the North-Eastern Hospital for Children, on account of anæmia and weakness, and cardiac dilatation with signs of valvular disease, and pains in the limbs, which dated from an attack of acute rheumatism six weeks previously.

He was admitted September 27th, 1880. A month later (October 28th), while still confined to his bed, symptoms of intestinal obstruction suddenly developed, without any assignable cause. Ten days previously an erythematous eruption had appeared on the chest and arms, extending subsequently to the legs, and accompanied by some coryza; and five days later (October 23rd) some abdominal pains had been complained of, attended with vomiting. These symptoms passed off the next day, but again returned on the day before the symptoms of obstruction appeared. At the time of the occurrence of the abdominal pains the cutaneous eruption and the coryza were already passing off.

The symptoms of obstruction were quite acute and definite. The house-surgeon was called at 4 a.m. to the patient, who was suffering from great pain in the abdomen and vomiting, and had passed a small quantity of clear blood, with much straining.

When examined in the afternoon a characteristic sausage-shaped tumour was felt in the situation of the transverse colon. An injection of water per anum was followed by the moving of the tumour to the right iliac fossa. Subsequent attempts at reduction by similar means were made on the three following days, but without any success. On the fourth day (November 1st) a consultation, as to the advisability of operative interference, was held with Mr. Hutchinson, consulting surgeon to the hospital, and with my colleague, Mr. Waren Tay, of whose advice and co-operation I had already availed myself.

Digitized by Google

An operation was not recommended at that time, chiefly on account of the peculiar form and great mobility of the tumour when examined under chloroform. The urgent symptoms had been checked by small doses of opium. Renewed attempts at reduction of distension by the colon were prevented by the presence of some sensitiveness in the right iliac fossa.

On November 3rd, the sixth day, the bowels began to act again spontaneously, local tenderness continuing. This occurred the day after belladonna had been substituted for the opium treatment. On the following day (November 4th) the temperature, which had previously been normal, went up to 101·8° in the evening. On Novemher 5th there were well-marked signs of peritonitis, and the child died on the 7th, just ten days from the onset of the symptom of obstruction.

Since November 2nd there had been an icteric tinge of the skin and conjunctiva.

At the autopsy the invagination of the end of the ileum, shown in the specimen, was found forming a tumour, occupying the right iliac fossa. It was about 1½ inch in length, the ileo-cæcal valve crossing the middle of the tumour, and forming a slight depression in it. The cæcum, when seen *in situ*, was somewhat distended, but collapsed at once on manipulation, fæces escaping freely through a wide rent in its outer wall. It was laid open after removal and showed the end of the invaginated portion of the ileum projecting through the ileo-cæcal valve. It was deeply congested and capped with a soft, black, partially adherent clot. There was no tension of the ileo-cæcal valve, the closed point of a good-sized pair of scissors passing without difficulty through the invaginated bowel. There was an extensive area of ulceration on the outer side of the cæcum, at the base of which two large irregular openings were seen. The edges of the ulceration are sharply cut, and just above it are to be seen a few small circular ulcers of similar character, evidently of recent formation. Superficial ulceration had extended also over a corresponding area of the peritoneal surface of the cæcum at the same place.

At the apex of the invaginated bowel evidence of ulceration of an older date was found between the deep folds of the mucous membrane. There was some lymph deposited between the opposed peritoneal surfaces at the commencement of the invagination; but it appeared that it could have been reduced without difficulty.

Digitized by Google

There were flakes of lymph on the other coils of intestine, and larger quantities over the stomach and liver. About a pint of thin purulent fluid was found in the peritoneal cavity. No extravasation of fæces had occurred. The colon contained much scyballous fæces. The heart was contracted. The mitral valve thickened merely.

This case is of interest on account of the very unusual form of the intussusception, and from its having been complicated with ulceration of the ensheathing bowel.

The passage of a portion of the ileum through the ileo-cæcal valve is a rare event. Its occurrence in this case offers a sufficient explanation of the failure of attempts to complete the reduction of the invagination by distension of the colon. An equal impediment must have been presented to any natural effort at reduction by contraction of the colon.

Ulceration of the ensheathing fold of bowel, such as that seen in the specimen, is also a very exceptional occurrence in cases of intussusception. This fact naturally raises the question as to whether it may in this case have been dependant upon injury to the gut caused by the force used in attempt at reduction. The characters of the ulceration, which is precisely that of the effect of irritation to the mucous membrane and its contents, does not accord with this view; and in cases where death has resulted from forcible over distension of the colon, the peritoneal surface has especially suffered, and death has resulted within a few hours, even, I believe, where no lesion of the bowel could be distinguished.

There are two other causes from which this ulceration may have arisen.

1. Dr. Aitken, in reference to perforative peritonitis as a cause of death in cases of intussusception, mentions amongst other cases that of a soldier, aged twenty-two, in whose case the end of the included gut had worn a hole through the wall of the containing bowel by pressure and rubbing. It is perhaps most probable that the ulceration of the cæcum arose in a similar manner in the present case.

2. It is possible, however, that the ulceration may have been antecedent to the invagination, and connected with the erythematous eruption on the skin, with the appearance of which the first observed abdominal symptoms were closely associated. If present it would have offered conditions favorable to the occurrence of

Digitized by Google

intussusception, which might account for its appearance under conditions in which it would appear to be especially unlikely to happen. *May 3rd*, 1881.

Case 2.—The specimen consists of the last few feet of the ileum, with the mesentery attached, and the ascending and part of the transverse colon, from a case of internal strangulation of the bowel, fatal on the fourth day. It shows a cord containing a diverticulum from the ileum, which was connected with the abdominal wall at the umbilicus. There is also a plum-stone in the ileum, which was found just above the diverticulum.

The specimen was taken from the body of a well-developed, healthy-looking boy, aged 10½, who was admitted into the London Hospital on March 22nd with symptoms of strangulation of the bowel of nine days' duration, and in a state of great exhaustion.

It appeared that he had been quite well until three days previously, and that then, having complained of some abdominal discomfort the evening before, attributed to the disagreement of some cake he had eaten, he was suddenly seized at 3 a.m. with severe abdominal pain and vomiting. The bowels at the same time acted freely, but had not been moved since. The pain and vomiting continued very severe during that and the following day. They were much less severe on the third day, on which he was admitted to the hospital. At the same time the mother noticed that the character of the vomited matter was changed; having previously been only the milk and other food rejected, it now had a yellow colour like yolk of egg. At the time of admission he vomited frequently, but was free from pain, and could turn on to either side without distress. The abdomen was much distended, not tender. The percussion resonance was full at the upper part, but comparatively flat in the hypogastric and lower umbilical regions, giving the impression that the intestinal coil in this situation were much less distended than the rest. There was no history of any previous trouble in the bowels beyond an occasional stomach-ache, to which no particular importance was attached. The boy himself stated that two months previously he had had a severe pain in his abdomen which lasted a whole day.

Mr. Rivington was called in consultation upon the case, and opened the abdominal cavity. He found the band, shown in the specimen, and several coils of congested bowel coming forward to

Digitized by Google

the right of it. These coils of intestine had got pushed from left to right behind the cord, and had become strangulated by it. They were restored to their proper position and the wound was closed. At the operation three bodies like plum-stones were felt in the strangulated coils of bowel.

The operation, though thus revealing a condition in which such interference afforded the only chance of relieving the patient, was unhappily too late, death occurring a few hours afterwards.

At the autopsy the upper part of the abdominal cavity was found filled with greatly distended coils of small intestine. The hypogastric region was occupied by several deeply congested coils, which were not distended in an unusual degree. These concealed the lower part of the cord shown in the specimen, which passed to the right of them forwards and upwards from a deeply situated part of the ileum to the abdominal wall, which it reached just below the umbilicus in the median line. It is connected with the ileum at a point about eighteen inches from the ileo-cæcal valve, and contains a narrow diverticulum about two inches long. The ileum below this point was completely contracted, as also was the whole of the large intestine. Immediately above the attachment of the cord the coils of congested bowel commenced. Between two and three feet of the ileum were thus congested. The coils of intestine above were greatly distended. The congested coils of ileum were thickened, and their surfaces marked with numerous black round spots, due to hæmorrhagic extravasation in the submucous connective tissue. There was recent lymph upon their surface. No general peritonitis. Within the ileum, immediately above the cord, a plum-stone was felt. Two other plum-stones and two pieces of bone were washed out of the ileum above.

In this case the sharp flexion of the ileum at the point of origin of the diverticulum, caused by the passage of the coils immediately above it behind the cord from left to right, and by traction on the ileum at that point by tension of the cord produced by this displacement, would necessarily cause a narrowing of the channel of the intestinal tract there, such that the arrival of a plum-stone might easily cause complete obstruction.

To account for the occurrence of strangulation under such conditions, the further effect of distension of the coils of small intestine above the displaced and incarcerated coils must be taken into consideration. The effect of this distension being to push the latter

Digitized by Google

coils downwards and to the left in front of the cord, that being their proper situation, and that of the sigmoid flexure, which, with the whole of the intestinal tract below the diverticulum, was completely emptied at the time that obstruction occurred. That the strangulated coils were crowded down in this region was indicated by the fact that when the abdomen was examined just after the patient's admission, it was in this region that flat percussion was found. This was more noticeable from the fact that it was the right iliac fossa to which my attention was drawn in the first instance, as there was a history of congenital inguinal hernia on that side, for which a truss had been worn up to the age of four years. *May 17th*, 1881.

---

4. *Adenoid disease of the rectum (cancer).*

By W. Harrison Cripps.

[With Plates VII to XVI.]

Two years ago I published in the Jacksonian prize essay certain observations on the pathology of malignant rectal disease. The object of the present communication to the Society is to exhibit a series of microscopic specimens illustrating this subject. The sections, drawings, and diagrams exhibited have specially been prepared for the Society, and form a distinct series from the drawings published in the work referred to.

The drawings, as far as possible, are exact representations of the specimens beneath the microscope, by the side of which each is placed; thus members have an opportunity of comparing their accuracy. This explanation is necessary to account for the want of clearness in some of the drawings.

The sections exhibited are selected from many thousands, cut from a great number and variety of rectal tumours. A considerable portion of them were removed from the body during life, the specimens being immediately transferred to the hardening fluid, so that, at the most, a few minutes only elapsed between their removal from the living body and their transfer to the preparation bottle.

It was found by experience that the beauty and clearness of the

Digitized by Google

preparation obtained was in inverse proportion to the time lost between its removal and preparation. From this cause specimens obtained from the dead-house were of little value for minute work, owing to disintegration and shrinkage of the cellular element.

Malignant disease of the rectum has enjoyed its full share of classification. Its nature has been described under the heads of scirrhous, medullary, and epithelial cancers, sarcomas, round and spindle-celled, myxomas, adenomas, &c.; while the innocent tumours have been described as villous growths, papillomata, and polypi.

The older writers founded a simple classification, according to their clinical experience, of these growths, and were content with two varieties—cancer (malignant growth) and the villous tumour (an innocent formation). This classification into simple or malignant growths is of considerable clinical value, but it assumes too much, and draws too hard a line between the two varieties of tumour. For notwithstanding that, in a large number of cases, the future of the disease can be accurately predicted, there remain a certain number of growths whose malignancy is of such a modified type that it is impossible accurately to forecast their future behaviour. They form, as it were, the connecting link between the malignant and innocent disease, but yet are not fairly provided for in that nomenclature.

Recent attempts to define these growths according to their minute anatomical structure is certainly more scientific, and if only accurate would form no cause of complaint. In the rectum, however, to which the present observations are confined, I have failed to discover any growths or tumours consisting entirely of the characteristic structure which pathologists designate as scirrhous or medullary cancers, or as belonging to the various varieties of sarcoma. Considering the eminence of many careful observers who have applied such names to these growths, it would be quite unjustifiable to assume that such distinctive structures never form the entire bulk of the tumour; but I feel bound to state that with, perhaps, a more than average opportunity of examining such growths from the rectum, I have been unable myself to discover tumours composed entirely of the distinctive features appertaining to these diseases.

It must not be supposed that all these growths have a similar structure. On the contrary, it is seldom that any two accurately correspond in their construction, but such differences as exist depend

Digitized by Google

Digitized by Google

Fig. 1.

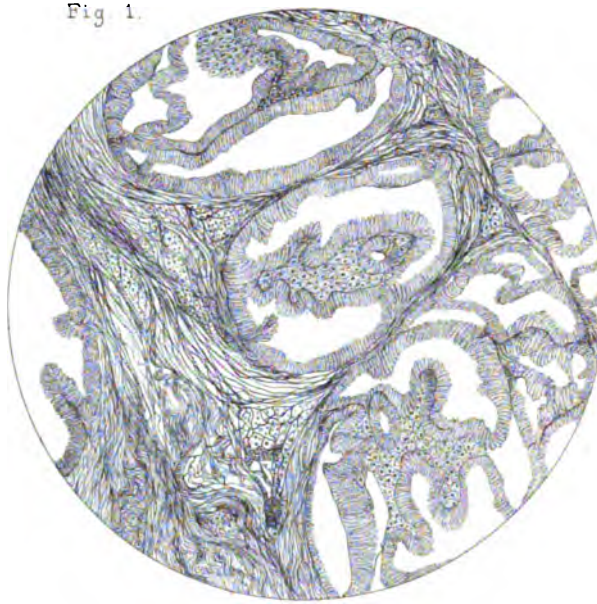

Fig. 2.

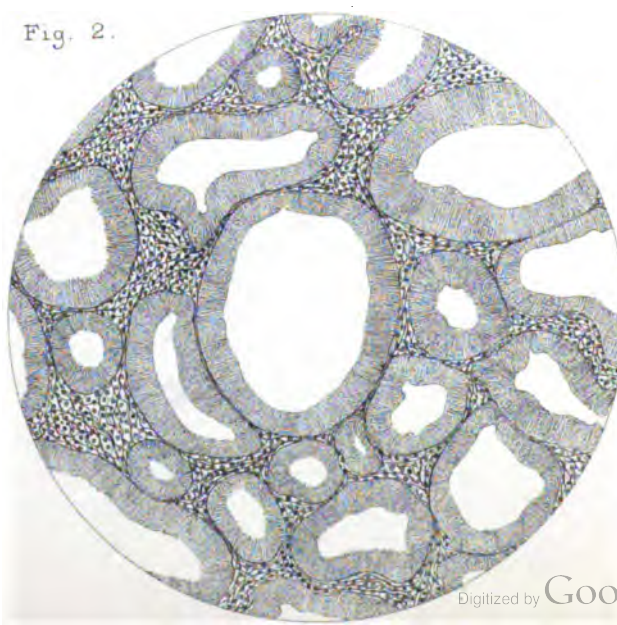

Digitized by Google

DESCRIPTION OF PLATE VII.

To illustrate Mr. Harrison Cripps' paper on "Adenoid Disease of the Rectum."

FIG. 1.—Section of slow-growing adenoid rectal tumour extending along the submucous tissue. Some of the cavities are becoming filled with growth from the walls. The intervening bands of fibrous tissue are well marked. (Low power.)

FIG. 2.—From very slow-growing tumour. The epithelial cells are very clearly marked, and the intervening retiform tissue well developed. (Hartnack, ob. 4.)

Drawn by Harrison Cripps.

Digitized by Google

Digitized by Google

Digitized by Google

Fig. 1.

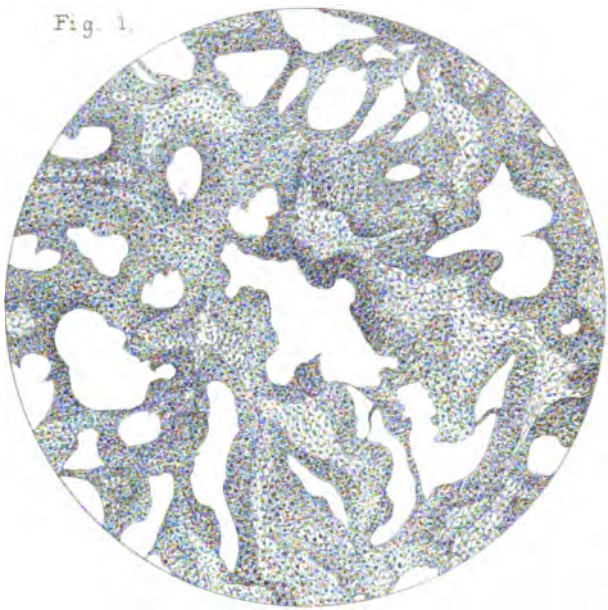

Fig. 2.

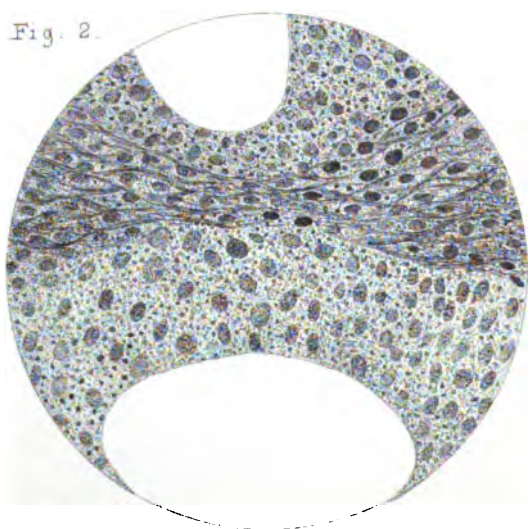

Digitized by Google

DESCRIPTION OF PLATE VIII.

To illustrate Mr. Harrison Cripps' communication on Adenoid Disease of the Rectum.

FIG. 1.—From a rapidly-growing recurrent fungous mass forming a large tumour in a few weeks. Close inspection shows its adenoid nature, and that it is formed on the same plan as the growth shown in Plate VII. The cavities are very irregular. The epithelial lining and the intervening retiform tissue are but embryonic and ill defined. (Low power.)

FIG. 2.—Portion of the same under a higher power. The epithelial lining is scarcely recognised as individual cells, but rather resembles a mass of nuclei with their large axes pointing towards the cavities. The intervening retiform tissue is represented by an ill-defined, spindle-celled tissue. (Hartnack, ob. 9.)

Drawn by Harrison Cripps.

Digitized by Google

Digitized by Google

Digitized by Google

Fig 1.

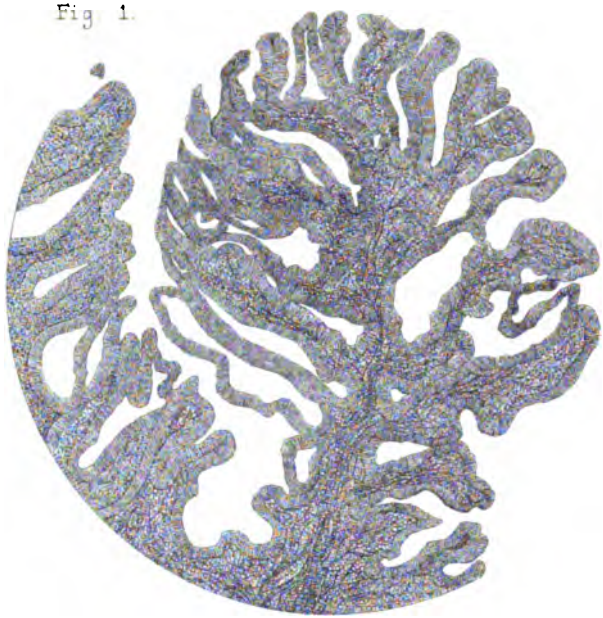

Fig. 2.

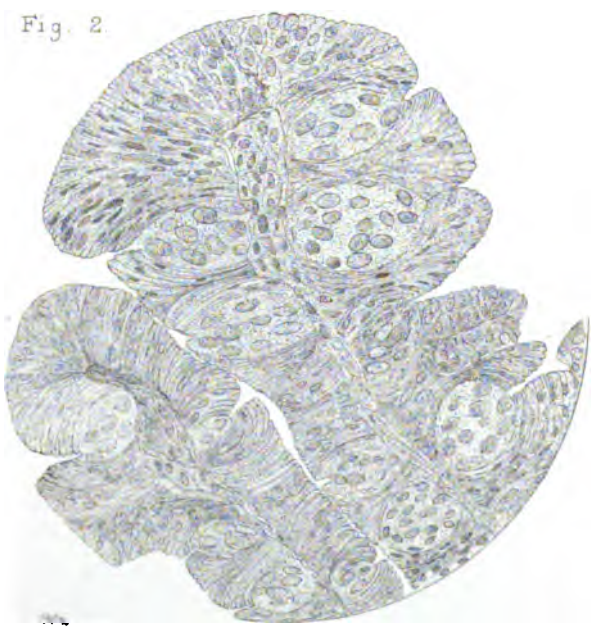

Digitized by Google

DESCRIPTION OF PLATE IX.

To illustrate Mr. Harrison Cripps' communication on Adenoid Disease of the Rectum.

FIG. 1.—Section cut at right angles to the surface of an innocent adenoid growth. The bipenniform arrangement of the epithelial cells upon a fine retiform tissue is well seen, and some of the fibres from this retiform tissue can be traced running from the lateral leaves into the central stalk. (Low power.)

FIG. 2.—From a slow-growing tumour probably, but not certainly of an innocent nature. Various secondary buds are commencing to grow from the surface of the projecting spikes.

The large oval bodies seen between these buds are the bases of cells forming buds, which have been cut across at right angles to the section. (Hartnack, ob. 7.)

Drawn by Harrison Cripps.

Digitized by Google

Digitized by Google

Digitized by Google

Fig. 1.

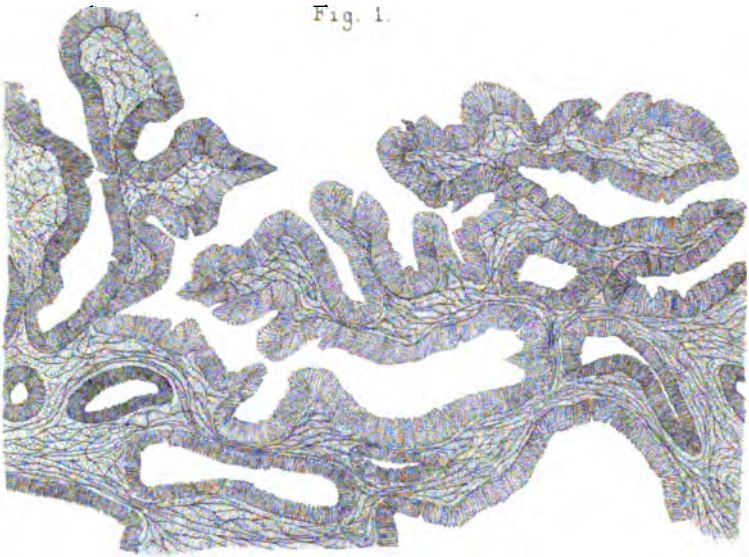

Fig. 2

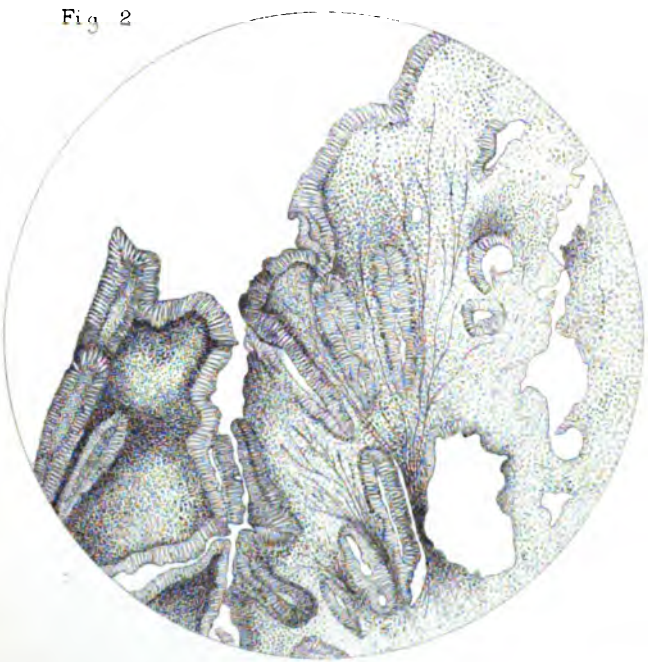

Digitized by Google

DESCRIPTION OF PLATE X.

To illustrate Mr. Harrison Cripps' communication on Adenoid Disease of the Rectum.

In this Plate sections cut through the surface towards the deeper part show how some of the cavities in the central portion of the tumour are formed.

FIG. 1.—In this figure the border is highly convoluted, and in places it bends over, so that the cells on the surface of different portions come nearly into contact. (Low power.)

FIG. 2.—From the advancing margin of a deeply ulcerated, crater-like mass of disease. The surface is slightly convoluted, and the quantity of retiform tissue is largely in excess of the epithelial element. This tumour recurred twice during the first year after removal. No recurrence has since taken place (three years).

Drawn by Harrison Cripps.

Digitized by Google

Digitized by Google

Digitized by Google

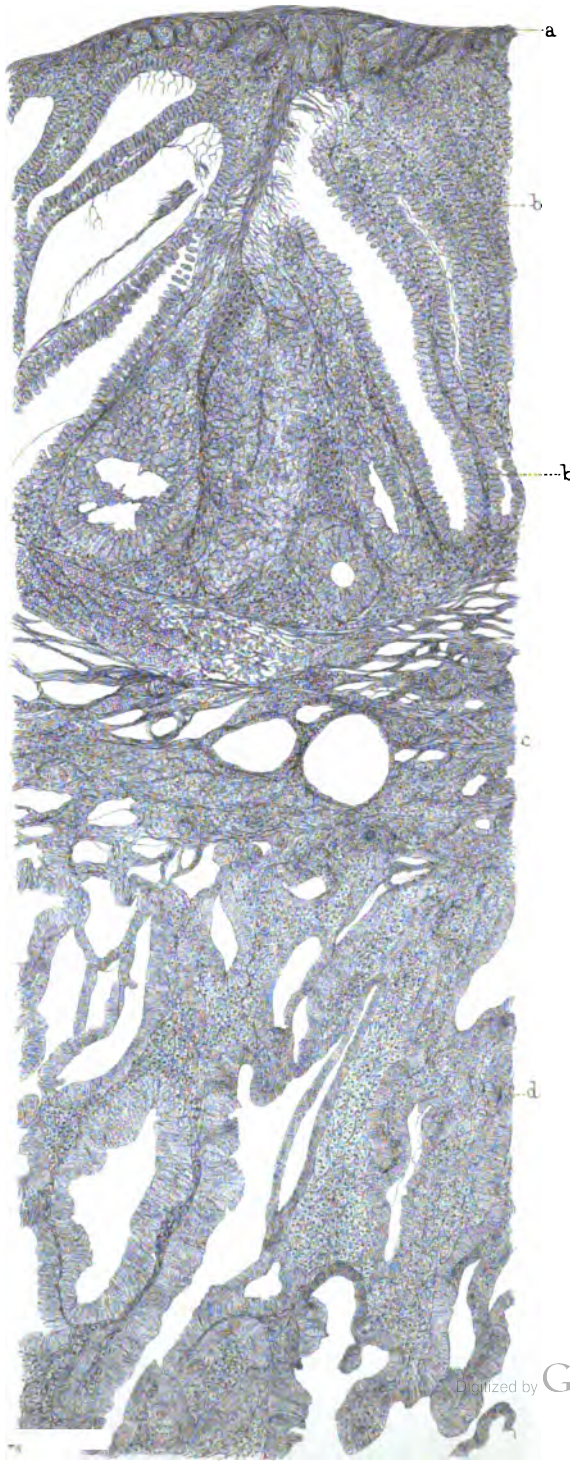

Digitized by Google

DESCRIPTION OF PLATE XI.

To illustrate Mr. Harrison Cripps' communication on Adenoid Disease of the Rectum.

Section of adenoid growth extending along the submucous tissue between the mucous membrane and the muscular coat.

a. Gelatinous material of doubtful nature (mucous?) covering the free surface of the bowel, and dipping into and blocking up some of the follicles. (Hartnack, ob. 4.)

b, b. Greatly hypertrophied Lieberkuhn's follicles.

c. Part of the submucous tissue crowded with small cells, but not invaded with the morbid gland tissue.

d. Well-marked morbid adenoid growth.

Drawn by Harrison Cripps.

Digitized by Google

Digitized by Google

Digitized by Google

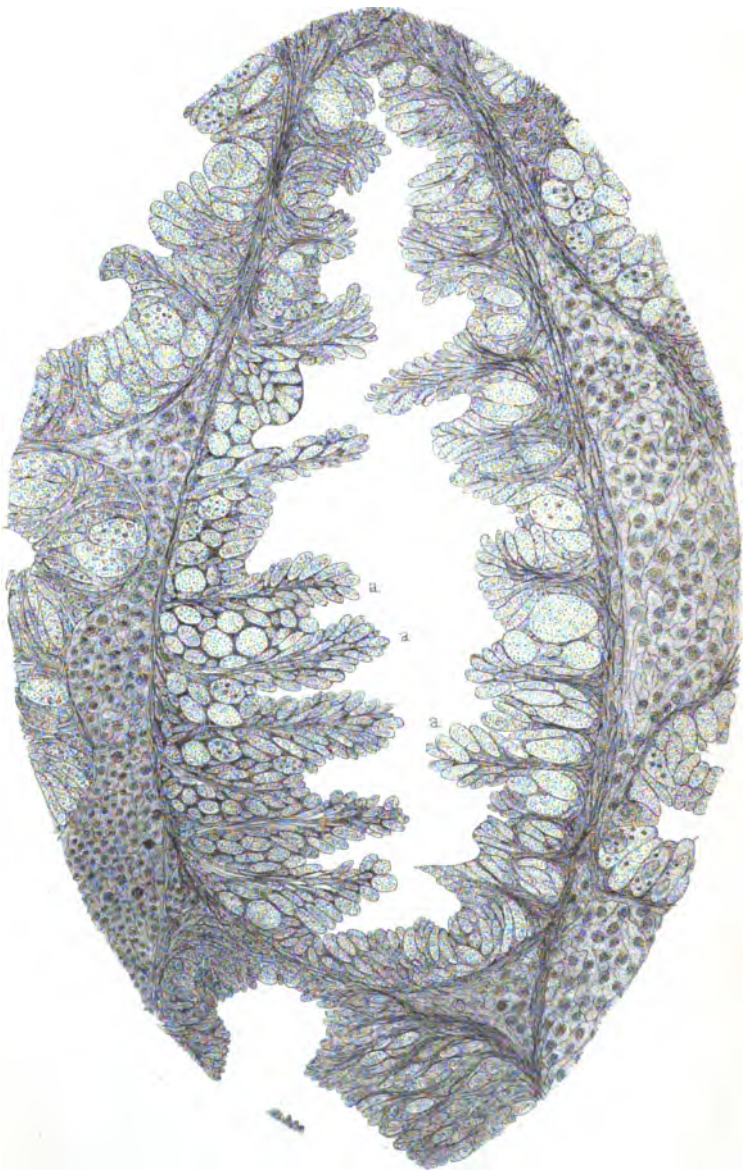

Digitized by Google

B. Harrison Cripps del

Muntern Bros lith.

DESCRIPTION OF PLATE XII.

To illustrate Mr. Harrison Cripps' communication on Adenoid Disease of the Rectum.

Section of follicle in adenoid growth. The cavity is becoming filled with secondary growths (*a*, *a*, *a*) from the lining walls. As the young cells are formed at the summit of the leaf they gradually elongate and bend over at right angles to the centre of the advancing bud. In the lower portion of the section the formation of fibrous tissue from the epithelial cell walls can be traced. (Hartnack, ob. 4.)

Drawn by Harrison Cripps.

Digitized by Google

Digitized by Google

Digitized by Google

Fig. 1.

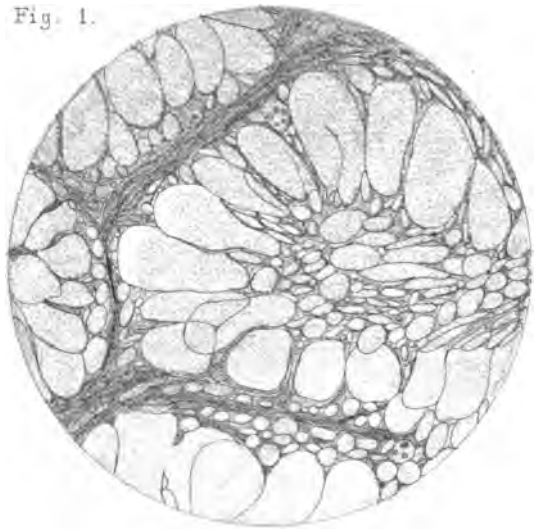

Fig. 2.

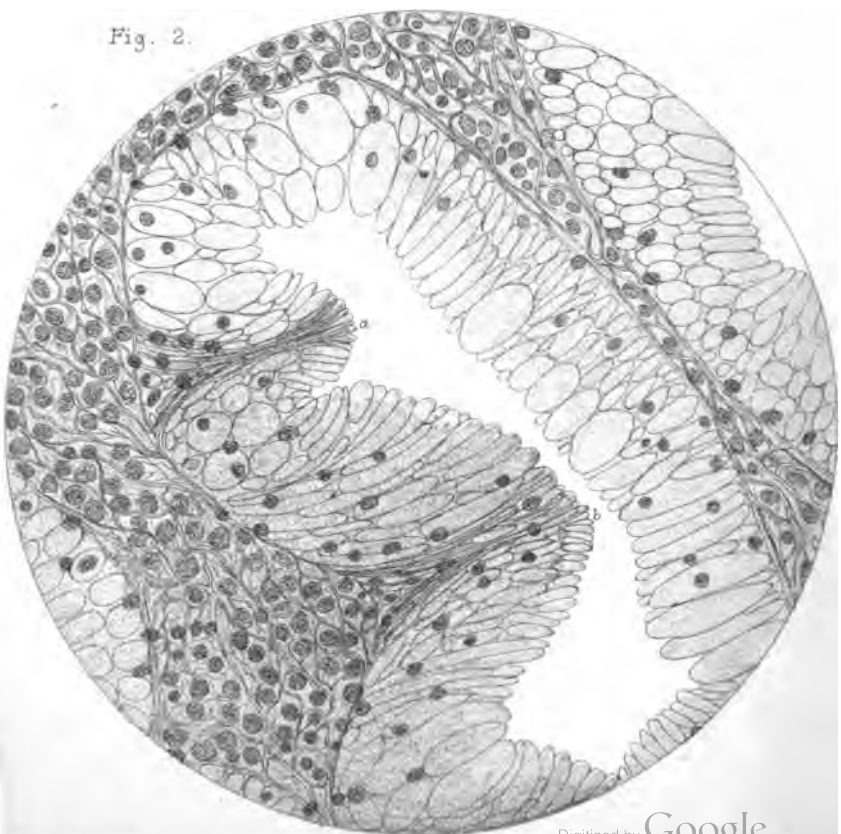

Digitized by Google

DESCRIPTION OF PLATE XIII.

To illustrate Mr. Harrison Cripps' communication on Adenoid Disease of the Rectum.

Fig. 1.—Section of enlarged follicle in immediate neighbourhood of an advancing growth. The walls of the large epithelial cells are seen to be continuous with the intervening fibrous tissue.

Fig. 2.—Section of follicle in morbid growth. The lining cells are extremely long and narrow and chiefly without nuclei. At *a* and *b* secondary buds are forming.

Drawn by Harrison Cripps.

Digitized by Google

Digitized by Google

Digitized by Google

Fig. 1.

Fig. 2.

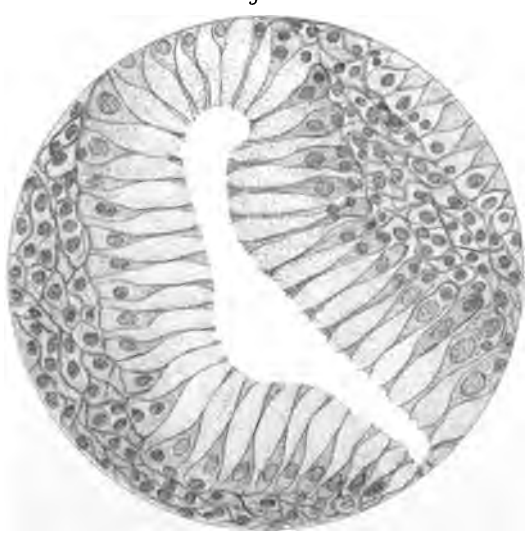

B Harrison Cripps del.

Digitized by Google

Minten Bros sc

DESCRIPTION OF PLATE XIV.

To illustrate Mr. Harrison Cripps' communication on Adenoid Disease of the Rectum.

Fig. 1.—Section of growth showing the supposed identity of the nuclei of the epithelium with the lymph corpuscles. (Hartnack, ob. 7.)

Fig. 2.—Follicle showing the absence of any basement membrane between the bases of the epithelial cells and the retiform tissue.

Drawn by Harrison Cripps.

Digitized by Google

Digitized by Google

Digitized by Google

Fig. 1.

Fig. 2

Fig. 3.

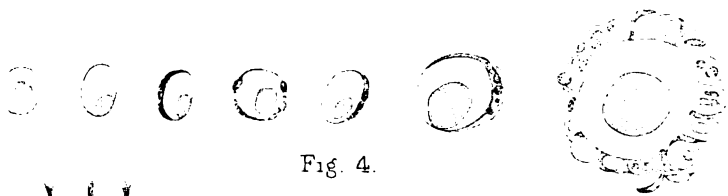

Fig. 4.

Fig. 5.

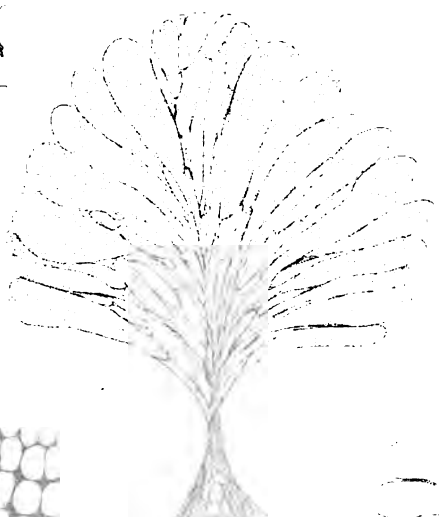

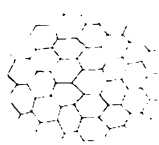

Fig. 6.



Fig. 7

Fig. 8.

Fig. 10.

Fig. 9

Digitized by Google

DESCRIPTION OF PLATE XV.

To illustrate Mr. Harrison Cripps' communication on Adenoid Disease of the Rectum.

FIG. 1.—A series of cells from surface of adenoid tumour.

FIGS. 2 and 4.—Cells from deeper portions of the growth.

FIGS. 3 and 8 show how the appearance of a stellate cell may be produced by the adhesion of a cluster of cells back to back.

FIGS. 5, 6, 7, 9, and 10 illustrate the formation of fibrous tissue from the walls of the epithelial cells.

Drawn by Harrison Cripps.

Digitized by Google

Digitized by Google

Digitized by Google

Fig 1

Fig 2

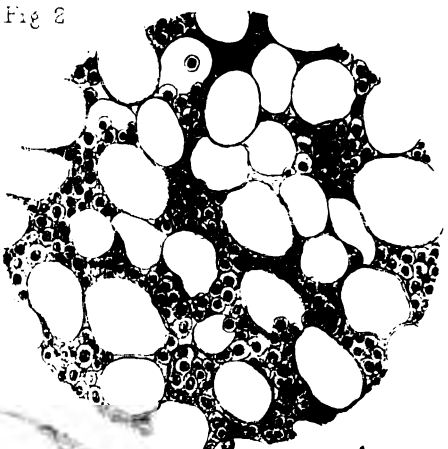

Fig 3

Fig 4

Digitized by Google

Mintern Bros lith.

DESCRIPTION OF PLATE XVI.

To illustrate Mr. Harrison Cripps' communication on Adenoid Disease of the Rectum.

FIG. 1 shows the morbid cell growth extending into fatty tissue.

FIG. 4 shows, under a high power, how small lymphoid cells are insinuating themselves between the fat cells.

FIG. 2.—The small cells have increased in size and quantity, and they have more of an epithelial appearance and compress the fat cells between which they lie.

FIG. 3.—A more advanced stage of growth, the invading cells having a distinctly epithelial appearance. (Hartnack, ob. 9.)

Drawn by Harrison Cripps.

Digitized by Google

Digitized by Google

rather upon the details of the growth than on any difference in the general plan on which it is formed. The length of time that the tumour has existed, the particular tunic which it has invaded, or the portion of growth from which the section has been cut, are sufficient to account for the varying appearances obtained by the microscope without the assumption that different types of the disease exist. It not uncommonly occurs that the particular features supposed to be characteristic of each type may be observed in the several portions of the same specimen, or that a tumour which, on its original removal, presented one variety, will on its recurrence present another.

Excluding the form of cancer known as colloid, as to the nature of which I am not altogether satisfied, it will be found that there is one characteristic structure common to almost all morbid growths in the rectum. This structure consists of gland tissue similar to Lieberkühn's follicles. By careful examination this tissue can be demonstrated in almost every specimen, but yet now and again search fails to disclose this gland tissue. These exceptional specimens usually present dense fibrous tissue, with only a small amount of cell element; but a considerable amount of such structure is always found in the older parts of typical glandular growths, where it can be demonstrated to be in direct continuity with, and to be formed from, the adenoid tissue. It is probable, therefore, that in the exceptional specimens either glandular growth existed in other portions of the specimen, but escaped detection, or that it had been present in an earlier stage of the growth, but had passed away before the specimen came under examination.

If these growths are to be named according to their anatomical structure the term adenoid will appear to be the most applicable.

Such expressions as malignant, semi-malignant, or simple adenoid, would, moreover, be sufficiently distinctive for surgical purposes, and at least have the merit of being in accordance with clinical and histological observation.

It is generally easy for a surgeon of experience to determine, as the result of clinical observation, whether a growth in the rectum be of an innocent or of a malignant nature. Occasionally, however, the characters of the disease are not sufficiently marked to admit of a positive prognosis. The quickly growing tumours, or those which have deeply eaten into the surrounding texture, are almost certainly malignant, while the more slowly developed growths pro-

Digitized by Google

jecting into the rectum, without extending into the deeper tissues, are generally innocent.

Growths will be found occupying, as it were, a position in regard to their clinical features midway between the extremes mentioned. Such growths admit only of approximate prognosis, as their features tend more or less in the direction of the innocent or malignant type.

Seeing thus, that from clinical observation it is possible to speak with considerable certainty as to the future of rectal growths, the question naturally arises whether the anatomical structure when examined by the microscope presents any constant appearances by which a malignant may be distinguished from an innocent tumour.

Although, as before stated, these growths are all constructed upon the plan of glandular tissue, yet I have no hesitation in affirming that it is generally possible to find appearances presented under the microscope by which the innocent or malignant nature of the growth can be established. However, just as in clinical observation so under the microscope, there will still remain specimens in which the structure presented lacks the distinctive features common to either of the pronounced types.

In commencing a description of these growths it may be well briefly to call attention to the typical appearance both of an innocent and malignant variety without attempting to describe intermediate links.

The innocent growth forms a soft tumour projecting into the cavity of the bowel. It sometimes has a fairly marked pedicle, especially if the growth has existed any length of time, but this pedunculated appearance is generally produced by the mass being constantly dragged upon during efforts of defecation, and thus drawing down the healthy mucous membrane around the base of the growth so as to produce the appearance described.

In the more malignant varieties, the new growth frequently spreads as a thin layer between the muscular and mucous coats. In this form it often occupies several square inches of the bowel while its thickness does not exceed a quarter of an inch. At first the mucous membrane lies intact over such a layer, but eventually it gives way by ulceration. This ulceration sometimes commences at more than one point so that the mucous membrane becomes honeycombed, and portions of the subjacent growth may even

Digitized by Google

sprout through it. The destructive process not only destroys the mucous membrane over the surface of the growth, but after a while the new growth is itself destroyed by the ulceration. While destruction is proceeding towards the centre the growth is advancing towards the circumference. In this way a crater-like mass of disease is produced, the centre of which consists of a dense fibrous tissue belonging to the muscular coat of the bowel, which appears for long to resist the ulcerative process. The margin of the crater consists of hypertrophied mucous membrane of the bowel, heaped up by the extending growth beneath it, tucking it over in such a manner as to overlap the healthy membrane. The border is at times so irregular as to represent a series of nodules rather than a continuous line.

It not unfrequently happens during the course of this laminated form of disease, that a portion of the growing margin at one or more points breaks beyond the restraining power of the mucous membrane, and rapidly develops into a fungating mass projecting into the bowel cavity.

Having in a previous publication at some length explained the mechanism by which contraction and stricture occur in these cases, the subject will not now be further discussed.

If sections be taken from an adenoid rectal growth, they will present a totally different structure according to the portion from which they are cut. Slices from the margin will show hypertrophied mucous membrane with a glandular growth beneath it, while sections through the centre show little more than the remains of a muscular coat involved in a dense cicatricial tissue. Again, sections from a fungating point will disclose a structure different from either of the preceding.

The powers that I have found most convenient in examining the structure of these growths are a 1-inch for obtaining a view of the general plan of a section, and a 1·9th for studying the same in detail.

It is difficult to obtain specimens of the disease in its earlier stages, and I regret never having had an opportunity of examining a primary growth at its commencement. An opportunity, however, has occurred in obtaining a secondary nodule of not more than a few week's duration, and which had scarcely attained the size of a pea.

During life this morbid growth was indicated by a small spot of

Digitized by Google

red-looking mucous membrane, the colour being produced by the deeper increased vascularity, while the projection was partly due to hypertrophy of the mucous membrane, and to a deposit in the submucous tissue causing it to project. On section the nodule consisted of mucous membrane, the follicles of which were from two to three times their normal length, the growth beneath consisting of a collection of an enormous number of leucocytes in the retiform tissue, the fibres of this retiform tissue being also much thickened and increased in quantity.

No downward dipping of the blind ends of the mucous follicles could be observed, nor could any definitely formed glandular growth be seen. But with the knowledge that such glandular structure is almost invariably present in more advanced stages of the disease, and had been specially well marked in the primary growth, to which the nodule just described was secondary, and further, seeing that the advancing border of an adenoid growth in the submucous tissue is always marked by a cloud of such cells, it would appear to be a fair deduction that the accumulation of leucocytes in the submucous tissue preceded the actual development of a new glandular growth. But this matter will be again alluded to when the method by which the growth into the deeper tissues is considered and compared with its extension on the surface.

If a section be cut from a slow growing projecting tumour, a structure will be seen similar to fig. 2, Plate VII. Its structure is clear and definite, and its glandular nature admits of no possibility of doubt.

A series of spaces are observed lined by a layer of columnar epithelium. The apices of the cells present a free border looking into the cavity, their bases rest upon a layer of retiform tissue. In such a specimen the columnar epithelial cells and their nuclei are definitely and distinctly marked, while the retiform tissue upon which they rest discloses a clearly-marked fibrous structure, in the interstices of which are perfectly defined leucocytes. Fig. 1, Plate VII, also represents a section from a slow growing tumour, but in this specimen the spaces have become partially obliterated. For this there are two explanations. At times simple external pressure has obliterated the cavity by causing the apices of the epithelial cells on the one side to come in contact with those of the opposite side (fig. 2, Plate XIII). At other times the cavities are obliterated by secondary growths springing from their walls (Plate XII).

Digitized by Google

If attention be now turned from these sections of slow growing, well-developed tissue to such a specimen, as is figured in Plate VIII, fig. 1, taken from a fungoid growth producing a considerable mass in a few weeks, it will be seen that the growth is upon the same plan as the specimen previously described, consisting of a network of spaces. But the absence of the distinctive features seen in the former is at once remarked. The clearly defined epithelial cells resting on an equally distinct retiform tissue can no longer be seen. In such a specimen under a low power, the difference between the retiform tissue and the epithelial lining is scarcely more marked than by a difference in the staining. Such a specimen in fact resembles a section of a well-developed growth seen with an unfocussed objective.

Under a high power the differentiation of the specimen is more clearly marked. Referring to fig. 2, Plate VIII, it is seen that the epithelial lining is represented by a series of clearly defined oval nuclei surrounded by a protoplasm, with their long axes pointing towards the cavity. The retiform tissue, instead of representing clear fibres and lymphoid cells, is little more than a sarcomatous spindle-celled tissue. The identity of the structure of the embryonic with the more perfect tissue can not only be traced by the varying degrees of development in different specimens, but it is possible in some cases in the same specimen to trace the embryonic to a more highly developed tissue.

In viewing these specimens the fact of their being sections only must be kept in sight, and it must be remembered that the representation in the plates referred to are but isolated slices from a beautiful and complete structure. If we cut into thin slices a brussels sprout or the heart of a cabbage, we shall have a representation on a big scale, not altogether unlike the section of a projecting adenoid tumour. The section of the vegetable shows a series of irregular spaces lined by cells, which in their turn rest on fibrous and retiform tissue, fine in some places, thick in others, the spaces are in reality the intervals between the leaves, the retiform and fibrous tissue is the central plane of each leaf, the lining cells being those forming the surface of the leaves.

In order to see this tree-like arrangement in adenoid growths, sections should be cut at right angles to and including a portion of the free margin.

The degree to which these processes are developed varies enor-

Digitized by Google

mously in different tumours. In some they are so highly developed as to cover the whole surface of the tumour with an infinite number of almost tree-like projections, in which central stalks of fibrous or retiform tissue can be seen shooting upwards and sending off lateral offshoots on which the columnar epithelium is arranged in a bipenniform manner (figs. 1, 2, Plate IX); while in others, these projections are much more simple, amounting to little more than the raising of the epithelium into undulating ridges (fig. 2, Plate X). Some of these projections, as shown on section, look like villous spikes, but it must be borne in mind that this appearance is produced by the specimens being thin slices, and therefore many of these spikes are but broad processes or leaves seen in section (fig. 2, Plate IX). If a portion be placed in spirit and examined carefully with direct light by a 1-inch power, the surface of some of the tumours have a very remarkable appearance, somewhat resembling an ant-hill thickly studded with fungi. Upon closer inspection these bodies are seen to be projections from the surface of the tumour. Some are mere asparagus-looking spikes, while others are broad, very thin leaves.

Both surfaces of each leaf consists of a layer of columnar epithelium, between which lies the retiform tissue forming the central portion of the leaf. In some places these leaf-like processes have a tendency to bend over towards each other, and unite at their margins; in others, the leaves curl upon themselves, their opposite borders coming into contact. Sometimes, however, each border curls upon itself like a dried-up leaf. In some, at one or more lines along their surface, little ridges appear, which in time become secondary leaves, and after a while behave in a similar manner to the primary ones. These secondary processes always appear on the concave surface of the parent leaf, thus they often become enclosed by its advancing border. Secondary offshoots, as just mentioned, throw off tertiary projections, so that ultimately an exceedingly intricate pattern is produced.

By reference to Plate X, fig. 1, the explanation of the cavities previously described, lying far away from the surface, and lined with epithelium, is apparent; for it will be at once seen that such epithelium was at a previous stage a portion of the free surface of the tumour.

In a previous publication on this subject I stated my belief that these cavities were actually cut off from the surface by the arching

Digitized by Google

over and subsequent coalescing of the cells forming the epithelial margin. I am not, however, as the result of further observation, quite clear that such spaces are in reality actually cut off by such coalescing, nor is it necessary that this should be the case to account for these cavities. It is possible that the epithelial lining of such a space might still be in continuity with that on the surface through intricate and convoluted channels. The plan by which these cavities, far away from the surface, become filled with secondary growths, is by a means precisely similar to the extension of the growth on the surface.

Before considering in detail the method by which the epithelial border extends, it is necessary briefly to consider the structure of the normal mucous membrane of the intestine.

This consists essentially of two layers, the superficial being a single layer of columnar epithelial cells, the second a layer of retiform tissue lying beneath it.

In order to economise space, and to enormously increase the superficial area, the two membranes are folded in such a way as to produce an infinite series of depressions commonly known as Lieberkühn's follicles.

In the small intestine the area is still further increased by drawing out, as it were, the tissue between the follicles in such a way as to produce distinct villi. But whether as depressions or projections the plan is the same, epithelial cells resting on a retiform tissue.

It is so important in its bearing on the growth of malignant disease that I must pause for a moment to consider what these epithelial cells mean. They line the whole alimentary tract, and I have calculated that there are something like 50,000,000 of these cells in each square inch in our bodies. Each of these units probably represents an individual life, requires nourishment, grows, and multiplies by the division of its nucleus.

It forms its habitat in our bodies. We give it warmth and nutrition, whilst it, in its turn, supplies us with the superfluity of its offspring by passing a portion of its nucleus into the body to supply the wear and tear which the cellular element is continually undergoing. Indeed, I think that some of the specimens shown to the Society, although they may not prove, cannot but strongly suggest that the leucocytes of the blood are in part derived from the nuclei of the columnar epithelium. It is perhaps dan-

Digitized by Google

gerous to argue from morbid specimens that a similar process takes place in health, but yet, to say the least, the evidence afforded by some of the specimens shown is singularly suggestive of the theory propounded of the formation of leucocytes in the columnar epithelium of the intestines.

According to this view, the retiform tissue underlying the epithelium of the intestine is merely the dilated extremity of the intestinal lymph system spread out so as to receive the nuclei from the superjacent epithelium, and convey them along the lymph channels to the circulation.

Let us now revert to the morbid growth. If that form of growth, spreading as a thin layer in the submucous tissue, be examined near the growing margin, the following appearances will be seen if the section be examined under a low power:—The follicles in the superjacent mucous membrane are greatly hypertrophied, so that they have a depth exceeding three or four times their normal condition. This hypertrophy not only affects the follicles as a whole, but the cells forming their epithelial lining have also undergone a relative increase in size. The lumen of the follicles is blocked up with a material having an indistinctly fibrous appearance. This material not only blocks up the follicles, but extends over the surface as a thin layer from one follicle to the other. The nature of this material is not certain. It may be that it is merely the mucous secretion hardened by the reagents used in preparation.

It is nearly always present in adenoid disease, but I have not noticed it in healthy follicles (see Plate XI).

Beneath the mucous membrane, and raising it up from the muscular coat, is the new adenoid growth. It is not, however, in direct continuity with the bases of the superjacent follicles, a considerable interval of retiform tissue filled with lymphoid cells intervening. The growth itself has not the same regularity of structure as when growing unimpeded on the surface. Here and there bands of thickened fibrous tissue can be seen, which represent the connecting links which normally exist between the muscular and mucous coats. These bands seem to have offered obstruction to the advancing growth, which has insinuated itself around or between them, and thus become very irregular.

The muscular coat is always greatly thickened, while in parts its muscular structure has been destroyed or displaced by the adenoid growth, the inter-muscular fibrous bands alone remaining.

Digitized by Google

The method by which the free epithelial border extends, and by which the cavities become filled by secondary growths, should be studied under a high power. The process is as follows:—At one or more points in the border the epithelial cells increase in length, so that they stand out like a small bud beyond the heads of their neighbours (Plate XII).

If such a bud be closely examined it will be seen that the two central cells forming the group act as the leaders of the growing branch. At the same time it is seen that these lengthened cells are in an active state of generation, and appear as if multiplying by cleavage of their extremities (Plate XII). As the cells are progressively formed they bend over and gradually assume a direction at right angles to the line between the primary cells. The line of junction between the walls of the two original cells, which at first was barely visible, becomes more strongly marked, assuming a distinctly fibrous character, and increases in thickness at the expense of the cell contents. After a while small dark cells appear in the very centre of this line, as if they were again separating the bond of union by which the two contiguous cell walls had united to form the original fibre.

Such cells become vacuolated, and the central line becomes the channel. In time a considerable amount of retiform tissue is formed in the centre of the growing leaf. It would appear as if the fibres of this tissue were formed from what is left behind of the walls of the epithelial cells, that is to say, that if the line of junction between any two of the contiguous cells forming the surface of the branch were followed inwards it would be continuous with the fibres of the retiform tissue (fig. 1, Plate XII).

The formation of fibrous tissue has long been a vexed question with physiologists, the prevalent opinion being that it is a formation from connective-tissue corpuscles, and that when found in new growths it is an extension upwards from pre-existing connective tissue. Its formation in health will not be here considered, but in the morbid tissues under consideration I believe that it admits of positive demonstration that it is in great measure derived from the walls of the epithelial cells.

The connection between the fibrous and the cellular elements in any given portion of a morbid growth is not easily traced. The stages of transformation of the cellular element have passed away, leaving a more or less perfectly formed tissue the result of pre-existing conditions.

Digitized by Google

On the margin of a growing tumour, or in the normal tissue, increasing more actively than usual in its immediate neighbourhood, a definite relation can be traced between the cell growth and the fibrous tissue formation; and it is a fair deduction to assume that the fibrous tissue of the deeper portions has been produced by a similar process.

The large and clearly defined columnar cells found lining the acini of adenoid growths in the rectum afford singular facilities for tracing the formation of intercellular fibrous tissue. Almost every writer upon gland structure has assumed the existence of "basement membrane" upon one surface, of which are the epithelial cells, and upon the other a retiform tissue and blood-vessels, the cells being kept in position by the adhesion of their bases to the membrane. Granting for the moment, that a clearly defined line can be seen in some sections lying between the epithelial cells and the subjacent tissue, it does not necessarily follow that such a line is a section of a thin membrane independent of the cells. Such an appearance may be produced by the bases of the cells resting on the same level and being cut on the same place. If a section be made of a portion of a bee's honeycomb an analogous line can be seen running down its centre, marking the boundary between the cells of opposite sides, but yet it clearly admits of proof that such a line belongs to no independant structure, but is produced by the bases of contiguous cells, each of which participates in its formation.

Now, this fibrous line, supposed to mark the existence of "basement membrane," is frequently absent if the section be cut exceedingly fine in a direction parallel with the long axis of the cells, and direct continuity can be traced between the fibres of the retiform tissue and the lines between the epithelial cells.

In Plate XIV, fig. 2, and in fig. 1, Plate XII, such continuity is seen. It remains, however, to be shown that the fibres are formed from the cell wall rather than by an extension upwards of pre-existing fibrous tissue.

If sections be made in such a way as to cut the growing cells across close at their apices, the lines marking the contact of the cells with one another will show us a fine hexagonal network. This hexagonal network must inevitably be the form taken by soft cylinders in contact with each other (fig. 6, Plate XV). If a second section be made, nearer the bases of the cells, the hexagonal network will have assumed a circular form, the lines forming it

Digitized by Google

being considerably thicker than those of the first section, the cavities being correspondingly smaller (fig. 7, Plate XV).

It is impossible to doubt that the fine lines described in the first section are due to the thickened outline of the protoplasm of the cells, for the same appearance is produced in every cellular effusion.

It can, moreover, be shown by vertical sections (fig. 9, Plate XV) that the fine network just described, formed by the apices of the epithelial cells, is in direct continuity with subjacent fibres of the retiform tissue. If, therefore, it be accepted that the epithelial cell wall and terminal fibre of the retiform tissue be one and the same structure, it would be a fair deduction to assume that the deeper part of the same fibres had a similar cellular origin.

In examining various specimens of these cross-sections it will be seen that the original fine hexagonal network does not undergo an equal thickening in all its parts, for it is at the angle of the hexagons that the greatest thickening takes place, and on this account the circular form of the spaces is gradually assumed.

The hexagonal or circular outlines are often very irregular, as the result of unequal pressure from various quarters. In some sections, such a network has an appearance strongly suggesting the idea of a series of stellate cells, anastomosing by their processes. This delusive appearance is occasioned by the processes of the supposed stellate cell, being in fact portions of the circumference of pre-existing cells; the body of the supposed stellate cell being the point of greater thickening, where four or more ordinary secreting cells come into contact (figs. 3 and 8, Plate XV).

I must confess to some difficulty in understanding the existence of stellate cells. I have never seen one isolated, and it is difficult to conceive that, if the fine lines radiating from such cells be in reality hair-like processes, how it comes to pass that a razor should happen exactly to catch many such processes on a plane so precisely parallel as to show them on section anastomosing across from one to the other. On the other hand, if these supposed processes were membranous walls of other cells, they would always show like fibrous lines in whatever direction the section was cut.

Believing the fibrous tissue to be the permanent refuse, so to speak, of pre-existing cells, the appearance it presents in these morbid growths will be briefly described.

Digitized by Google

It is first clearly recognised as an open network at the bases of the epithelial cells under the name of retiform tissue.

If the fibres of this tissue be traced downwards from the surface to the deeper parts, it will be observed that the majority of the fibres gradually converge, and coming in contact form bands of fibrous tissue of greater or less thickness. All the fibres, however, do not thus converge, for occasionally, instead of coming in contact, they form boundaries to well-marked spaces or channels.

Now and again fibres forming a bundle once more spread out in an open network.

Bearing in mind that the examination of this retiform tissue is by thin slices only, it is at once suggested that the appearance presented is not the result of a simple network of fibres, but may be due to a series of convoluted channels, the fine walls of which, on irregular section, give the appearance of a fibrous network. The convolutions of such channels would in great measure account for their not looking likes tubes on section. Occasionally, however, a very beautiful regular appearance is produced in the retiform tissue lying between two adjacent follicles, and instead of a haphazard-looking network, the fibres are arranged in two or three concentric circles, between the lines of which a single layer of lymphoid cells lying in contact with each other can be seen without intervening fibrous bands.

If the retiform tissue is really a series of channels, each channel would appear to commence at the base of a glandular epithelial cell, and such a cell must be regarded as the active living root of the lymph system. It is certain that all the tubes become very irregular, for while some of the channels become obliterated by their opposite walls coming in contact, as if by stretching, others dilate into large lymph spaces.

We will now glance briefly at some of the leading characteristics of the cell elements found in these growths. These cells represent extraordinary variations (see figs. 1, 2, 4, Plate XV).

One of the most prominent features of these morbid cells is their large size, for whereas the normal glandular epithelium is seldom more than $\frac{1}{1000}$th of an inch in length, many of the cells in question are at least ten times as long, some of them of such a size, in fact, as to be almost visible to the naked eye.

On the surface some of these cells resemble tubes $\frac{1}{100}$th of an inch in length, but not wider than the $\frac{1}{800}$th of an inch. The line

Digitized by Google

of contact between the adjacent cells is very clearly marked. In some parts these tubular cells are filled with a faintly staining, homogeneous, granular material, without the slightest trace of nuclei. They appear, in fact, to be barren cells, like pods without peas. In others, again, all the cells are nucleated. Some contain two or three nuclei arranged equidistant apart between the summit and base of the cell. In these circumstances the cell wall bulges opposite the nuclei, with corresponding hour-glass constriction between the nuclei.

The nuclei in these multi-nucleated cells are so arranged that the bulging portion of one cell fits into the hour-glass constriction of its neighbour, so that every alternate nucleus only is on the same level.

Another form of cell, especially in the growing buds, is that the lower or attached half of the cell is narrowed to the finest tube or line, but its outer half forms an oval bulb, which contains the nucleus. Sometimes its condition is reversed, the outer portion of the cell being reduced to the narrow tube, the nuclei being contained in the bulging portion at its base.

The tubular cells just described are met with in the chronic forms of adenoid tumour. In the more rapid growths the cells are of a more spheroidal shape and more irregular, presenting every grade of variation between a lymphoid and an epithelial type.

On a previous page the development of the leaf-like offshoots by the progressive formation of epithelial cells has been described. If, however, we more closely examine the club-like extremities of these growing buds, it will be seen that the young epithelium is first represented by a little projecting mass of protoplasm closely resembling a leucocyte (Plate XII), and that the epithelial type of cell is subsequently assumed by this little mass remaining as a nucleus, but surrounding itself with a material staining more faintly. It thus appears that a young columnar epithelial cell on its first emerging into distinctive life bears a closer resemblance to a simple leucocyte than to its own epithelial parent.

In one of the specimens shown to the Society, the representation of which is figured in Plate XIV, fig. 1, an appearance so clear and remarkable is produced that it may be well to give the history of the specimen.

Although I have some thousands of sections cut from many different specimens, the specimen exhibited, together with two or

Digitized by Google

three imperfect slices from the same growth, are the only specimens in my possession which show, with anything like similar distinctness, the appearances about to be described.

The section in question was taken from a recurrent nodule, or more probably from a portion of growth which had escaped removal at the first operation. A portion of growth, about the size of a small hazel nut, was, at the instant of removal, placed in weak chromic acid solution, being subsequently transferred to spirit and dyed with logwood in the usual manner. It would seem, therefore, that the exceptional clearness of the specimen was possibly due to its rapid transfer to the hardening fluid.

In this specimen the nucleus-like bodies towards the base of the cylindrical epithelial cells forming the surface of the hypertrophied mucous membrane are remarkably clearly defined owing to the intensity by which they have taken the staining. In the subepithelial retiform tissue a considerable number of lymphoid cells are similarly darkly stained. In form, size, and the extent to which they have taken the dye, there is no perceptible difference between the bodies (nuclei?) within the epithelial cells and the bodies (leucocytes?) within the retiform tissue.

It is scarcely possible not to believe but that they are identical the one with the other. The difference of situation alone remains, and even this in portions is no longer noticeable, for here and there the bodies can be seen so close upon the boundary line between the epithelial and the retiform tissue, that it would not be possible positively to state whether the body should still be regarded as a nucleus within the epithelium or as a lymphoid cell in the retiform tissue.

If it be conceded that these bodies are identical, it would still remain a question as to whether their movement was in the direction of leucocytes entering the epithelium from below, or whether they were nuclei passing from the epithelium to become lymphoid cells in the retiform tissue.

Putting aside for the moment the question of direction, we seem now to be in possession of some evidence to prove that a lymphoid-looking cell can become epithelial, and also that an epithelial cell can produce a simple lymphoid-looking body, and that the one is an immature embryonic form of the other.

If it be conceded that a lymphoid cell can gradually develop into an epithelial type, it would appear that the latter is in a higher

Digitized by Google

stage of organisation than the former, and it would, therefore, be as easy to assume that the epithelium increased by multiplication as that the lymphoid bodies could do so.

Let us pause for the moment once more fairly to understand the position of the question under consideration.

It is whether a proliferating epithelial cell directly produces a complete cell similar to itself, or whether the offspring first produced by an epithelial cell is not rather a simple lymphoid body which subsequently surrounds itself with protoplasm, gradually assuming the type of the perfect cell from which it sprang.

If it be admitted that the embryo epithelium is a simple lymphoid body, the next question which arises is whether this embryonic body can migrate from its place of birth and become identical with the leucocytes of the retiform tissue and blood, for if so, it might afford an explanation as to the vexed question of the origin of leucocytes, as they would in great measure be derived from the columnar epithelium in the intestinal tract.

I should be unwilling in a paper of this description to destroy the value of the actual facts relative to the development of cancer in the rectum by mixing them up with vague and unproved theories, but at the same time it may be pardonable to recapitulate a few of the facts which would appear to lend colour to the view suggested as to the relation between the leucocytes and the epithelium. I would wish it therefore to be clearly understood that the specimens before me merely suggest the view in question without in any way assuming that they admit of such an interpretation only.

If the apex of a growing epithelial bud be examined, the young cells which first appear have no visible features by which they can be distinguished from the leucocytes or granulating tissue. This gradual conversion of the lymphoid to the epithelial type can also be well studied when these morbid growths are extending into adipose tissue. Plate XVI is a section of some fatty tissue lying external to the rectal wall, into which the new growth is gradually penetrating. In some portions of the specimen the fat cells are normal, in others they are completely replaced by the growth.

The first appearance of morbid infection consists in the infiltration of a single layer of leucocytes between the walls of the individual fat cells in such a way that they (the fat cells) become com-

Digitized by Google

pletely surrounded by a one-celled layer of leucocytes. It can next be observed that these leucocytes, surrounding themselves with protoplasm, gradually increase in size, and in so doing, compress the fat cells between whose walls they lie, so that after a time the outline of the original fat cell is represented by a ring of new growth, a small cavity only remaining to mark the spot of its existence. This, too, in its turn, often becomes completely obliterated by its walls being compressed into apposition, so that all that remains of what once was the cavity of a fat cell is a double line of fine fibrous tissue, the compressed walls of the original cell.

In the meanwhile the invading growth, which was primarily represented by a layer of leucocytes, is shown by large epithelial cells into which the leucocytes have grown, arranged in a circular manner (see Plate XVI). It is upon this evidence and that of the growing epithelial buds that the possibility of the development of the lymphoid into epithelial cells is based.

If we now refer to the specimen described on page 102, and figured in Plate XIV, and consider what evidence can be adduced to establish that the lymphoid bodies are rather travelling from than towards the epithelium, it must be remembered that the argument is that a lymphoid cell can develop into an epithelial cell and that an epithelial cell can produce a lymphoid cell without itself reverting to a similar type.

If the bodies were travelling into the epithelium they must be disposed of in one of the following ways. They must either accumulate within the epithelial cells, or pass out of the free extremity, or be dissolved, and disappear within the original protoplasm of the epithelium, or develop into an epithelial cell, so that they can be no longer separately recognised. That they neither accumulate nor pass out of the free extremities can be proved, nor does it appear that they are supplying the place of epithelium that has been shed, for the line remains unbroken. It is not of course possible to prove that they do not disappear by absorption. On the other hand, there is some strong indirect evidence that these lymphoid bodies have been derived from the epithelium, for it is in their collection immediately beneath the hypertrophied epithelium that the first evidence of the tumour formation is evinced, and, as will be subsequently shown, they invariably form the advanced guard of extending adenoid tissue. At first sight it must be admitted that this accumulation of leucocytes on the outskirts of

Digitized by Google

the growing tumour would as easily admit of the interpretation that they had come from distant parts, as that they had been developed from the local cells.

Dr. Moxon, and other observers of high repute, state that not infrequently they have observed in nodules in the liver secondary to rectal cancer, not merely columnar epithelial cells, but a structure actually identical with Lieberkühn's follicles.

The deduction to be drawn from these secondary deposits is that they grow from cells originally derived from the rectum. Now, it is scarcely possible to conceive that the large columnar-shaped epithelial cell of the rectum can be transmitted, in the bulk of its complete form, through the intricate lymph paths between the rectum and the liver; but no such mechanical difficulty lies in the path of the smaller lymphoid cell, which when arrested in the liver grows to the likeness of its epithelial parent.

Already on page 97 the method has been described by which the tumour extends on its free surface, and it has been shown that it does so by a progressive development of its epithelial border.

The view is commonly held that these growths advance into the deeper tissues by a similar process, and that it is by a downward prolongation and branching of the follicular crypts that the epithelial growths are formed in the deeper parts.

That this is one method by which the tumour extends into the deeper portions I admit, but that it is the only, or even the commoner, method of extension is doubtful. Until quite recently, I have never been able directly to trace their downward extension, but a specimen has recently come under observation in which something like direct continuity can be traced between the surface follicles of the mucous membrane and those in the body of the tumour. As a rule, however, careful search fails to show any such connection.

Notwithstanding the inability to trace this downward growth from the surface, such continuity might have existed, but yet remain undiscovered in the sections. It is possible that such a downward dipping might have begun at a single point and then have spread horizontally like an inverted mushroom. In such a case the connection could not be established save in a fortunate section through the connecting pedicle itself. Seeing the destructive process which occurs in the older portions of these growths,

Digitized by Google

such a pedicle would probably have disappeared before the specimen came under observation.

It is certain that these growths must have other means of development in addition to direct extension by continuity of their epithelial element, otherwise the development of morbid adenoid tissue in isolated patches on the peritoneal coat of the bowel, or in the internal organs, cannot be accounted for. It admits of clear illustration that these separate points of disease are not directly connected by epithelial tissue with the primary growth.

Again, when we come to examine under the microscope the line of demarcation between the morbid growth and the tissue which it is invading, we generally fail to find a clear epithelial border marking the boundary. In the more chronic growths a line of fairly formed epithelium may occasionally be seen marking the boundary, but this is not generally the case. For if a section be cut through the new growth, extending into the healthy submucous tissue, it will be seen that there is a kind of no man's land intervening between the growth and the normal tissue. This is infiltrated with a cloud of cells.

The cells forming the extreme border of this infiltration differ in no way from ordinary lymphoid cells, but as they are traced towards the growth they are seen gradually to become larger, and to assume a distinctly epithelial type. These in their turn gradually assume the appearance of an ill-marked adenoid tissue, which in time assumes a more definite type.

In short, the appearances suggest that the growth increases by the gradual conversion of the lymphoid cells on its border into adenoid tissue, and that the source from which these lymphoid cells are derived is the epithelium of the growing tumour, a portion of them gradually developing into the likeness of their parents cause the extension of the growth.

The actual structure of these morbid growths in the rectum has now been studied at some length. It has been pointed out, notwithstanding the multiplicity of names applied to them, there is after all nothing very obscure in their structure. It has been conclusively proved that at least in the majority of instances they consist of a more or less perfect reproduction of the normal tissue of the part, and what we have been examining therefore must be regarded rather as the product of some morbid influence than the disease itself.

Digitized by Google

In searching for a cause to account for this unnatural cell accumulation, it may be well briefly to consider what causes are already known to produce such a result.

Increased blood supply to a part acting either directly or through the influence of the nervous system is such a cause. Local mechanical irritation is another. Probably, however, this acts through the cause already cited, by producing an increased blood supply. Lymphatic obstruction is by some considered the cause of hypertrophy.

Such a group of causes is mechanical. We now come to another group, the effects of a specific irritation producing cell production.

Minute particles of vaccine lymph will produce such a result. Here the manifestation is local, so far as the cell collection is concerned. In the same category may be included the poison in pyæmia, which not only produces the primary abscess (cell formation), but can pass along the lymph and blood channels without losing its potency, causing secondary formations wheresoever arrested. Other instances might be cited, but sufficient have been mentioned for the purpose of illustration. Such causes act more or less acutely, and pus (the cellular product of such irritation) is formed too quickly to organise itself into a fixed tissue.

It is like a quickly collected, unorganised mob, the individuals of which act independently. In the haste of their collection the commissariat has been neglected. The capillary blood-vessels, which should supply the lymphoid cells with food, have had no time for development. The collected cells are consequently short lived and soon become little more than dead refuse. So far we have been considering the result of quickly acting specific poisons. In searching for an illustration of some specific poison, which both locally and secondarily will produce a cell formation, having sufficient vitality and blood supply to allow of its formation into cohesive tissue, we have an example in syphilis.

In descending the scale of creation we find that the vegetable kingdom rich in examples of cell formation due to specific irritation. Those who have studied the formation of galls, and the suggestive references made on the subject by Sir James Paget, will know how these bodies are produced by such irritants.

Here we have a tumour formation, the individual cells of which are derived from the bark or leaf on which it is placed, and can be easily identified with the cells of the neighbouring normal tissue;

Digitized by Google

but yet it is established beyond doubt that this extraordinary behaviour of a portion of a tree is the result of a specific irritation from without.

Now, in considering whether any of these causes bear upon the question of malignant tumours, the mechanical irritation and obstruction will first come under consideration. It has frequently been sought to prove that mechanical irritation is one of the sources of cancer, but as yet with entirely negative results.

Patients with cancerous ulceration on the lips or tongue are invariably questioned as to smoking, or as to the existence of broken teeth. Affirmative replies are considered evidence of a connection between the irritatives and the morbid growths. If these relations be regarded as cause and effect, why should the cause be at work in 1000 cases, the effect following in one only? Instead, therefore, of such irritations being the cause of morbid growths, we have overwhelming evidence that they are not so save in the rarest instances.

Without denying the connection that may occasionally exist between injuries and morbid growth, the determining cause must lie in some factor not yet considered. It has been attempted to be shown that such a factor lies in what has been described with unscientific vagueness as a constitutional predisposition, so that instead of the irritated part producing a simple hypertrophy or abscess, a malignant cellular growth results.

Inquiry was for some time satisfied in regarding "this predisposition" as something inherited. The doctrine of such inheritance rested on the supposed fact that cancer was peculiar to certain families, and that the peculiarities of the constitution were transmitted from parent to child in the same way as the tendency to red hair or blue eyes.

This doctrine of inheritance need no longer trouble us, for the whole teaching is founded on a basis that vanishes before critical inquiry. The cause of cancer is, and may be long, shrouded in mystery; but yet the one thing certain, admitting of positive proof, is, that a parent suffering from cancer in no way increases the liability of the offspring to suffer from the same disease.[1]

Simple mechanical lymphatic obstruction might account for the formation of a local tumour, the cells formed in a given part being

[1] 'St. Bartholomew's Hosp. Reports,' vol. xiv, "Relative Frequency of Cancer found in the Direct Offspring of a Cancerous or Non-cancerous Parent," p. 287.

Digitized by Google

unable to pass away, but such obstruction must either lie between the tumour and the gland or beyond the gland. In the former case the gland could never become diseased, in the latter it should be the primary seat, both of which conditions are contrary to fact.

Now let us consider the causes of specific irritation which produce cellular collection.

The effects of such irritation are various, but, speaking generally, the same irritation always produces within certain limits the same effects. The irritation of small-pox, measles, and syphilis for instance, all produce their characteristic cellular collections, each collection, though formed from the cellular element in our tissues, being distinctive and of a nature suitable for propagation or ripening the particular seed originally sown.

The manner by which the primary poison or its offspring has been conveyed from the original seat of disease is not known, save that it follows the course of the lymph or blood currents. In the instances mentioned it would appear as if it were the actual seed itself which was conveyed to distant parts, causing the cell proliferation from the particular tissue in which it became arrested.

When we come to consider cancer and its secondary deposits, we see that there is a dissimilarity in its course to that of the diseases mentioned in the last paragraph. It has been already shown in an earlier part of this communication, that the primary tumour in malignant disease is built up of cells similar to that found in the normal tissue in which the tumour is placed.

Now, if it were the particular poison alone that was transmitted, we should expect that such particles producing the irritation wheresoever arrested would cause a cell proliferation after the manner of the particular structure in which they sojourn, thus producing a local hypoplasia of the liver, spleen, or kidney forming their home; but, in many instances this is not the case, and the secondary tumour produces a structure the elements of which are composed of cells similar to those found in the site of the original growth, rather than of cells resembling the tissue in which it happens at the moment to be residing.

The deduction from this phenomenon is that the actual cells themselves are diseased, and carry their morbid condition with them to their new situation, and being unable from their altered form, due to their diseased condition, to pass the interstices of the tissue,

Digitized by Google

collect and form tumours, while at the same time it is more than probable that they may infect the cell elements of the part in which they are arrested. Let us for a moment compare this theory with the interpretation of facts previously suggested in the study of primary rectal growth. Lymphoid cells, offspring of the glandular epithelium of the intestine, are born with the disease. The function of such embryonic cells, if healthy, would have been to have passed through the lymph channels into the blood, and there to have circulated until required by some particular portion needing their assistance for repair, but owing to their alteration by disease they not only have great difficulty in passing along the lymph paths, but when they succeed in doing so have a tendency again to become arrested in the fine structures of the glands. In the first instance their undue sojourn in the lymphatics in the immediate neighbourhood of their birthplace gives them time to develop into the more perfect type of cell, or even to a tissue similar to that formed by their parents, and the same development taking place when arrested in distal parts causes the formation of secondary growths.

The exact nature of the irritant infecting the cells is at present unknown, but seeing the increased prevalence of malignant disease in certain districts, it would appear to be from some cause originating external to the body, and to have a special affinity for certain structures, in the same way as particular galls only infect the leaves, bark, or root of the plant, according to their special variety. The undoubted starting-point of malignant growths, especially in glandular structures, can from time to time be directly traced to some blow or injury, yet, as a rule, thousands of such blows or injuries may occur without being followed by any such result. But we can study an almost analogous process in the acute necrosis affecting the bones of children.

Hundreds of slight contusions of the periosteum may occur without producing acute pyæmic necrosis, but yet the starting-point of this grave disease can at times be clearly traced to such an accident. If the product of one of these acute abscesses be examined it will be found crowded with organisms, notwithstanding that no communication with the air previously existed.

Such a phenomenon can, I think, only be explained upon one hypothesis. That such organisms, by absorption, find their way into the blood, and whilst still circulating within the vessels are

Digitized by Google

incapable of multiplying or doing harm; but when they become stationary by extravasation into the tissues as the result of a blow they immediately become active, and produce the phenomenon of sub-periosteal abscess or pyæmia.

The fact that an organism in one part of the body may be perfectly harmless, while in another it produces the gravest pathological results, has been proved. As an example, the facts recently narrated by Vulpian to the French Academy may be mentioned; these experiments showed that a rabbit, when injected with saliva from a healthy individual, died within two days of inoculation, the blood of the rabbit so dying being crowded with organisms.

In cancer no parasite has been discovered by the microscope, but this is no evidence whatever of its non-existence, for it must be borne in mind that it is only within the last few years that even the larger microscopic organisms have been detected, and some of these would never have been suspected had not their movements attracted attention in recent specimens. The myriads of minute specks of granular material seen by the microscope when examining a section of malignant disease might contain any amount of organisms which, at present, are incapable of recognition.

If cancer could be propagated from one person to another it would support the view of its cause lying in some specific contagion. Hitherto, all direct experiments with a view to inoculation have failed; but yet when we read the accounts of these experiments, they merely prove that when a portion of a tumour, or of its secretion, is inserted *beneath* the skin of an animal the results are negative. If portions of the disease could be kept sufficiently long in contact with an *epithelial* structure, there is reason to suppose that inoculation would take place. Such an experiment is occasionally carried out by nature. At the present time there is, at St. Bartholomew's Hospital, a woman who has a large cancerous ulceration involving the breast and skin of the thorax. For the last few months, being unable to put on any dress, she has kept her left arm bent at right angles in constant contact with the disease. The result of this contact has been that the skin in the neighbourhood of the elbow has become the seat of a cancerous ulcer several inches in diameter. Similar cases of auto-inoculations have been described in the 'Transactions' of the Society.

The fact that when sound epithelial tissue is kept in constant contact with malignant disease it becomes infected lends no small

Digitized by Google

support to the view that the poison of cancer may yet prove to be of a parasitic nature. *April 19th*, 1881.

---

5. *Cystic disease of the liver, and of both kidneys.*

By P. H. Pye-Smith, M.D.

(With Plate XVII.)

The organs exhibited were taken from the body of a man who died under my care in Guy's Hospital last November. He was fifty-three years old.

He had by his own account been a hard drinker for many years, and had several times been under treatment for bronchitis. He died of chronic interstitial pneumonia with great thickening of the pleura. This ended in pulmonary gangrene and secondary lobular pneumonia. There was no grey tubercle, and no caseous material in the lungs, bronchial glands, or any other organ.

During life the symptoms pointed to chronic non-tubercular disease of the lungs. The liver was not enlarged, and no abdominal tumour was felt. There was never a trace of jaundice, and up to the last there was neither dropsy nor uræmic symptoms. The urine was abundant, pale, and occasionally showed the presence of a little albumen. The sp. gr. was usually below normal, about 1015, and the pulse indicated increase of arterial tension, so that I suspected that the kidneys would be found granular.

The liver was about the normal size. It was somewhat puckered and deformed, and several cysts were visible on its upper surface. On section, many more were discovered; but perhaps three fourths of the hepatic substance was free from disease, and the gall bladder contained normal bile. Most of the cysts varied from microscopic dimensions to the size of a pea or a bean. One only was as large as a pigeon's egg. They were filled with clear, thin, slightly albuminous liquid, free from the least tinge of bile. No connexion with the ducts could be discovered.

The kidneys were greatly enlarged, so that the two together

Digitized by Google

Digitized by Google

Fig. I.

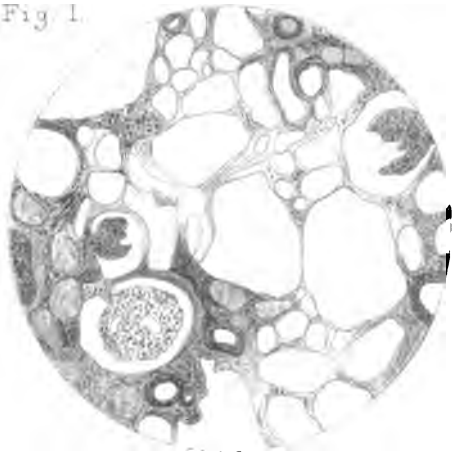

Fig. II.

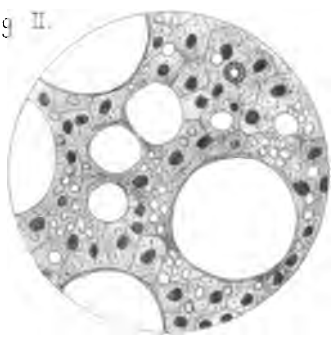

Fig. III.

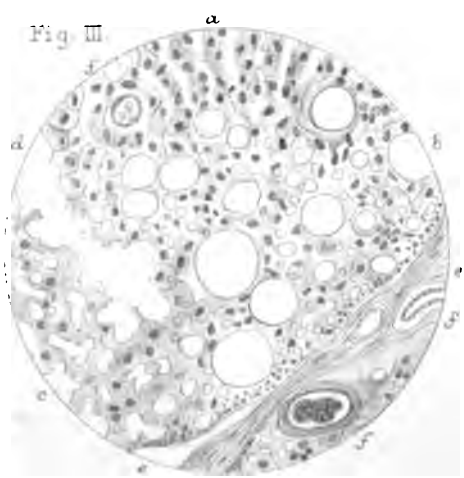

Digitized by Google

DESCRIPTION OF PLATE XVII.

Illustrating cases by Dr. Pye Smith. (From drawings by himself.)

FIG. 1.—Section of cystic kidney, low power.

Three Malpighian bodies are seen (*a*), and several uriniferous tubules, of which only one has preserved its epithelium (*b*). Blood-vessels (*c*) were few in number. The section shows the irregular cysts described. (Smith and Beck, ½ in.)

Fig. 2 A.—Section of cystic liver.

Blood-vessels (*a*) and ducts (*b*) are seen, with a portal canal in the S.E. of the field. In the N. the columns of a lobule are represented unaffected, except from slight shrinking in the preparation. There are numerous large, and still more numerous small, cysts. Towards the W. of the field these have joined to form an irregular cystic cavity (*c*) and several smaller ones.

The transition from normal to cystic hepatic tissue was more gradual than is here shown; the upper fourth of the section was really four times as far from the rest as is here represented. (Smith and Beck, ½ in.)

FIG. 2 B.—Taken from the same slide as Fig 2 A (more highly magnified). Seven of the larger cysts and numerous minute cysts are shown, the latter beginning as vacuoles in the hepatic cells. The protoplasm is clear or very firmly granular. The smallest vacuoles appear in some cases through a thin layer of cell-substance; in others they are, like the larger ones, uncovered. (Hartnack, No. 9.)

Digitized by Google

Digitized by Google

weighed 64 oz.; they were about equal in size and preserved their natural shape. The whole surface of each was covered with transparent thin-walled cysts, like those of the liver, but much more abundant, and more uniform both in distribution and in size. On section, the whole gland was found to be converted into similar cysts. At first it appeared as if no healthy structure remained, but careful scrutiny showed several normal spots, especially in the medullary part of the pyramids, and in the interpyramidal projections of the cortical substance.

On microscopical examination, the liver showed, in the neighbourhood of the cysts which were visible to the naked eye, a multitude of smaller ones, of various sizes, down to some which were not larger than the nuclei of the liver cells. Looking to these, the smaller microscopic cysts, it was very plain that they began as vacuoles in the protoplasm of the secreting epithelium (see fig. 2). Sometimes a single vacuole was seen in a liver cell, sometimes three or four, and sometimes they were so numerous that the nucleus was displaced, or had disappeared, leaving the cell completely riddled with these cavities. They were unlike the ordinary vacuoles containing oil, which are seen in physiologically and pathologically fatty livers; and this unlikeness was confirmed by a comparison of sections from the fresh frozen liver with those mounted in balsam, as well as with others in glycerine. Where the vacuoles increased further in size, the cell was destroyed and multilocular cavities were formed, both small and large, corresponding to the size of the cysts which produced them.

It was suggested at the meeting, where some of the slides were shown, that the abundance of nuclei pointed to an interstitial inflammatory process as the origin of the cystic degeneration.

Though not accepting the conclusion, I thought that there was some concomitant interstitial hepatitis, which indeed the habits of the patient made likely enough. On more careful examination, however, with additional sections and higher powers, I found that, though there was a certain excess of nuclei and leucocytes to be found in some parts of the liver (probably a stage of cirrhosis), yet that they were less numerous as the cystic portions were approached. In the thoroughly microcystic regions, as seen in figs. 2 and 3, the septa between the cysts are formed entirely by hepatic cells; and in some parts, where the tissue was still more

Digitized by Google

riddled, this attenuation of the epithelial cells, which only held together by slender processes, was even more marked than in 3. The numerous nuclei resembled in size and shape those of liver cells, not of leucocytes or of connective tissue; and in the best sections it was possible to count them individually, and to assign each one either to a well-defined cell, or where the cells were not obviously distinct, to a cell-territory of corresponding size. The protoplasm of the cells was remarkably free from either fatty or pigmental degeneration.

The microscopical examination of the kidneys showed, on the whole, a close agreement with the ordinary histology of cystic degeneration of these organs, as will be seen from fig. 1. The cysts were, for the most part, naked, and appeared to be formed by dilatation of the tubules. The Malpighian bodies seemed to be only secondarily affected. There was no trace of vacuolation in the epithelial cells of either the convoluted or the straight tubules which remained. In spite of the extensive and advanced cystic degeneration, a much greater aggregate of renal tissue was found remaining in numberless small patches than, on making the first section, seemed possible.

No other abnormality was found in the body.

Remarks.—Cysts in the liver, excluding, of course, hydatids, are rare. Most of the cases described by Cruveilhier, Davaine, Buhl, Budd, and earlier writers, were regarded, and probably correctly, as due to dilatation of the bile-ducts, and in several cases this was proved by their contents being tinged with bile-pigment, by their direct communication with the duct being traced, or by the presence of an obvious cause of obstruction. So Rokitansky: "Cysts are rare. They are often clearly the result of dilatations of the biliary passages becoming separated off" ('Path. Anat.,' Bd. ii, S. 263).

Cysts, however, with contents free from a trace of biliary matter are occasionally found in the liver. In Frerichs's treatise we read (vol. ii, p. 223), "Simple serous cysts, with clear watery contents, are not of frequent occurrence in the liver. I have repeatedly, however, observed isolated cysts in the organ varying in size from a pea to a bean."

Sir Benjamin Brodie described, in 1846, large serous cysts of the liver, with no trace of hydatid structure, occurring singly, and sometimes needing surgical interference ('Lectures,' p. 105).

In 1865, while working in the Pathological Institute at Berlin, I

Digitized by Google

examined a liver taken from a man of twenty-four, who died from hepatic abscess of probably traumatic origin, and subsequent pericarditis and pleurisy. Just at the attachment of the falciform ligament was a cyst the size of a marble, with colourless, mucus-like contents. Under the microscope it showed epithelial scales, leucocytes, and large granular corpuscles. Prof. Virchow decided this to be due to obstruction and dilatation of a bile-duct, and to be in all probability congenital. The manner in which biliary cysts from local obstruction may, by atrophy of the surrounding parenchyma, gradually approach the surface and acquire colourless contents, is described by him in his great work on tumours.[1]

Single cysts of the kidney and micro-cystic degeneration, as a concomitant or result of chronic granular degeneration, are common enough, and the latter form of disease has been the subject of numerous investigations and much controversy. But both kidneys being enormously increased in size by conversion into innumerable cysts of various sizes is a rare condition, and most cases been found in new-born infants.

In 1855 Prof. Virchow published a paper, read before the Medical Society of Würzburg the preceding November, "Ueber Congenitale Nierenwassersucht,"[2] in which he described two recent cases of congenital cystic degeneration of both kidneys, besides two museum specimens of the same condition. He points out their frequent association with horse-shoe kidney, cleft palate, hydrocephalus, and malformations of the urino-genital passages. He refers the fatality of these cases not to uræmia, as Förster had suggested, but to mechanical interference with respiration after the birth of the child, to which, indeed, the enormous size of the abdomen often proves an insurmountable obstacle.

Virchow agrees with Rokitansky (loc. cit., p. 339, fig. 39), Beckmann ('Virchow's Archiv,' ix, p. 221), and Dr. Geo. Johnson in attributing the cysts of this form of renal disease to dilatation, by obstruction, of the capsules of Bowman or of the tubules themselves.

Similar cases of congenital cystic degeneration of both kidneys had been previously recorded by Rayer and by Förster.

The first case recorded, so far as I am aware, which resembles mine, is one described by Dr. Bristowe in the seventh volume of

[1] 'Krankhafte Geschwülste,' i, pp. 256—8.

[2] 'Gesammelte Abhandlungen,' p. 864. See also other cases discussed on p. 839.

Digitized by Google

these 'Reports' (1856) as "Cystic Disease of the Liver associated with similar Disease of the Kidneys." The liver weighed more than four pounds, and contained numerous cysts varying in size "from mere points to the size of a pigeon's egg." The kidneys were also much enlarged and full of cysts, but instead of being all full of clear serous liquid, as in my case, several contained red, thick, or buff-coloured contents. In all other respects the description agrees closely with what I observed. Dr. Bristowe's patient was a man fifty-three years old, who had passed blood in his urine. The heart was hypertrophied, without valvular disease.

In the same session of our Society Dr. Wilks exhibited a museum preparation of cystic disease of the liver and right kidney,[1] as a specimen of the same remarkable condition ('Path. Trans.,' vol. vii, p. 235).

A second case was recorded in our tenth volume, also by Dr. Bristowe (p. 174). The age of this patient is not given, but she was a married woman with two children, and had been long ill with cough and dyspnœa, but without renal symptoms. There was found evidence of chronic bronchitis and a circumscribed empyema on both sides. The liver contained vast numbers of minute cysts, mostly filled with "a reddish-brown waxy material." The two kidneys weighed 17¾ oz. They were thickly studded with cysts, large and small, with serous, or occasionally milky, contents.

Rindfleisch records a single case of the same association of the liver and kidneys in cystic degeneration,[2] and argues in favour of the hepatic cysts being really an extreme form of cysto-sarcoma beginning in the interlobular hepatic ducts. He also refers to a case observed by Rokitansky, but does not give a reference, and I am not able to find where it is recorded.

Prof. Frerichs, in his 'Diseases of the Liver' (vol. ii, p. 223 of Dr. Murchison's translation), quoted Bristowe's and Wilks' cases and added a brief record of a case of his own at Breslau. In the liver of an old woman who died of pneumonia and pericarditis were found, in the neighbourhood of the suspensory ligament, "numerous cysts from the size of a pea to that of a bean, with clear watery contents. Similar cysts were observed in greater numbers in the cortical sub-

[1] Now Nos. 1909[40] and 2047[75] in the Pathological department of the Guy's Hospital Museum.

[2] 'Lehrb. d. path. Gewebelehre,' p. 402.

Digitized by Google

stance of the left kidney, which was likewise covered with numerous scar-like depressions. There was no cyst in the right kidney."

The question arises whether this remarkable condition of liver and kidneys is congenital or acquired. That a similar condition may be congenital, at least in the case of the kidneys, is undoubted, and the singular latency of the disease, its symmetry, and extent seemed, at first sight, to point to the same conclusion.

But, in the first place, the very success with which Virchow establishes the occurrence of this cystic degeneration of the kidneys in the fœtus proves that the morbid conditions before and after birth are essentially the same. In his cases the fœtus suffered from the cystic degeneration already well known in the adult. In mine the adult suffered from the same disease as the fœtus.

Again, Virchow proved that in his cases the condition was not a mere malformation, but the result of intra-uterine disease. Then in mine also it was the result of disease, and the only question is whether this began before or after birth.

Moreover, in Dr. Bristowe's first case there was clear evidence of recent and active disease, and in the two reported by Dr. Wilks and by Prof. Frerichs, the curious fact of the only one kidney being affected, beside the liver, points to the probability of the morbid process being still in course of development at the time of death.

There would be no difficulty in understanding how even a considerable number of cysts in the liver should not give evidence of their presence, while the greater part of the organ remained unaffected, but it would certainly be strange if the renal functions could have been carried on for fifty years by organs which had been so extensively destroyed as the kidneys were in my case.

In this instance, moreover, we have clinical evidence of chronic renal disease. The abundant urine, of low specific gravity, with a trace of albumen associated with high arterial tension, pointed to ordinary interstitial nephritis, which was going on along with an analogous chronic process in the lungs.

Lastly, the microscopical examination, although it shows no recent and active inflammatory process in the kidneys, proves that this extreme and remarkable form of cystic degeneration is histologically the same as the ordinary micro-cystic form of kidney, associated with the later stages of chronic Bright's disease. Although other theories of this condition have been held by Mr. Simon, by Professor Rindfleisch, and other pathologists, it appears to

Digitized by Google

me that the weight of evidence as well of authority, is in favour of the multiple cysts of the kidney being "retention cysts," produced by constriction of the efferent tubes and consequent dilatation either of the Malpighian capsules or of the cortical tubules.

The question still remains whether the cystic degeneration of the liver is part of a common disease or whether it has arisen by a different morbid process from that affecting the kidneys.

Here, again, at first sight I was inclined to connect the two organs in their pathology. But the histological evidence is decidedly against this view. As a rare result of local or general interstitial hepatitis, retention-cysts are no doubt found in the liver. Such cases are recorded by Budd, Virchow, Frerichs, Wilks and Moxon, and other systematic writers. But as Dr. Wilks remarks, such cases are very different from those of cysts which contain clear fluid without a trace of bile, which do not communicate with the ducts of the liver, and which occur in the complete absence of contractions, cicatrices, or any other cause of constriction. There appears to be no doubt from the observations of Naunyn and of Rindfleisch, that the liver is occasionally the seat of cystosarcomata, and that the cystic element may, as in the breast, greatly predominate. But, in the present case, careful and repeated examination of sections of the diseased liver made plain to me (as the figures sent herewith will, I hope, make plain to others) that the cystic degeneration is neither due to obstruction of ducts nor to new growths, but to a process of vacuolation of the secreting cells themselves.

I am glad to find that this result confirms the view taken of a similar case by one of the most eminent contributors to the histology of the liver. Dr. Bristowe's first specimen of cystic liver was referred by this Society to Dr. Lionel Beale. He injected the ducts with Prussian blue, and ascertained that there was no natural communication between the cysts and ducts; so that "the formation of the cyst in this instance does not depend upon closure of a part of a tube and the subsequent accumulation of the secretion beyond this point." He also says, "I am led to conclude that the formation of cysts commenced within the lobule itself and not in the interlobular fissures: and I think it probable that the fresh change which took place consisted in an alteration of the secreting cell (liver cells)."

If, as I believe, this case shows that a different histological process produces the cystic condition in the liver and in the kidney,

Digitized by Google

we must adopt Dr. Bristowe's original supposition that the co-existence of the same form of diseases in the liver and kidneys is merely a coincidence.

We cannot suppose "a tendency to the formation of cysts," seeing that cysts are always secondary products. Tendency to the production of interstitial contraction which will occlude the natural ducts of a gland is one thing, tendency to the growth of cysto-sarcomata is another, and tendency to vacuolation of secreting cells is a third.

In the present case we have, I believe, an example of the first process in the kidneys, and of the last in the liver; and I look upon the two as independent in origin, and both as having begun long after adult life. *March 15th*, 1881.

---

6. *Chronic dysentery and abscess of the liver, opened first by aspiration and then by direct incision, with antiseptic precautions. Death on the sixth day.*

By Sir Joseph Fayrer, M.D.

Major J. G—, æt. 41, of the M.S.C., was invalided from Afghanistan, where he had served more than a year during the war, by a medical certificate, dated 25th October, 1880, and recommended to return to Europe for the period of eighteen months, in consequence of his having suffered from "diarrhœa accompanied by low fever, dependent on a congested state of the liver, aggravated by exposure whilst on service." It is stated that he had two attacks of dysentery during the last year.

Major G— arrived at Southampton on the 15th December, 1880, and on the 18th December was conveyed to London.

On his arrival, Mr. Adams found that the patient had borne the journey to London fairly well, and had the advantage of being accompanied by his brother-in-law.

The patient did not complain of pain in the region of the liver, or of any local pain, but the difficulty and distress in breathing were very great. Dulness on percussion existed over the whole of

Digitized by Google

the right side of the chest, and no respiratory sounds could be heard, even towards the apex of the right lung.

A large abscess of the liver was evidently pointing on the outer side of the chest, between the ninth and tenth ribs on the right side, where fluctuation was distinct, but the skin pale. In this situation the abscess had been punctured by the aspirator a week ago, and 16 oz. of matter drawn off.

Sir Joseph Fayrer advised that the abscess should be opened by direct incision, under antiseptic precautions, without delay, and in this opinion Dr. Dickinson also concurred.

Sunday, the 19th December.—Mr. Adams performed the operation at 10 a.m., opening the abscess by an incision an inch in length, between the ninth and tenth ribs, a little behind their cartilages. A drainage-tube of large size, and about six inches in length, was introduced, and 20 oz. of dark coloured, thick, clotted matter, with what appeared like some fragments of disintegrated liver structure, such as could not have passed through a small aspirator tube, were removed.

The carbolic spray and Lister's antiseptic dressing were employed, the chest and abdomen being wrapped round with a wide and long gauze sheeting, held in position by an india rubber bandage.

The upper border and internal surface of the tenth rib was denuded of its periosteum and roughened, evidently in a carious condition. This would be explained by the length of time the abscess had been forming, which Major G— said was about two months and a half. Sir Joseph Fayrer, Dr. Dickinson, and Mr. Spencer Watson were present at the operation.

The immediate relief afforded by the operation was very great. The respiration became much easier, and with rest and nourishment the patient improved. The evening temperature fell to 99·2°, it had been 103°.

Monday, 20th, 9.30 a.m.—The patient going on well; morning temperature 99·6°, evening 99·7°; nourishment taken freely and very little stimulant. Bowels moved once.

Tuesday, 21st, 9.30 a.m.—The patient going on well, slept pretty well, a draught with gr. ¼ of morphia had been given. Morning temperature 99·2°, evening 99·9°.

Wednesday, 22nd, 9.30 a.m.—The patient going on well. The draught was repeated last night. He slept pretty well, and took

Digitized by Google

plenty of nourishment. Morning temperature 99·7°, evening 100·7°, pulse rather quick and feeble. The antiseptic dressings were removed and reapplied.

Thursday, 23rd, 9.30 a.m.—The patient about the same; has not improved. He says he feels weaker. Breathing rather short and hurried, and at times he has some difficulty in swallowing. Morning temperature 99·4°, evening 101·1°. During the day the bowels acted three times and were relaxed, but not amounting to diarrhœa. An astringent draught was ordered with a little port wine and brandy. Nourishment was taken freely. The night draught to be repeated. Pulse rather quick and feeble.

Friday, 24th, 9.30 a.m.—The patient appears to be rather more feeble. Has slept pretty well and taken nourishment freely. Morning temperature 100·4°, evening 99·7°. Breathing still short and quick; pulse feeble, and respiration 110. The antiseptic dressings were again removed and replaced. The long tube was removed and a short one of smaller diameter was introduced. The discharge from the abscess has been free, but no decomposition has taken place; no offensive odour. In consequence of irritability of the bowels, milk diet with chicken broth and a little port wine and brandy were ordered. Night draught to be repeated.

Saturday, 25th, 9.30 a.m.—The patient seemed to be very much the same as yesterday, but complained of feeling weaker, and his wife said that he had abandoned hope of recovery the evening before. The short and hurried breathing, and the small and quick pulse continued. Morning temperature 99.4°. The irritability of the bowels had diminished, but at 1 p.m. the bowels were relieved, and immediately after this effort a little blood was observed to trickle out from the lower border of the bandage. Mr. Adams and Mr. Watson were sent for and arrived in a few minutes. The patient appeared to be sinking. The pulse was 120 to 130 and very small; it soon became impossible to count it; and the breathing, at first short and rapid, gradually became prolonged. He died at 3.15, just two hours from the commencement of the bleeding, which appeared to be very slight.

Post-mortem examination, Monday, 27th December, 1880.—Body fairly well nourished.

Right pleural cavity contained a pint or more of serum, in which long shreds of yellow flocculent lymph floated from all sides, and

Digitized by Google

the pleura was everywhere thickened and covered with a thick layer of adherent lymph. The thickening of the membrane was very marked over the surface of the diaphragm where this had been pushed upwards by the abscess in the liver, and had, no doubt, resulted from the direct extension of inflammation through the diaphragm. No pus was found in the pleural cavity.

Right lung compressed and displaced to the upper and posterior part of the chest-cavity lying between the spine and the angles of the ribs; a small portion of the lung was adherent to the surface of the diaphragm. A portion of the compressed lung-tissue thrown into water immediately sank.

Left lung perfectly healthy.

Diaphragm pushed up to the 4th rib anteriorly on the right side by the liver. The pleura over the diaphragm thickened and covered with lymph, as already described. On the under surface of the diaphragm close adhesions existed everywhere at the upper and posterior part between the liver and diaphragm.

Liver a little enlarged, surface smooth; general appearance tolerably healthy; structure rather pale and looked a little fatty, but not in any marked degree. At the upper part of the right lobe was the cavity of an abscess three inches in diameter, containing yellow pus and lymph; no broken down liver structure. The wall of the abscess was thick and well defined. The external opening, between the ninth and tenth ribs, communicated directly with the cavity of the abscess. No other abscess existed in the liver.

Spleen.—Enlarged to nearly twice its normal size, but structure apparently healthy.

Kidneys.—Pale, but structure apparently healthy; the right contained a small cyst.

Heart.—Natural as to size, and generally healthy; all the valves healthy; no atheromatous deposit in aorta, but the pulmonary artery was filled with a firm fibrinous clot, moulded to its shape, extending into the right ventricle. This clot had probably formed some time previous to death, and contributed to, if, indeed, it was not the immediate cause of death.

Intestines.—No indications of old or recent ulcerations, either in the large or small intestine; mucous membrane generally attenuated and walls of intestine thin; the valvulæ conniventes had almost disappeared; patchy congestion in many parts, more in the small than in the large intestine; arborescent patches of congestion in many

Digitized by Google

places, and the mucous membrane covered with thick viscid mucus stained with bile.

The tenth rib, just below the puncture, was entirely denuded of its periosteum, and in a roughened, carious condition for more than an inch of its length. The tissues in the neighbourhood were somewhat disintegrated, and possibly an intercostal vessel might have been opened by ulceration, giving rise to the hæmorrhage which immediately preceded death. WM. ADAMS.

The chief point of interest in this case is the nature of the abscess. The history and the condition of the patient, suffering from chronic diarrhœa and dysentery, seemed to point to the abscess as one of those septic abscesses which doubtless do, though perhaps not so frequently as is supposed, follow tropical dysentery, such abscesses generally being multiple.

The abscess was single, and had probably occurred independently of the bowel complaint, although excited by the same climatic causes.

Had the opportunity occurred of making a free opening earlier, there is reason to think that the result might have been different.

The formation of a fibrous coagulum in the pulmonary artery—a condition so likely to supervene in certain states of the blood, especially in those induced by malarious influences—is interesting, and worthy of attention as a more frequent cause of death than is generally supposed.

The power of the cavity to contract after the removal of a large quantity of pus is also remarkedly illustrated.

Acute dysentery and liver abscess; the liver and large intestine of a case of multiple abscess.

CASE.—G—, a Hindoo, aged 24, admitted into the Medical College Hospital, Calcutta,[1] August 7th, 1880; died August 16th, 1880.

Had diarrhœa for a month, culminating in dysentery with fever during the last seven days; is weak and anxious-looking. Great pain over lower part of abdomen, which is hard and tender to the touch, especially at one spot, about three inches below the right costal arch, in the course of the ascending colon, where also a distinct tumour-like thickening of the bowel, can be felt, almost the

[1] From Dr. McConnell.

Digitized by Google

size of the closed fist. It is dull on percussion. The stools are very frequent, ten to twelve in twenty-four hours, and passed with much griping and straining. They consist of soft fæculence, with branny mucus and blood.

August 8th.—Thirteen stools in last twenty-four hours; abdominal tenderness increasing; urine scanty. Temperature 100° Fahr.

9th.—Several dark sloughs passed to-day and the tumour-like swelling in the abdomen is diminishing.

12th.—Seven to eight stools in twenty-four hours; no more sloughs; a little fæculence and blood.

14th.—Patient weak; fever increasing. Twelve stools to-day; fæculent and bilious.

15th.—To-day the stools contained a few more pieces of slough and gelatinous mucous (nine stools during the night); pain in abdomen much less.

Evening.—Has had ten evacuations during the day; countenance very worn and anxious; pulse small and weak; extremities cold. The tumour has entirely subsided; gurgling on pressure in the right iliac fossa.

16th.—Subnormal temperature 96·4° to 97°; pulse thready. Twelve stools during the day; contained sloughs. Body bathed in sweat. Sank gradually, and died at 8.45 p.m.

Temperatures.

1880.	Morning.	Evening.	1880.	Morning.	Evening.
Aug. 7	98·4°	99·0°	Aug. 12	99·0°	102·0°
„ 8	99·0	100·0	„ 13	98·4	102·0
„ 9	98·4	100·0	„ 14	99·0	102·0
„ 10	99·0	100·2	„ 15	98·2	100·6
„ 11	98·4	102·6	„ 16	96·4	97·0

Post-mortem examination, August 17th, 1880, twelve hours after death.—Body emaciated; rigor mortis slight. Brain-substance pale, anæmic, much softened. Lungs: anterior portions pale and anæmic, but the margins and bases dark and congested; the lower lobes œdematous. Heart feebly contracted; fluid dark blood with small fibrinous clots in right cavities; a little fluid blood in the left; muscular tissue pale and soft. Abdomen: small intestines much distended with gas); their walls unusually thin and translucent. The transverse colon is seen glued to the under surface of the

Digitized by Google

liver by a little recent lymph. There are similar soft recent adhesions between the liver and diaphragm and between the transverse colon and duodenum; and about two ounces of opaque turbid serum effused into the general peritoneal cavity. Weight of liver 2 lbs. 15½ oz. Both upper and lower surfaces are covered with soft, projecting nodules, seen on section to be abscesses. They vary in size from a hen's egg to a hazel-nut, and on incising the liver are seen also thickly distributed throughout the parenchyma of both lobes. Each abscess is distinctly circumscribed, is surrounded by a bright hyperæmic zone, and contains a varying quantity (from a few drops to half an ounce) of thick, glairy, greenish-yellow pus. Such portions of the liver-substance, as remain unaffected, are soft and greasy. The lobular structure indistinct. No reaction under iodine. Gall-bladder about a third full; duct free; bile thick, reddish yellow; measures a little over two drachms. Spleen a little enlarged. Capsule much thickened and opaque, adherent to the surrounding parts. Substance moderately firm. The trabecular structure throughout much hypertrophied. Weight 7¾ oz. A good deal pigmented at the periphery. Kidneys a little congested; nothing else remarkable. Stomach small and contracted. The mucous membrane a good deal congested, pale and anæmic. That of the small intestine also pale and anæmic, but stained yellow from bile. The ileum throughout is much thinned. The ileo-cæcal valve has been partially destroyed by ulceration. The whole of the cæcum presents a thickened, puckered, and ulcerated condition. The mucous membrane of the rest of the large intestine is highly swollen and œdematous. A little below the hepatic flexure of the colon is a very large, transversely-placed ulcer, its margins covered with recent creamy inflammatory exudation (lymph); and the rest of the gut is thickly covered by transversely-placed ulcers and sloughs, the majority also showing a granular recent deposit of lymph at their margins and bases. The submucous and muscular coats of the bowel are enormously swollen and œdematous, very much thickened over the whole ascending colon, and especially rigid in the neighbourhood of the large ulcer therein found (above described). The whole intestine, is contracted in calibre, abnormally firm, rigid, and shortened. The mesenteric glands are not affected. The stomach contains about two ounces of milky fluid; the small intestine about six ounces of brownish, thin, muco-fæculent fluid; the large gut about half an

Digitized by Google

ounce of thin, highly offensive fæculence, with one large dark slough and numerous small fragments or shreds of others.

I am indebted to Mr. Alban Doran, F.R.C.S., of the Royal College of Surgeons, for the following report on the microscopic examination of the so-called abscesses of the liver of this case:

"I selected a small piece of hepatic tissue, close to the surface of the liver, which included a spherical white lump, firm throughout. The liver substance around it was of the normal colour and appearance; the surface was slightly puckered over the white lump.

"Sections of this piece were cut, after hardening, by Dr. Vincent Harris, in the Physiological Laboratory of St. Bartholomew's Hospital; the freezing microtome was used for this purpose. The section here shown was stained with logwood. I then examined this section, and found the following appearances:

"In the midst of the white mass I distinguished a cloudy or faintly granular matrix, containing a few liver-cells, some with their outlines tolerably distinct, others much broken down; so that I suspect the granular matrix may be made up of *débris* of liver-cells. More distinct than these cells were elongated bodies, of the shape of cells seen in young connective tissue, only none were so distinct. I could not detect a nucleus in any; and when seen in a mass, under a low power, they had a fibrillated appearance. The exact nature of these bodies is uncertain; they possibly represent fibrillation of new connective tissue, or may have been artificially produced by the action of the hardening medium on the not quite absorbed fluid part of an old abscess. The portions of the section, which included the border of the white mass, showed the fibre-like or spindle-cell-like bodies very indistinctly, large and perfect liver-cells predominating, whilst some of these were undergoing degeneration. The appearance of the section at the extreme limit of the white mass, and close to the most evidently normal part of the true liver-substance, shows the morbid change in a still earlier condition.

"It is at least clear that the morbid action has taken place amidst the true liver-cells, and never displaced them, but simply destroyed them in their places, for the *débris* of these cells may be distinctly traced in the deepest part of the white mass. They appear, in fact, to have broken down from acute local inflammation; the cells being homologous to the 'cloudy' and swollen cells

Digitized by Google

in tubal nephritis. No true leucocytes can be found, hence exudation from the vessels must have been very slight. *May 3rd*, 1881.

---

7. *Abscess of the liver consequent upon dysentery contracted in England.*

By W. Howship Dickinson, M.D.

The specimens before the Society are the representatives of a case which appears to throw light on the debated nature of the connection between dysentery and abscess of the liver and goes far to support the view that the abscess is a direct consequence of the dysentery against the opinion held by so many distinguished Indian pathologists, that the two disorders are but fortuitously associated or only as common results of the same cause.

A lath-splitter, 36 years of age, was admitted as my patient at St. George's Hospital on the 9th of March, 1881. He had a good family history, had had good general health up to the beginning of the illness for which he sought admission, and had never left England.

On the 14th of the preceding February he, being then apparently in perfect health, went to see the international sculling race on the Thames, at which he thought he got chilled. He drank more than usual on that day, and in the evening ate fifteen raw mussels; to these he attributed his attack. Half an hour after he had swallowed them he "felt very queer" and had violent pain in the stomach; he had no vomiting, but was violently purged five times during the night. The diarrhœa was constant during the whole of the next day and so continued until the 18th when he went to the Royal Free Hospital and got some medicine which gave him relief. But the relief was only partial.

On the 22nd the diarrhœa recurred with violence, insomuch that from the 23rd of February until the 2nd of March, he was confined to bed. He then became an out-patient, and then, as related, an in-patient at St. George's Hospital, the diarrhœa having been

Digitized by Google

practically continuous from its origin on the 14th of February to his admission on the 9th of March.

The action of the bowels had latterly been as frequent as seventeen and twenty-one times in the twenty-four hours; the motions were described as slimy and containing blood. When first seen some days afterwards they were liquid and yellow, much like the motions of typhoid, and the surface of the liquid mottled with small sanguineous patches. The patient was febrile, his temperature ranging pretty regularly from about 98° in the morning to 102° in the evening. The belly was distended and tender, the pulse rapid, the tongue remarkably smooth, polished, and bare of epithelium, and presenting an uniform bright red, almost vermilion tint. There were no typhoid spots nor any evidence of tubercular disease though there were prolonged respiration and dulness behind the right lung.

The treatment may be briefly indicated as restriction of the diet to milk and farinaceous food, with the subsequent addition of brandy as the prostration increased, and the administration in admixture or succession of ipecacuan, opium, bael, compound kino powder, Australian red gum, acetate of lead and acetate of morphia.

The discharge was somewhat mitigated by the remedies, but the condition of the patient did not improve. The abdomen remained full and tender, much as with typhoid, to which also there was further similarity in the state of the motions and in the temperature. This maintained its large daily variation, generally rising four degrees from morning to night. Before death it was observed that the right hypochondriac region presented increased dulness while the patient complained of pain in the right side of the chest. The abdominal tenderness and the prostration of the patient prevented any satisfactory examination of the affected regions. He sank on the 24th of March, thirty-eight days after the first symptom.

On *post-mortem* examination the large intestine presented from end to end a patchwork of dysenteric ulcers, separated by narrow ridges of thickened mucous membrane. The ulcers were very irregular in size and shape; they were for the most part deep, some exposing the muscular coat of the bowel. The glands of the mesentery of the meso-cæcum and meso-colon were congested and swollen.

Digitized by Google

The small intestine was healthy. The liver contained a large single abscess which held about four ounces; it lay in the back part of the right lobe near its upper and posterior surface. The shape was irregular, its walls ragged, and without lining membrane.

The right pleura was coated with flocculent lymph, and the cavity contained serous fluid in quantity sufficient somewhat to compress the lung. No communication or connection could be traced through or behind the diaphragm between the hepatic abscess and the inflamed pleura, though it could not but be suspected that these lesions were associated by contiguity.

Nothing else was found save a few miliary tubercles of old standing in the right lung, and a small superficial cavity of somewhat doubtful nature.

Remarks—It may be in the memory of some of the older members of the Society, that in the year 1862[1] I brought forward the instance of a woman, who had never left England, who died with an enormous hepatic abscess (it held at least a gallon) and dysenteric ulceration of the large bowel. The present case is more conclusive because its history is more definite; it is scarcely possible to look at the occurrences in their order and doubt that the dysentery was the direct and immediate cause of the abscess of the liver. No other influence was observed, or could be conceived, to which the abscess could be attributed. The man had never left England. Until he was seized with dysentery, he had had vigorous health, the only interruptions to which were an attack of gonorrhœa sixteen years before, and slight rheumatism eight years before his death. It is sufficiently evident that the abscess was not antecedent to the illness which commenced in so definite a manner on the day of the boat-race, and it is equally clear that the disorder began so early and so violently with bowel disturbance, that it is not possible but that any other mischief must, at least, have been subsequent to this. Since the abscess then obviously followed the dysentery, the inference presents itself, at least, as a probability that the hepatic was the result of the intestinal lesion. And this probability is strengthened in this case, almost to a certainty, by the absence of any tropical or other influence which could be supposed to have acted as a common cause for the dysentery and the abscess.

Dr. Budd's view that the hepatic abscess is produced by the irritation of dysenteric products conveyed to the liver by the portal

[1] 'Pathological Transactions,' vol. xiii, p. 121.

Digitized by Google

vein, explains this and similar cases in so satisfactory a manner that it needs more conclusive evidence than any yet adduced to compel its abandonment.

But many Indian authorities, those it must be allowed who have seen most of dysentery and of hepatic abscess, do not accept this view of their direct connection, but hold that the association is fortuitous, or, at least, no more direct than that both are the results of a common cause, or of causes which occur together. The late Dr. Murchison, while allowing the possible origin of pyæmic (multiple) abscesses in dysentery, gave it as his opinion that the tropical (single) abscess is independent of this disease; and Sir Joseph Fayrer has expressed similar views. But it seems to me that the abscess is so constantly preceded by the ulceration that we are bound to believe in a direct connection. It is easy to show, and it is nothing to the point, that dysentery, as at Millbank Prison, may take place any number of times and not be followed once by abscess: seed does not always fructify, nor every ovum produce an animal. It may be presumed that the slighter forms of the bowel complaint, such as occur in temperate climates, seldom give rise to this grave result. But, looked at from the hepatic point of view, we find the connection is more easily to be seen, for, however often dysentery may occur without abscess, it is very seldom that abscess occurs without dysentery. Waring found, as the result of *post-mortem* examination, that in 72 per cent. of the cases of abscess of the liver, fatal in Madras, the lesions of dysentery were also present; and Netley Hospital provides similar evidence, showing 34 cases of dysentery in 48 of fatal hepatic abscess. And it is obvious that these figures necessarily understate the frequency of dysentery, since they only note the presence of its lesions after death. Abscess of the liver has little tendency to recovery, and will, with few exceptions, be found after death if ever present during life. Not so dysentery. Mucous membrane has a power of healing which is peculiar to itself, and executes an amount of unobservable repair which is scarcely to be paralleled by any other structure. It is, therefore, probable that there may have been instances of dysentery among these cases in which that disease, though it may have given rise to abscess, has subsequently disappeared and left no other record of its existence.

Pyæmic abscesses in the liver are usually many and small, the dysenteric or tropical abscess single and large; this may be held to

Digitized by Google

show that the tropical abscess is not strictly pyæmic, but it does not follow that it is not equally a direct result of dysentery. It may be that the dysenteric poison is a cause, not of the embolic process of pyæmia but of a more diffuse irritation, which sets up local hepatitis, which rapidly advances to suppuration *en masse*. Whether the dysenteric irritant (assuming this to exist) be or be not different from that of pyæmia, there is, at least, one point of difference which is sufficiently clear between the morbid absorption of dysentery and that at least of systemic pyæmia. It is obvious that the irritants of systemic pyæmia, which so constantly result in multiple abscesses, are distributed to the liver by the hepatic artery; the poison of dysentery by the portal vein. But since pyæmic abscesses, which take their source within the portal territory, as from cancerous simple and typhoid ulcers, are also multiple, it is probable that the peculiarity of the single or tropical ulcer, supposing it to be of dysenteric origin, arises from the nature of the infection, not from the channels by which it is conveyed.

I venture to think that the tropical evidence before us is enough to show a direct, or, at least, a close connection between the abscess and the flux; that the dysentery is the cause of the abscess, or the abscess of the dysentery, or that both are the results of a common cause. That the abscess causes the dysentery has been long ago proposed and abandoned. The only method which can be suggested is by the contact of vitiated bile, and that, it is to be presumed, would affect the upper part of the bowel more than the lower, instead of the reverse, as dysentery does. The hypothesis of a common cause might be accepted, though doubtfully, had we only tropical cases to go by. Hepatitis is a disorder of the tropics; dysentery is so too. Dysentery is produced by the water, abscess possibly by the brandy which is mixed with it, which only in the tropics is productive of this result. But it is not possible thus to explain the cases which occur where no tropical influences are at work. In this country, solitary abscess of the liver, apart from hydatids, is immeasurably rare; that it should accidentally befall together with dysentery, which is also rare, and have no pathological connection with it, is so improbable as to be nearly impossible. In the present case the dysentery clearly came first; if either lesion caused the other, the dysentery caused the abscess. In the absence of tropical influence no common cause presents itself. And, in short, I think we have no choice but to look upon the ulceration and the

Digitized by Google

abscess as cause and effect, and upon the portal vein as the connection. *May 3rd*, 1881.

---

8. *Abscess of liver in a child.*

By NORMAN MOORE, M.D.

THE liver showed two abscesses, one in the right lobe as large as a small orange, and one in the left lobe of the size of a filbert. The abscesses have very definite boundaries, and microscopic sections of the neighbouring tissue showed healthy liver structure. The whole of the large intestine was extensively ulcerated.

The patient was a girl, aged 3½, who was under the care of Dr. Andrew, and died in St. Bartholomew's Hospital.

She had been ill ten months with diarrhœa, and for about two months there were slime, blood, and general symptoms of dysentery. She was in the hospital for about five weeks, and during that time her temperature occasionally sank to 99°, but usually ranged from 102° to 105°.

The child had never been out of London, so that this is an example of hepatic abscess following British dysentery. The case is further of rarity on account of the age of the patient, and I have not met with an account of hepatic abscess after dysentery occurring at so early an age as three and a half years.

January 18th, 1880.

---

9. *Cirrhosis of liver in a child.*

By NORMAN MOORE, M.D.

THE whole liver was dense, with great elastic bands of fibrous tissue in its substance. The surface was rough and nodular. Microscopic sections show atrophy of the liver-cells with great increase of connective tissue.

Digitized by Google

There was tuberculosis of the peritoneum but not of the liver. There was great ascites. The specimens were from a girl aged ten years, who was in St. Bartholomew's Hospital, under the care of Dr. Gee.

On admission the child was greatly emaciated, and had considerable distension of the abdomen. Even after tapping, which was done twice, neither liver nor spleen could be felt. Her temperature was raised throughout. There was no history of spirit-drinking, and I believe the case to have been an example of interstitial hepatitis in association with general tuberculosis as described by Cornil and Ranvier. *January 18th*, 1881.

---

10. *Cirrhosis of liver in a child with congenital hydrocele.*

By SAMUEL OSBORN.

C. F—, aged 9, first came under Mr. Osborn's care on the 11th of January, suffering from a congenital hydrocele of the left side. It had only been noticed seven or eight months, and showed the usual transparency by transmitted light with propulsion on coughing and reduction in size after lying down. A left inguinal truss was applied and worn continually for four days. The contents of the hydrocele sac commenced to increase, directly after the application of the truss, to such an extent that the father thought it would burst.

On January 18th, there was found to be œdema of the penis and scrotum on the left side, showing that the hydrocele sac had actually ruptured, the scrotum still remaining beautifully transparent. Cold water rags were kept continually applied and the scrotum supported. The father fancied that at this time the child's abdomen was increasing in size; but his mother stated that he had always been pot-bellied. Child suffered no pain.

January 24th. The fluid in the abdomen has gradually increased in quantity, with decided fluctuation across the abdomen, which now measures thirty-one inches in circumference. It was the opinion of Mr. Osborn that the pressure of the truss at the neck of the

Digitized by Google

hydrocele had produced subacute inflammation of the peritoneal and hydrocelic sacs. Aperients were administered and punctures made to relieve the œdema of the penis, but the fluid in the abdomen increasing in quantity sufficient to obstruct the breathing, Mr. Osborn tapped the hydrocele and emptied the abdomen by that means, drawing off about eight pints of clear fluid.

The boy then went on well as long as the fluid drained away. The puncture, however, occasionally closed up, so Dr. Southey's indiarubber drainage tube was inserted to keep the opening free. At the same time two grains of Hyd. c. Cretâ were given twice a day, and under this treatment his abdomen decreased in size four inches.

On February 23rd, after having passed a very restless night, he became delirious, troubled with a severe cough and difficulty of breathing, and died quite suddenly. The father, mother, and remaining children were all healthy and highly respectable.

Post-mortem examination by Dr. Seymour Taylor.

On February 24th, 1881, I made a *post-mortem* examination of the body of C. F—, who had died four hours previously.

I may preface the account of the autopsy by stating that the family history I obtained was good. The father is a steady, sober man. The mother has had one miscarriage, but enjoyed good health.

The patient had had measles, and subsequent whooping-cough, when very young. He had suffered from epistaxis for the last four or five years, and from morning sickness for last four years, with loss of appetite for breakfast. I could obtain no history of spirit drinking.

The child had never been jaundiced; had not suffered from hæmorrhoids, but had gradually lost flesh since Christmas, 1880.

The body was warm; rigor mortis had set in. There was no signs of scars or ulcers on any part of the body; there was slight *post-mortem* staining down the flanks and most dependent parts of the body.

The peritoneal cavity was distended with fluid and communicated with the left tunica vaginalis, forming a congenital hydrocele; the tunica vaginalis was thickened; the scrotum and penis swollen and œdematous. There was also slight œdema of the belly walls.

A dark, offensive, and apparently sanguineous discharge, exuded from the nostrils.

On opening the abdominal cavity it was found to contain 2½ pints

Digitized by Google

of clear serum; but there were no signs of inflammation, no naked-eye appearances of tubercle.

My little finger was easily passed through a patent left internal abdominal ring, down the inguinal canal and into the scrotum, where the testis could be felt in its normal situation.

Pleura healthy, with the exception of slight old adhesions at the left apex.

The pericardium was normal.

The lungs were both somewhat congested, with slight collapse along the anterior borders. They presented no appearance of tubercle.

The heart was free from valvular disease; there was no congenital malformation.

The stomach was greatly distended with gas; its coats much thickened; and the mucous membrane covered with dark, offensive, and apparently bloody fluid, which easily washed off, leaving a slightly discoloured surface. There was no ulceration and no malignant growth. Dark blood oozed from the cut vessels in the walls of the stomach. The duodenum contained similar dark fluid, but the remainder of the alimentary canal was not examined. The liver weighed 20½ oz. It was free from any signs of perihepatitis. It measured:

Antero-posteriorly, right lobe	6½ inches.
„ „ left lobe	6½ „
„ „ at suspensory ligament	4 „
Transversely	7 „
In greatest thickness	2½ „

It is a good specimen of cirrhosis. The whole of the surfaces of the gland are irregular and nodulated, but with no appearances suggestive of syphilitic taint. The nodules are well marked, prominent, and vary in diameter from ⅛ of an inch to that of a mustard seed, but are not more particularly marked in one lobe than in the others. Where the transverse fissure joins the left lobe is found an accessory lobe about the size of a pigeon's egg, the surface of which is not so deeply puckered as the other parts of the organ although the actual nodules are slightly larger than elsewhere.

The anterior border of the liver is sharp, and its general consistence firm and elastic.

The capsule is generally thickened all over, is here and there

Digitized by Google

very transparent, and presents many ramifying superficial blood-vessels.

The gall-bladder was full of dark, viscid bile, and was apparently healthy.

On examining the cut surface of the liver it will be observed that the gland substance is mapped out into small circumscribed areæ, corresponding in measurement with nodules seen on the surface of the organ. These areæ are groups of lobules; the growth enclosing them consists of fibrous tissue rich in cells, ramifying principally in the course of the offshoots of Glisson's capsule and the larger divisions of the portal vein.

But it is not limited only to the course of the larger vessels, but, under a higher power of the microscope, it is found to follow the course of the finer subdivisions of the portal system—to dip into the lobules, and to enclose and separate various groups of cells. Many of such isolated cells have lost their normal shape and characteristics, and are reduced to granular *débris*, or are shrunken and withered, or compressed by the adventitious growth into shapes resembling stratified epithelium.

The spleen was enlarged, measuring 7 inches by 3, apparently twice the normal size; it was very firm and much congested; its weight was not ascertained.

The kidneys were healthy.

The testes also healthy as regards their gland structure.

The brain and spinal cord were not examined.

Remarks.—The above case is interesting to the Society for many reasons.

We fail to obtain any evidence of alcoholic excess. The child's parents are respectable people of the working class, and they can give me no account of the boy's "tippling." He occasionally fetched his father's ale from the tavern, but was never known to obtain spirits. His mother states that he only rarely had a "sip of ale," but that he showed no taste nor desire for it.

There is no distinct trace of syphilitic taint, either in the father or mother, The mother has had one miscarriage; one other child died of bronchitis; the rest of the family are healthy and well.

The age of the patient is of great interest.

Although by no means the youngest case recorded, still a case of cirrhosis of liver in a child under 10 years of age is sufficiently rare to justify its being brought before the Society.

Digitized by Google

Amongst others, the late Dr. Murchison records a case in a boy aged 9, who died in St. Thomas's Hospital. Also Dr. Frederick Taylor[1] brought a parallel case before the Society last session of a child aged 8. In Dr. Murchison's case there was distinct history of alcoholic excess.

In briefly discussing the possible causes of cirrhosis, or conditions somewhat resembling cirrhosis, I may draw attention to the following facts, as revealed by the *post-mortem* examination:

1st. There were no bands of adhesion to the diaphragm or surrounding structures, thus negative of the chance of its being due to a perihepatitis.

2nd. The valves of the heart were healthy, therefore the condition of the liver could not be due to the secondary results of chronic passive congestion.

3rd. There are no deep fissures or cicatrices in the liver, such as would suggest its possible syphilitic origin.

4th. Against its alcoholic origin are the age of the patient and the absence of spirit "nipping."

On the other hand, the history of morning sickness, the splenic engorgement, and the microscopical appearance of the liver, are in favour of alcohol being its cause. *April 19th*, 1881.

---

11. *Cicatrices in the liver, the result of suppurative pylephlebitis.*

By James F. Goodhart, M.D.

The patient was a boy, aged 18, who was admitted into Guy's Hospital, under my colleague Mr. Howse, for an abscess of obscure origin in the left loin. This abscess communicated with the descending colon. He was ill about ten months in all, and died worn out by emaciation, suppuration, and lardaceous disease of the viscera.

At the inspection a pelvic abscess was found which had burrowed about in various directions, forming sinuses in each groin, and also

[1] 'Transactions of Pathol. Soc. of London,' vol. xxxi, p. 119.

Digitized by Google

in the left loin. The latter opening also into the colon. The abscess had opened also into the general peritoneal cavity and set up a suppurative peritonitis. The colon was ulcerated, and there were appearances in the cæcal appendix which looked like the scar of an old ulcer. For this reason, and because no other probable source of abscess was to be found, I concluded that typhlitis had possibly been the cause of all the mischief.

The left pleura was the seat of a local empyema; there were infarctions in the lung, and a lardaceous spleen and intestine. The state of the liver is also particularly worthy of record.

The portal vein was completely occluded, its walls much thickened, and containing in its centre purulent matter tinged with bile pigment. The greater part of the liver was perfectly healthy, but in various parts scars were found which mostly had a caseous centre, and in one spot, near the surface, was a distinct mass of caseous matter, apparently an old or residual abscess.

Under the microscope, a quantity of new fibrous tissue was seen to have destroyed the liver substance almost completely at the spots described as scars.

The interest of the case seems to hinge upon the probability that suppurative pylephlebitis had ended, not as usual in the death of the patient, but in cicatrisation, and in doing so had set up isolated centres of cirrhosis, such as have been described by Hanot, Charcot, and others in connection with the ducts. A condition similar to this has been observed and such cases have been recorded by Dr. Moxon and myself to exist occasionally in the kidney.

May 17th, 1881.

Digitized by Google

V. DISEASES, ETC., OF THE GENITO-URINARY ORGANS.

1. *Epithelioma of bladder, following removal of a calculus.*

By N. Davies Colley.

Thomas L—, aged 51, painter, died in Guy's Hospital in October 1880, of cancer of the bladder, under the care of Dr. Habershon.

In 1858, when 29 years old, he was admitted under Mr. Birkett in Guy's Hospital, having suffered from symptoms of stone in the bladder for seventeen years. The stone was first crushed three times, and then lateral lithotomy was performed. Two fragments of a large oxalate of lime calculus, coated with phosphate, were removed. Seven months later he was again admitted (in March, 1859) suffering from irritation at the end of the penis, and a constant desire to micturate. He was sounded but no stone could be detected. In a short time he went out relieved, but he appears ever since to have been troubled by pricking sensations in the penis. Five years before his death he came under my care in the Seamen's Hospital, Greenwich, with fracture of the neck of his femur. While he was under treatment it was noticed that his urine contained a little blood. His bladder was again sounded but no stone was found. About a year before his death he began to pass large quantities of blood per urethram. Latterly, he suffered from anasarca, and a tumour was felt in the region of the left kidney.

At the *post-mortem* examination it was found that a considerable portion of the lungs was consolidated by pneumonia, and that here and there softening had taken place and sloughing cavities formed. The bladder was contracted; a mass of cancer projected from its posterior wall as a flat nodulated growth into its interior as large as the palm of one's hand. It reached downwards and forwards nearly as far as the urethral orifice. Its surface was rough

Digitized by Google

and villous. It was continuous with a thick mass of cancer, which projected above the fundus of the bladder into the upper outlet of the pelvis. The prostate and vesiculæ seminales were healthy. The cicatrix of the lithotomy wound could be seen on the left side of the floor of the prostatic urethra.

The left kidney was much enlarged, and reduced to a sacculated pouch full of pus. It contained also two-branched coral-like calculous formations composed of triple phosphate. The branches extended into the dilated calices and the stalks into the pelvis. There were two small nodules of cancer in the liver. The vena cava inferior was completely obliterated by a similar growth from the glands in front of the lumbar vertebra. On examination with the microscope the tumours in the bladder and the glands were found to be good examples of epithelioma.

Remarks.—I have brought this case forward because it seems to me probable that the cancer of the bladder was the result of the vesical calculus removed twenty-one years before the patient's death. In vol. xxviii of the 'Transactions,' Dr. Fagge has recorded two cases of epithelioma of the bladder, in which the disease was due to chronic cystitis and catheterism, and numerous instances might be cited in which similar results have followed the irritation of other mucous tracts. At the same time that this patient was under my observation, a man was attending as one of my out-patients with frequent hæmorrhage from the bladder, who gave a similar history of a stone removed many years before. As I sounded him and could detect no evidence of the presence of another stone, I presume that in him also the bleeding was due to ulceration or cancerous growth. It seems to me probable that in the case which I have related, an ulcer or scar had been left after the removal of the large stone twenty-one years before. That this had been the cause of the pricking sensation of the penis, which never left him, and that finally the epithelioma had developed as the result of this persistent irritation. On the other hand, it may be urged that the presence of a large calculus in the kidney was sufficient to account for the sensation referred to in the penis; and if my hypothesis is true with respect to the causation of the cancer, it is strange that the much greater irritation due to the presence of the large calculus within the kidney should not have determined development of the cancer there rather than in the bladder.

March 3rd, 1881.

Digitized by Google

2. *Case of villous polyp of the bladder.*

By Frederick Treves.

The bladder exhibited was taken from a man, forty-eight years of age, who died of cancer of the pylorus. For the last fourteen years of his life he had suffered from occasional hæmaturia, and for this symptom he was admitted into the London Hospital, under my care, some short time before his death. The bladder presents a small villous polyp, projecting from its posterior wall, and situated about midway between the summit and the orifice of the viscus. The polyp in the recent state was roundish, about the size of a large cherry, and when floated in water had a very flocculent and uneven surface. When not suspended in a fluid it precisely resembled a clot of recently coagulated blood both in colour and consistence. It was extremely soft, very freely movable, and attached to the bladder by a very narrow and fibrous-looking pedicle, about the thickness of a No. 8 catheter. For some little distance upon this pedicle the mucous membrane of the bladder was continued. But for this polyp the bladder was perfectly healthy, as were also the prostate, urethra, and kidneys. Death had occurred from gradual emaciation in connection with the cancer at the pylorus. The case might be considered of interest on these grounds—tumours of this kind are somewhat rare, they have occasioned death from hæmorrhage, and have at the same time been successfully removed by operation; the diagnosis, therefore, is a matter of importance. The symptoms of such growths appear to be mainly negative, and much stress is laid—in the matter of diagnosis—upon the one conspicuous symptom of hæmaturia. This symptom is apt to be confused with the hæmorrhage from cancerous growths, and Sir Henry Thompson[1] and others, in dealing with the differential diagnosis between these two affections, state that the hæmorrhage in cancer is usually intermittent, and, when it does occur, severe; whereas in villous disease the urine is more or less persistently coloured with blood. In the present case the hæmorrhage was always intermittent, occurring usually at intervals of from fourteen to thirty days or more, and during the attacks the

[1] 'Clinical Lectures on Diseases of the Urinary Organs,' fourth edition, p. 352.

Digitized by Google

loss of blood was often very considerable. The attacks lasted about two or three days as a rule. The absolute freedom from hæmorrhage during the intervals was remarkable. During such periods no amount of exercise appeared capable of inducing bleeding. Moreover, he was on several occasions sounded during these intervals, and although the instrument must have passed several times over the growth no bleeding ever ensued.

During the continuance, however, of the hæmorrhagic attacks vigorous exertion would increase the amount of blood that appeared in the urine.

The bleeding had not increased either in severity or in frequency, and, indeed, some of the most severe attacks of hæmaturia occurred early in the history of the disease.

It is remarkable that the growth should have existed for fourteen years and yet have attained so inconsiderable dimensions.

April 19th, 1881.

---

3. *Case of sarcoma of the right kidney confined to the capsule.*

By William H. Day, M.D.

E. N—, aged 4, a female child, was admitted into the Samaritan Hospital, under the care of Mr. Knowsley Thornton, February 8th, 1881, with an abdominal tumour of two months standing. A swelling was first noticed on the right side of the body below the ribs, and it had since become painful. The tumour extended downwards from the region of the liver to the spine of the ilium, and irregularly inwards for an inch to the left of the umbilicus. It had an elastic solid feel but palpation was difficult on account of tenderness, and fluctuation could nowhere be detected. The general opinion expressed was in favour of the growth being a malignant tumour of the kidney. The superficial veins were greatly distended on both sides of the abdomen, over the tumour, being dilated from the axillæ to the iliac spines, but most markedly on the right side.

Digitized by Google

The measurements of the tumour were—circumference at umbilicus 27 inches; from the spine to the middle line of abdomen on either side 13½ inches; from right anterior spine of ilium to umbilicus 6 inches; from left spine to umbilicus 6½ inches; from ensiform cartilage to umbilicus 6 inches; from ensiform cartilage to pubes 4½ inches.

The heart was displaced upwards and to the left; the thorax was generally dull on percussion, and respiration was scarcely audible over the whole thorax, or below the spine of the right scapula.

Mr. Thornton passed a small trochar and cannula into the most prominent part of the tumour in the right lateral region, under the carbolic spray, but only a few drops of dark, bloody serum escaped. On March 7th he transferred the patient to my charge, when the temperature was 100·0°, and the pulse 120; the child lay on her back, and was free from pain. On the following day, at 8 p.m., the temperature was 103·0°, pulse 120, respiration 30; she was in no pain, but very fretful. On March 16th, the morning and evening temperature averaged 100·0°; she screamed out from pain in the body; the abdomen was tense and shining, whilst the veins were more distended. On the 17th the temperature reached 102°, and on the following day fell to 99·0°. Ten days later (28th) she had gradually become worse; the face was anxious and the lips dusky; there was short hacking cough from bronchial congestion; the pulse and respiration were rapid, but the temperature for some days had been normal, now it rose to 100·0°; the labia, feet, and legs were œdematous, and only a small quantity of urine was passed. She died on the 30th, having been in great pain during the previous night.

The *post-mortem* examination was made by Mr. Ammond Routh eleven hours after death. The body was generally ill-nourished; the labia and legs were œdematous. The abdomen was enormously distended, and the abdominal veins also, especially on the right side from the ilium to the axilla. On opening the body, and removing the sternum and costal cartilages, the lungs were found to be much collapsed. The heart occupied a position completely to the left of the mid-sternum, and the apex lay between the third and fourth ribs outside the nipple line. The diaphragm was at the level of the second interspace on the right side, and at the third on the left. The abdomen was filled, from the diaphragm to the true pelvis, with a whitish-looking tumour, occupying all

Digitized by Google

the right half of the abdomen, and pushing the liver and intestines over to the left side. The lower border of the right lung was situated in the third interspace, and the base was rather congested; the lower border of the left lung was situated opposite the second interspace; the apex was emphysematous, but there were one or two pneumonic patches at the base. The liver was normal, but pushed over to the left side, the upper border reaching to the third left interspace. The right border was displaced as far as the median line. The spleen was normal. The left kidney was healthy in structure but somewhat enlarged.

The *tumour*.—The circumference from above downwards was 26 inches, the transverse circumference 22 inches. It occupied all the space from the third intercostal space to the true pelvis on the right, and part of the left iliac and hypogastric regions. It was ovoid in shape, covered with peritoneum, of a pale colour, slightly lobulated, and semifluctuating except at a few points on the right surface, where distinct fluid could be made out. On removing the tumour by cutting through the pedicle attached to the spinal region, the renal artery and vein were seen entering it much enlarged. It was altogether beneath the peritoneum. On the under surface, the ureter, normal in size and appearance, was seen entering a solid body, embedded in the tumour. This body is evidently the kidney considerably enlarged and lobulated, but of normal colour and feel. The tumour seemed to grow out from the upper, lower, and anterior surface of the kidney, the posterior surface being quite free.

It was found on further dissection that the tumour did not involve any part of the kidney, but lay entirely between the anterior surface of that organ and the capsule which was stretched over it, but could readily be traced from the surface of the tumour on to the back of the kidney. The tumour was chiefly composed of a soft, encephaloid material, which broke up easily, with here and there patches of softer and more fluid matter. It weighed 9¼ lbs.

Sections of the tumour were examined microscopically by Mr. Knowsley Thornton and Mr. Alban Doran. The growth proved to be a mixed sarcoma, spindle-cells predominating; but round cells were, at different parts, very abundant. Immediately under the capsule, as may be seen in the specimen shown under the microscope this evening, is a very distinct zone of round cells, of almost uniform breadth. Beneath this zone is a layer of spindle-cells, and, deeper in the growth, round cells and spindle-cells, larger than those lying

Digitized by Google

more superficially make up the bulk of the tumour. The deep lying round cells precisely resemble those forming the zone under the capsule. This zone appears to be simply the lymphoid tissue naturally lying beneath the capsule, and there is reason to believe that the morbid growth might have been developed from this tissue. The difficulty in hardening this very soft growth has hindered the preparation of very distinct sections showing the reticulum of lymphoid tissue; but from anatomical position and from the form of its round cells, the zone under the capsule has every appearance of being lymphoid. *May 3rd*, 1881.

---

4. *Calcified fibroid of uterus.*

By Norman Moore, M.D.

The calcified mass as large as a child's head, was found attached to the uterus of a woman, aged 54, who had died of cirrhosis of the liver. She had been for some time under the care of Mr. Godfrey, of Jersey, and the tumour caused no symptoms, and was unsuspected during life. Mr. Godfrey made the *post-mortem* examination, and was so good as to send me the specimen.

October 18th, 1880.

---

5. *Large multilocular fibrocystic tumour of uterus.*

By W. A. Meredith, M.B., C.M.

The specimen was removed from a patient in the Samaritan Hospital, aged 43, by my friend and colleague Mr. Knowsley Thornton, to whose kindness I am indebted for the opportunity of showing it to the Society.

The existence of uterine fibroid disease was first recognised ten years ago, but only within the past three years had the tumour,

Digitized by Google

which seems previously to have presented only the ordinary features of a solid fibroid growth, begun to enlarge at all rapidly. The total weight of the mass removed at the time of operation was twenty-three pounds, of which the fluid contents constituted about eighteen pounds.

On examination the tumour is seen to consist of a mass of cysts, eight to twelve in number, the whole springing from a solid base of dense fibroid material, which was attached by a short, thick pedicle to the fundus of a much enlarged fibroid uterus. The outer surface of the growth is covered by the remains of very extensive omental adhesions, whence was derived the chief vascular supply. The divided surface of the pedicle, which measures nearly three inches in diameter, shows traces of but very few vessels of any size.

The cysts, constituting the main bulk of the tumour, are of various capacity; one or two of the largest may have held as much as four or five pints of fluid, but the majority are much smaller. The cyst walls, as a rule, are thick and tough, showing a perfectly smooth white surface from within, very different in appearance from the lining membrane of ordinary ovarian cysts. In one instance, however, a cavity containing the remains of broken down blood clot, shows much staining of its inner surface. Three or four of the smallest cysts presented a marked contrast to the remainder, as being uniformly extremely thin and translucent where protruding into neighbouring cavities, or upon the surface of the tumour; thus suggesting the possibility of spontaneous rupture in such cases.

On section of the solid portion of the growth, in the neighbourhood of the pedicle, there may be noticed several points at which cystic changes are evidently commencing in the dense tissues, which appear softened and relaxed around small translucent-looking areas, where small collections of semi-fluid material are forming between the meshes of the fibrous tissue. Microscopical examination reveals the ordinary fibro-myomatous structure commonly met with in uterine growths. The internal surface of one of the thin-walled cysts which I examined was lined by a layer of small, elongated, flat nucleated cells, suggestive of an endothelial origin.

Some fluid withdrawn at the operation from one of the main cyst cavities was of a deep amber colour, perfectly clear and limpid, with none of the viscid qualities commonly met with in the secretion found in ovarian cysts. It was of neutral reaction and showed

Digitized by Google

a specific gravity of 1020. There was no tendency to spontaneous coagulation even after keeping for some time; but on boiling a portion of it in a test tube, there was immediately formed a dense heavy coagulum, which was subsequently all but completely dissolved on further boiling after the addition of an equal quantity of strong nitric acid. A few drops of cold acid added to some of the original fluid at once caused a dense white precipitate, which proved partly soluble in an equal bulk of the acid, and was then almost entirely dissolved on boiling.

On examination of the tumour four days after removal, it having been in the mean time left exposed to the air and not placed in any preservative solution, the contents of one or more of the smaller thin-walled cysts, which had not been opened, were found to have undergone partial coagulation, with the formation of a tolerably firm clot of moderate bulk. A similar process had also taken place in some of the fluid which had escaped into the vessel containing the tumour.

Microscopical examination of the cyst fluid showed but few elements of any kind; the most noticeable were large, granular, occasionally nucleated cells, resembling those met with in ovarian fluids; in addition to these were seen a few specimens of small, flattened, endothelial (?) cells, and occasional examples of the so-called "fibre cell," described by Dr. Atlee as characteristic of fibro-cystic fluids, and considered by him as degenerated muscle fibre, a view as to the correctness of which I have as yet been unable fully to satisfy myself. *January* 18*th*, 1881.

---

6. *Proliferating cysts in the ovary of a seven months' fœtus.*

By Alban Doran.

[With Plate VI, fig. 2.]

A few months since, when engaged in the examination of healthy human ovaries, I removed the internal generative organs from a seven months' fœtus, kindly forwarded to me by my friend Dr. Champneys. Presuming from their outward appearance that the

Digitized by Google

ovaries were absolutely normal, I thought that they would afford me a favorable opportunity for investigating the development of the Graafian follicles, and particularly for observing the primitive involution which these follicles undergo long before puberty. For this purpose I first entrusted the ovaries to Dr. Vincent Harris, whose skill and experience in preparing microscopic specimens were sufficient to ensure the production of the fine series of sections which are brought forward to-night.

Each ovary measured two fifths of an inch in length. The right proved to be perfectly normal. Hundreds of Graafian vesicles were scattered over the stroma. In the tissue of the hilum, but there only, were thick-walled vessels. It is significant that whilst in the left ovary not one of the smaller cystic cavities presently to be described could be positively identified as an ovisac, in this, its fellow, the follicles forced themselves on the observer's notice at the first glance. Some of the deeper follicles lay close to the thick-walled vessels with which they are so often confounded. The ova were very distinct; the epithelial lining of the follicles was far more prominent than the slender endothelium which bounded the lumen of the thick-walled vessels, but much thinner than the lining of the morbid cysts in the left ovary. The spindle-celled stroma of the parenchyma in this normal ovary contrasted strongly with the fibrous and elastic tissue which replaced it in the same organ on the left side.

The left ovary appeared quite flat, like its fellow, and had the sharply-defined, sinuous border characteristic of the ovary in later fœtal life. Dr. Harris and myself were much surprised, on examining the sections, to find that the ovary contained three cysts, of almost equal size, lying in a row along its long axis, and plainly visible to the naked eye, which could also detect exuberant vegetations growing from their walls. The cysts were almost perfectly spherical; the largest measured one-twelfth, the smallest one-sixteenth of an inch in diameter.

Examining the sections under the microscope, I found that the cysts, owing to their great relative proportions, encroached equally on the vascular tissue of the hilum and on the more superficial part of the ovary towards the tunica albuginea. They were surrounded by much condensed fibrous tissue. Into their interior grew an abundance of branched vegetations covered with a stratified layer of columnar epithelium. After repeated examination I could detect

Digitized by Google

cilia on some of the superficial epithelial cells. In the narrower processes of the vegetations the stroma appeared purely fibrous, but in the broader tufts there were epithelial bodies in the midst of the stroma. The tissue at the base of these same tufts passed into the substance of the ovary, external to the boundary of the cyst, the epithelioid cells being traceable throughout, from the stroma at the free end of the tuft to the stroma of the ovary. These cells were clearly the same which, found in the deeper parts of normal ovaries, are admitted to be relics of the tubes of the Wolffian bodies.

In one of the sections (where a fourth proliferating cyst could be seen) a mass of vegetations sprouted, without any capsule, from the outer end of the ovary. The epithelial lining was far more regular than in the intra-cystic growths, and on examining a section of the fimbriated extremity of the Fallopian tube connected with this ovary, the identity of its epithelium and subepithelial stroma with the epithelium and stroma in the free vegetations outside the ovary became self evident. In fact, these free growths must have been developed from the ovarian fimbria of the tube.

The stroma of the parenchyma of the left ovary contained an unusual amount of elastic fibre and a very scanty supply of the spindle cells seen in normal ovarian tissue—as in the fellow to this ovary. The germinal epithelium had atrophied and become converted into a true condensed, fibrous tunica albuginea. Towards the surface of the ovary were several enlarged vessels, some full of blood-corpuscles, and all recognisable by their thin endothelium and thick muscular coats. Close to them were several cystic bodies not exceeding one-fiftieth of an inch in diameter, and lined with columnar epithelium precisely similar to that which invested the intra-cystic growths. At first these small cysts appeared to be true Graafian vesicles, but on careful examination it could be seen that none contained ova, and that the epithelium on their inner walls was made up of much larger cells, arranged with greater regularity than in the cellular lining of a true ovisac in any stage of its development. No such epithelium could be found within any of the normal follicles which swarmed in the opposite ovary. The stroma around these small cysts contained a great number of the epithelial cells already mentioned. In fact, these cysts were most probably an early and younger form of the larger proliferating cavities.

There can be little doubt, judging from the appearances described

Digitized by Google

above, that the proliferating cysts were developed from vestigial remains of some of the tubes of the Wolffian bodies, not from those tubes which remain in the adult as the parovarium, but those which can be detected in the stroma of the ovary as certain epithelioid bodies. The existence and nature of these bodies is admitted and explained by most of the living authorities on ovarian histology, especially Balfour, who has distinctly traced them from the Wolffian body. Klein and Noble Smith describe them minutely in their 'Atlas of Histology,' chap. xxxii, p. 286, quoting His, Waldeyer, Romiti, Born, and Balfour, as holding the same opinions on the nature of the epithelioid bodies. Olshausen, in his work 'Die Krankheiten der Ovarien,' describes at great length certain proliferating cysts often confined to the ovary, but more often involving the broad ligament, and in both cases traceable to the vestigial remains of the Wolffian body in the ovary. This kind of cyst is well known to surgeons experienced in ovariotomy, and distinct from the simple, non-proliferating "parovarian cyst;" but I am not aware that it has ever been observed before in a fœtal ovary. Olshausen states that no cysts, except those originating in dilatation of the Graafian follicles, have been found in the ovaries in fœtal life.

The epithelial elements scattered in the stroma of a normal ovary representing a general atrophy of that part of the Wolffian body which becomes surrounded by ovarian tissue, it is reasonable to suppose that the proliferating cysts in this specimen represented tubes belonging to that body which have, on the other hand, become dilated and cystic. All these changes, normal and morbid, were to be seen in this same specimen. Firstly, the proliferating cysts, then the smaller cystic bodies, one fiftieth of an inch in diameter, and hardly altered from their original condition as true Wolffian tubes, and lastly, the epithelial relics of other Wolffian tubes that have undergone normal atrophy.

The absence of Graafian vesicles was so marked in this ovary as to lead to the conclusion that the abnormal changes in the Wolffian tubes must have blighted their development at a very early period.

The general appearance of the ovary is well represented in the highly successful micro-photographs taken by Mr. Francis Fowke and brought forward this evening for exhibition, together with the microscopic sections, with which they may be compared.

March 15*th*, 1881.

Digitized by Google

7. *Fibro-cyst of uterus.* (*Card specimen.*)

Exhibited by W. A. MEREDITH, M.B.

THE tumour weighed altogether 23lbs.—about 6lbs. solid and 17lbs. fluid contents.

The mass is composed of a number of smooth-walled cysts, with partitions of variable thickness, springing from a thick stem which was attached to the top of a large fibroid uterus. The pedicle contains but few vessels of any size, with a large amount of muscular tissue. The main blood supply was derived from vessels in the extensive adhesions of the omentum and mesentery which enveloped the upper portion of the tumour. The cyst contents consisted of yellow serous-like fluid, sp. gr. 1020, neutral or faintly attractive in reaction, which was not spontaneously coagulable.

January 18*th*, 1881.

Digitized by Google

VI. DISEASES, ETC., OF THE OSSEOUS SYSTEM.

1. *A case of congenital absence of fibula and two toes, and talipes equino-valgus.* (*Living specimen.*)

By A. Pearce Gould, M.S.

J. W—, male, æt. 8 years, seventh child of healthy, well-developed parents; none of his brothers or sisters exhibit any deformity. His mother states that when her seventh pregnancy had advanced two or three months she fell heavily on her face and stomach and shook herself severely; she was quite well during the rest of the pregnancy. The boy is a healthy, intelligent child, well-developed in every respect except in the left leg. The appearance of the leg is stated to be the same now as at birth. The thighs are symmetrical. The *left leg* is generally smaller than the right. The *tibia* is rather sharply curved forwards just below the middle, and over the prominence of the crest there is a vertical groove in the skin 1½ inch long. The inner malleolus is prominent on the inner side of foot. The *fibula* is entirely absent; there is no trace of outer malleolus, shaft or head. A firm fibrous or tendinous ridge can be traced up for some distance, occupying the position of the fibula; this is no doubt the outer border of the interosseous membrane. The *great toe* is normal. There are *two small webbed toes*, probably the second and third on its outer side. The heel is drawn up and the tendo-Achillis is tense; the foot is also everted, its inner border depressed, the outer border raised, and the sole looks outwards as well as down. Between the outer border of the foot and the tibia, where the outer malleolus should be, there is a deep wide groove. The *biceps* tendon is smaller than normal, and can be traced to its insertion into the outer condyle of the tibia. The *calf* is fairly developed, and the peronei and the extensor muscles of the toes and the tibialis anticus can be clearly traced. The boy is badly crippled,

Digitized by Google

for the limb is considerably shorter than the other, and on walking he rests on the inner malleolus and inner side of the foot.

This case was kindly sent to me at the Westminster Hospital by Dr. W. Murrell. I divided the tendo-Achillis and so brought down

WOODCUT 2.

the heel, fitted the boy with a high boot with a support on the outer side, and he is now able to walk upright on the sole of the foot, and is considerably improved.

Congenital absence of either of the bones of the leg is less frequent than of the radius or ulna, and only one case of absence of the tibia has been recorded (Billroth). It is also more common to find absence of part of the fibula than of the whole bone as in the above case. Mr. Wagstaffe has recorded two such cases ('Journ. of Anat.,' vol. vii, 1873), in one of which only the lower end of the fibula was present; in the other a small mass of bone was

Digitized by Google

felt occupying the position of the head of that bone. Dr. Meyersohn ('Virch. Archiv,' vol. 76) refers to 6 other cases—4 of deficiency of the upper part of the bone, recorded by Meckel, Nagel, and Volkmann who found the same condition in a father and son; in Nagel's case the right arm was absent too. In these cases the fibula was only represented by the malleolus. In Volkmann's cases the toes were normal; in Meckel's case the cuboid and two outer toes were absent; in Wagstaffe's case the second and fourth toes were absent and the tarsal bones were fused together into a flat mass of bone. The two cases of absence of the lower part of the bone were observed by Billroth and Schnelle. Billroth's patient had the head and upper end of the shaft of the bone, and the fifth digit was absent. In Schnelle's case, as in Wagstaffe's, only the head was present, and only the inner two toes were developed. Wagstaffe's patient had three toes. At the meeting at which my case was shown, Mr. W. Adams said he had seen several cases of partial absence of the fibula, but in his opinion there was really fusion of the bones in such cases—he did not refer to any dissections in support of this assertion. I can find no account of any case of "fusion" supported by anatomical evidence, and, indeed, what certain evidence there is goes to refute this view, for in all dissected specimens the interosseous membrane has been present, and very strongly developed along its outer edge, which becoming quite tendinous, has replaced the shaft of the fibula as a firm origin for muscles.

Cases of bilateral complete absence of the fibula have been recorded by Göller, Danyau, Buhl, and Humphrey; and of the same deformity on one side only by Duval, Otto, Faber, Wagstaffe, Ringhoffer, Dumas, Rosenberg, Foerster, Meyersohn, and the present case is, therefore, the fourteenth recorded example of this malformation that I have been able to meet with. In many of the cases the facts have been verified by careful dissection. The degree of associated deformity has varied very much, thus in Foerster's case ("Die Missbildungen des Menschen") the left leg had no fibula, three toes to the foot, no leg muscles, foot small, contracted, and drawn back. From the back of the thigh below the middle sprang another leg, in which there was a fibula and six toes—the inner being doubled. In Humphrey's case (On the Skeleton) the cuboid and one toe were also absent, and the toe representing the fourth and fifth articulated directly with the os calcis. Rosenberg's case is the only one in which all the toes have been present, from

Digitized by Google

one to four having been absent in the other cases; in Faber's case the rudimentary foot consisted of only a mass of cartilage covered with skin; while in Ringhoffer's case no phalanges were present but the nails were well formed. The foot is generally in a condition of valgus, but varus (Otto), equino-varus (Duval), and pure and extreme equinus in one case, have also been noted.

Humphrey has pointed out that the fibula is absent in many animals such as the ruminants, and there is a relation—but not close—between its presence and absence and the presence and absence of the outer toes.

The biceps tendon is always inserted into the outer condyle of the tibia when the head of the fibula is absent. The peronei, flexor, and extensor muscles commonly arising from the shaft, are usually present when the bone is absent, and spring from the firm outer edge of the interosseous membrane, which, as in the present case, can generally be felt as a tight cord along the outer side of the limb.

Wagstaffe found considerable good from tenotomy, and the use of suitable mechanical appliances.

The groove in the skin over the bend in the sharp crest of the tibia is characteristic of a congenital malformation, and is never seen in an acquired deformity. The curve in the tibia gives some support to the notion that intra-uterine violence may have been the cause of the deformity. *November* 16*th*, 1880.

---

2. *Fracture of the coracoid process, followed by fibrous repair.*

By Samuel G. Shattock.

The specimen was obtained from an aged female subject.

The fracture of the coracoid process is slightly oblique, being directed from before backwards, between the insertion of the pectoralis minor and the origin of the coraco-brachialis and inner head of the biceps; the coraco-clavicular ligament is attached solely to the entire base of the process.

The fragments are united by a fibrous strap-like band about a

Digitized by Google

third of an inch in length, and continuous with the adjacent portion of the coraco-acromial ligament.

There was no injury of the shoulder-joint or of the clavicle.

As in the cases cited by Flower and Hamilton, the detached fragment has undergone no material displacement, which indeed would probably be always true, since the coraco-clavicular ligament will maintain the detached process in position should it be fractured through its base; or should the fracture pass, as in this specimen, in front of the coraco-clavicular, the detached fragment will be as securely upheld by the coraco-acromial ligament.

The evidence of fracture as against an epiphysial separation of the coracoid process is as follows:

The coracoid ossification includes nearly the whole of the process, and most, if not the whole of the surface which gives attachment to the coraco-clavicular ligament, and the plane of its union with the body of the scapula is directed obliquely downwards and outwards towards the glenoid cavity, the highest part of which it forms.

On the contrary, in the specimen, not only is the plane of fracture out of correspondence with the plane of the natural union, but the coraco-clavicular ligament and the pectoralis minor are connected wholly with the undetached portion of the process.

October 19*th*, 1880.

---

3. *Comminuted fracture of the astragalus with subastragaloid dislocation of the foot outwards and backwards.*

By Henry Morris.

[With Plate XVIII.]

Thos. McC—, aged 40, was admitted May 31st, 1875, under me, into the Middlesex Hospital, with such a complete smash of the right leg as to require immediate amputation. The left foot was also the seat of a severe injury; it was made out at the time that there was a comminuted fracture of the astragalus, and that the foot was displaced outwards and a little backwards beneath the

Digitized by Google

Digitized by Google

Fig. 1.

E. Burgess lith.

Fig. II.

West Newman & Co. imp.

Digitized by Google

DESCRIPTION OF PLATE XVIII.

Illustrating Mr. Morris's Case of Comminuted Fracture of the Astragalus with Subastragaloid Dislocation of the Foot outwards and backwards.

FIG. 1.—Subastragaloid dislocation of the foot outwards with comminuted fracture of the astragalus, the head of which remained in the scaphoid socket. Bony ankylosis resulting. Inner view.

A. Tendons of flexor longus digitorum and flexor longus pollicis, which had been ruptured and are now amalgamated with the tendinous origin of the abductor pollicis.

B. Tibialis posticus tendon, which had been ruptured and has formed a new attachment to the internal malleolus.

C. Inner malleolus, ankylosed with the astragalus and projected downwards on the inner side of the foot.

D. Line of fracture through the neck of the astragalus.

E. Head of the astragalus in normal relation to scaphoid. A quantity of new bone has taken the place of the calcaneo scaphoid ligament.

FIG. 2.—Outer view of the same foot.

A. Tendon of peroneus longus, ruptured and jammed down between the back of the fibula and the upper surface of the os calcis.

B. Tendon of peroneus brevis attached to the outer surface of the os calcis.

C. Fibula ankylosed upon the superior surface of the os calcis.

D. Lower end of the tendon of the peroneus longus.

Digitized by Google

Digitized by Google

astragalus, which seemed to have retained nearly, if not quite, its natural relations with the tibio-fibular mortise. There was some increase of length between the point of the heel and the back of the ankle, and a corresponding shortening of the foot in front of the ankle; the width of the foot just in front of the ankle was increased. There was no marked eversion of the sole of the foot, and there was a distinct soft tumour between the tendo Achillis and the back of the ankle. The soft parts of the foot and leg were much contused, but there was no undue pressure from the fractured astragalus upon the skin. The accident was caused by the man falling, together with a number of planks, the height of 100 feet, as he was being raised by a crane.

Extensive cellulitis of the foot and leg followed, and the skin around the ankle, heel, and lower part of the leg, sloughed in patches; but ultimately, after several months in hospital, he was able to get about on an artificial limb, and with his left foot ankylosed in a good position with the leg. During the last five and a half years he has been occupied as a care taker, but after long standing he has suffered pain in the left ankle, and on two or three occasions he has returned to the hospital on account of ulceration of the cicatrix. He had repeatedly urged me to remove the foot, and at last, yielding to his entreaties, I amputated, and the patient now goes about more comfortably upon a pair of wooden pins.

Examination after removal.—There had been a transverse fracture right across the neck of the astragalus, the line of which is still clearly indicated by a narrow sulcus. The body of the astragalus, the tibia and fibula, are all ankylosed by bone to one another. The foot is still displaced a little outwards but not backwards, so that the fibula rests upon the upper surface of the os calcis, to which it is very firmly ossified. A quantity of new bone has been thrown out on the under surface of the body of the astragalus, whereby it is united behind by a bridge of bone to the inner part of the os calcis, posterior to the articular facet on its upper surface, and on its outer side to the under surface of the sustentaculum tali. Bony buttresses also pass from the internal malleolus and front of tibia to the body of the astragalus.

All the three tendons which pass round the inner ankle had been completely ruptured, and were by their upper ends connected with the fibrous tissues behind the inner ankle and to the tibia. By

Digitized by Google

their distal ends they were firmly attached to a layer of osseous tissue on the under surface of the astragalus.

The peronei longus and brevis were both ruptured; the brevis had firm connection with the outer side of the os calcis; the longus was attached deeply behind the fibula and had been firmly jammed down between that bone and the os calcis.

The arteries were not lacerated, but the posterior tibial was very small, and rigid from calcareous deposit; and to it, just behind the inner ankle, a small fragment of bone the size of a pea was adherent.

May 17th, 1881.

---

4. *Fracture of the inner malleolus with partial dislocation of the foot by rotation around its antero-posterior axis.*

By Henry Morris.

The preparation, consisting of the dissected foot and the lower half of the bones of the leg, was removed after death from an elderly woman, who died in one of my wards at the Middlesex Hospital from advanced malignant disease of the mamma.

The only history obtainable was that nineteen years ago she had met with an accident whereby her "ankle was broken."

The foot was "out of shape," and remained so, but subsequently she was able to gain her livelihood sometimes at a street stall, sometimes by hawking goods in the streets. The foot was greatly deformed, and in the position typical of extreme talipes equino varus, a large bursa was developed over the outer and dorsal side of the foot.

On examination after dissection, the foot was found so much displaced with regard to the tibio-fibular mortise, that the posterior extremity of the superior and inner edge of the astragalus corresponded to the central part of the trochlear surface of the tibia; and the articular surface of the external malleolus corresponded to the posterior part of the trochlea of the astragalus. Thus the foot was displaced forwards, and was in addition rotated about a quarter of

Digitized by Google

a circle round its antero-posterior axis. The astragalus, together with the rest of the tarsus, being *rotated*, so that the inner edge of the foot was raised.

The head of the astragalus was "started" to a slight degree upwards and outwards from its scaphoid socket; but this was probably due to the crumpling or shortening of the inner edge of the foot by the approximation of the os calcis to the scaphoid; whereby the superior ligaments have been stretched and the sustentaculum tali is almost touching the lower edge of the scaphoid. This altered position of the os calcis to the scaphoid increases the depth of the tarsal arch, and was doubtless produced gradually by the constant pressure of the weight of the body from above, and the resistance of the ground against the outer edge of the metatarsus below.

The posterior edge of the tibia rests upon the upper surface and upper and inner border of the os calcis behind the articulation of that bone with the astragalus. The inner malleolus had been broken off and was displaced backwards, lying embedded in fibro-cellular tissue against the inner surface of the os calcis.

The tip of the outer malleolus had also been detached and was displaced downwards and forwards, still resting in its place against the astragalus.

The surfaces of the astragalus and fractured end of tibia were much altered; bony outgrowth had occurred at the lower end of the tibia above the seat of fracture, and a piece of bone projected from above downwards in a crescentic manner from the inner side of the neck of the astragalus.

The tibia rested in a large semilunar depression, bounded in front by this osseous deposit on the astragalus; behind by the tendons passing round the inner ankle and the other fibrous structures at this part; on the outer side by the inner surface of the astragalus; and below by the edge of the sustentaculum tali and the condensed and partially ossified calcaneo-scaphoid ligament.

May 17th 1881.

Digitized by Google

5. *Genu valgum.*

By HENRY MORRIS.

[With Plate XIX.]

HENRY L—, aged 18, a small framed, timid lad, looking not more than 12 or 13, was admitted into the Middlesex Hospital, on February 25th, 1881, with well-marked genu valgum of the right knee and two discharging sinuses over the lower part of the right shin.

About eight years before, some wood fell on his legs, and shortly after this accident a lump formed on the right shin and was very painful; soon, this swelling was lanced, and ever since there has been a discharge of thin pus from the part. So far as he knows no bone has ever come away. Not long after the lump on the leg formed, his right knee began to enlarge on the inner side, and the direction of his leg to change; but it is only quite recently that he has not been able to walk on this leg.

On admission the knee was much deformed, owing to a great increase of the inner condyle, which projects unduly both on the inner and front aspects of the joint.

The patella is displaced so that its front surface looks more outwards than forwards, and its articular surface seems to be resting entirely upon the outer side of the enlarged internal condyle.

The leg is flexed upon the thigh at an angle of 140°, and cannot be extended beyond this; flexion, however, in this limit, is perfect. As he lies on his back, the whole limb is so rotated outwards as to allow the outer side of his knee and the outer side of his foot to rest flat on the mattrass with the leg straightened out as far as possible; when his leg is flexed he can rest his foot flat on the sole, but if he wishes to extend the leg again he at once rotates the thigh outwards until the outer side of his limb is again resting on the mattrass, and then he extends the leg with an effort. It appears that in this posture the extensor muscles get a greater pull upon the tibia than,—owing to the oblique position of the patella and the altered shape of the inner condyle,—they obtain when the thigh is straight or rotated inwards.

When erect, his leg inclines outwards from the knee to the ground,

Digitized by Google

Digitized by Google

Fig. III.

Digitized by Google

Burgess lith

West Newman & C° imp

DESCRIPTION OF PLATE XIX.

Illustrating Mr. Morris's paper on Genu Valgum.

FIG. 3.—The leg and foot are in the position of standing; the thigh being straightened as nearly as it was possible.

The drawing shows great enlargement of the inner condyle, with a large supplemental growth of cartilage below the outer condyle. The marked obliquity of the femur and of the foot to the leg are well seen.

An ununited fracture of the tibia and a false joint at the seat of fracture are shown. The tibia received support from the curved fibula, which is in contact with the tibia at the level of the fracture, and for some distance above it.

The irregular outgrowth of cartilage upon the articular surface of the patella is also shown.

Digitized by Google

Digitized by Google

so that the inner edge of the foot is nine inches from the vertical line drawn through the symphysis pubis. The leg is rotated outwards at the knee, and has the appearance of being partially displaced backwards.

The hamstring tendons are somewhat contracted. There is no tenderness or pain. Except for the limited extension the passive movements are unimpaired, and in addition there is very free lateral movement, which causes the joint to be very insecure.

The leg is much smaller than normal, all the parts being wasted. The head and upper four or five inches of the shaft of the fibula can be distinctly made out, but are very small; the external malleolus is small but distinct, and the peronei tendons, as they pass round it, bulge somewhat on to its outer surface. The lower and middle parts of the shaft of the fibula cannot be defined; indeed, there seems to be no bone, in this part of the leg, distinct from the tibia; and nothing like an interosseous space can be distinguished.

There is a large supple scar over the right shin and the inner surface of the calf; at the lower part of the scar is a superficial ulcer, and two sinuses lead through the ulcer down to the tibia. The tibia here is thickened and irregular, but the probe impinges on soft tissue more like cartilage than carious or rough bone.

Three years ago he fell upon his right elbow, and since then the external condyle of the right humerus has become enlarged, and extension of the forearm on the arm is impaired. Like the knee, the elbow is quite free from pain or tenderness, but is much deformed. The liver is enlarged, and the urine contains $\frac{1}{5}$ albumen, and has sp. gr. 1008.

His thigh was amputated on April 6th; he made a good recovery, and on leaving the hospital his urine contained scarcely a trace of albumen; the improvement in his physique and the change from a timid, scared manner, to one of confidence and cheerfulness, were very marked.

Examination after removal of the limb.—The internal condyle was greatly enlarged in every direction, and chiefly by an overgrowth of the posterior lower surface, which rests naturally upon the tibia in extension and moderate flexion. The increase in this direction had led to a vertical elongation, so to speak, of the condyle, and to a tilting backwards and outwards of the tibia; the tibia was also, as a necessary consequence, separated by a greater distance than normal from the line of the lower epiphysial cartilage of the femur.

Digitized by Google

The external condyle was much deformed, having its outer and front edge somewhat everted, and a large superadded mass of cartilage was growing from its fore and inner side, and served as a bearing point for the outer tuberosity of the tibia in all positions of flexion and extension. The idea suggested by this mass was that the tibia, being pushed downwards by the vertically elongated inner condyle of the femur, needed this addition to the outer condyle as a point of resistance for its outer tuberosity; it is obvious that but for this the degree of valgum would have been much greater.

The old trochlea on the femur for the patella had come to look upwards, and was much altered in size and outline. It no longer received the patella, which was now resting in a large fossa, formed below the normal trochlea, and between the condyles, just in front of the intercondylar notch.

The articular surface of the patella was much deformed, being enlarged, irregular, and very soft. All the natural markings on it were entirely defaced.

The entire alteration in shape of the femur was due to the great growth of cartilage. At some parts, as over the inner and part of the outer condyles, this growth involved the surfaces uniformly; at others the cartilage was deposited in the shape of an excrescence. In some places it presented a firm resistance. In others it was soft and almost boggy to the touch; this was especially the case at the new trochlea on the femur, and upwards from this to the epiphysial junction; and on detaching a little of the cartilage here a quantity of soft tissue, like splenic pulp, was exposed. The increase in the patella was probably due chiefly to this pulpy material beneath the cartilage-coated surface, for here and there the cartilage was so thin as to allow of the red colour being seen through it; and everywhere the structure of the patella was very yielding.

The internal lateral ligament was elongated, but became much stretched during extension by the pressure of the enlarged inner condyle, which projected beyond the edge of the tibial tuberosity against the ligament. The external lateral and the crucial ligaments were tense, the external lateral especially; its chief point of attachment seemed to be in a deep groove between the lower edge of the external condyle and the outer surface of the additional mass of cartilage growing from the condyle. The popliteus tendon was attached much higher up, but the natural groove for it was lost.

The bones of the leg and thigh were very small, especially the

Digitized by Google

upper part of the shaft of the fibula. The tibia, in its lower half, was rough and irregular, and in places carious; it was completely fractured in a transverse direction, and a false joint had been formed. The fractured ends were soft and cartilage-like, and doubtless it was here that the probe had touched at the time of the examinations previous to amputation. The fibula was curved inwards towards the tibia at its lower two fifths, so as entirely to do away with any interosseous space: and, being in the closest contact with the tibia, it acted as a buttress to it; had thus afforded sufficient support for the patient to walk and stand upon this leg until the insecurity of the knee became too great; and had prevented any appreciable mobility, or other symptom of an artificial joint. The semilunar cartilages were natural, and the articular surfaces of the tibial tuberosities were not noticeably altered beyond being smaller and softer than natural. There were no nodular outgrowths on the tibia.

May 17th, 1881.

---

6. *Acute necrosis of the tibia.*

By W. Morrant Baker, for Dr. Gregory White.

The specimen was removed by amputation from a boy 11 years old, who was admitted into the Bournemouth Cottage Hospital, under the care of Dr. Gregory White, August 13th, 1880. For the notes of the case from which the following abstract has been made, I am indebted to Dr. Woodroffe, house-surgeon.

Five days before admission into the hospital the lad was struck, in play, on the knee by a small fir cone, but, with the exception of a little stiffness, he did not complain of anything for two days. Then he began to complain of pain below the knee, which increased up to the time of his admission. At this time he suffered much pain and had a temperature of 103·2° F. The right knee was somewhat swollen but not tender. The skin of the upper half of the leg was, however, glazed, swollen, slightly red, and acutely tender.

On the 14th August a free incision was made, and gave exit to a

Digitized by Google

large quantity of thick pus, with great relief to the suffering of the patient.

For a day or two the general condition seemed improved, but on the 17th there occurred an attack of diarrhœa, and the temperature rose to 105°. This was followed by very rapid loss of flesh, delirium, and night sweats. The discharge from the wound was very copious, amounting to about half a pint in twenty-four hours.

On the 23rd August amputation was recommended, but the parents would not consent.

During the next few days the patient was occasionally delirious, but the temperature was lower.

On the 27th there was some shivering, with a rise in temperature and increased flow of pus.

During the next fortnight the patient became weaker, was frequently delirious, and continued to lose flesh; but it was not until the 14th September that consent was given for the amputation of the limb. This was performed on the same day by Dr. White, at the junction of the middle and lower third of the thigh.

For a time the patient seemed to rally well, but ultimately sank about a fortnight after the operation.

Dr. Woodroffe adds that, after removal of the limb, the soft parts were found normal on dissection, with the exception of the popliteus and tibialis anticus muscles, close to their tibial attachments, which were found softened and much paler than normal. The periosteum from the middle to the upper third of the shaft of the tibia was easily stripped from the bone.

The specimen is an excellent one of acute necrosis, with some osteomyelitis of the upper third of the tibia; the sequestrum being in part detached. There are the usual evidences of attempted repair, with thickening of the surrounding periosteum and nodular deposits of new bone. *October 19th*, 1880.

Digitized by Google

7. *Ostitis of the femur.*

By W. Morrant Baker.

The specimen was removed (by amputation) from a man (G. B.) aged 28, who was admitted into St. Bartholomew's Hospital, May 13th, 1880, with the following history:

About nine months ago he had pains in the knees, and the joints became swollen. The swelling of the right knee, unlike that in the left, did not subside.

About six months ago an incision was made on the outer side of the ham and the opening has never closed. Abscesses have since formed in the ham and burst.

At the time of admission the thigh was swollen, and the swelling was found to be evidently due to a considerable thickening of the lower two thirds of the femur. The scar of the incision, which had been made along the outer side of the ham, was still visible, and this was pierced by several fistulous tracks. There were also two fistulæ on the inner side of the popliteal space. At the back of the thigh, about the junction of the middle and upper third, was another fistula, through which a probe could be passed to what felt like dead bone at the back of the femur.

The patient was a fair and delicate-looking man, and had wasted much. His temperature was, during his stay in the hospital, always above normal, rising every evening to between 99·4° and 101°. He suffered excessively from pain in the affected limb, and his rest was much broken.

The patient came under my care in the beginning of September, and on the 15th I explored the sinuses in the thigh with the object of discovering whether the disease were necrosis or only inflammation of the bone. No dead bone could be anywhere detected; but the sinuses extended by large and irregular tracks to various parts of the bone, which was, however, not bare, but sheathed everywhere by thickened periosteum. No blood-vessel of any notable size was divided in the exploration of the parts, but there was a good deal of oozing of blood at the time; and within the next three days two attacks of hæmorrhage of the same kind occurred, the blood

Digitized by Google

appearing to come from various parts of the raw surface made by the incisions. This fact and the probability that if amputation were not soon performed the patient would sink fromthe exhausting effect of pain and discharge, compelled me to amputate notwithstanding the patient's prostrate condition.

Amputation through the middle third of the femur was accordingly performed on September 19th, 1880. No trouble occurred with any large vessel, and altogether no considerable amount of blood was lost at the time; but numerous ligatures were applied, blood oozing from minute vessels on almost every part of the face of the stump. After the application of carbolised oil dressings the stump was firmly bandaged, and the patient removed to bed.

Although exhausted and with a weak pulse, the patient held his ground fairly well during the night, but early in the morning following the amputation the house-surgeon was called to him on account of hæmorrhage of the same character with that which had given trouble on two occasions before the amputation as well as during its performance. After considerable trouble the house-surgeon stopped the bleeding by the application of perchloride of iron, followed by firm bandaging and the elevation of the stump. The patient, however, gradually sank and died about sixteen hours after the amputation.

Examination of the limb after removal.—On removing the soft parts, which were found greatly condensed and thickened, and riddled with sinuses, the femur was found, as to its lower half, in a state of chronic inflammation. On making a longitudinal section of the bone it was found to present all the typical characters of chronic ostitis. The bone was enlarged by the deposit of new osseous material by the inner layers of the greatly thickened periosteum, and the medullary canal was blocked by similar deposit from the endosteum. No trace of dead bone was visible, and the pathological changes which were proceeding in the bone tended evidently in the direction of hypertrophy and not necrosis, and illustrated well a certain stage in the production of that species of hypertrophy with sclerosis, which is represented so abundantly by specimens in museums of pathology. The mode of production of the enlargement by deposit within and without the bone—by both periosteum and endosteum—is clearly shown; and the modelling process by which the various layers (formed respectively by the endosteum, the

Digitized by Google

original shaft, and the periosteum) could have been ultimately fused into one had already commenced.[1] *October 19th*, 1880.

---

8. *Ostitis deformans.*

By FREDERICK TREVES.

THE patient brought before the Society is a woman, E. W—, 48 years of age. Her mother, six years before her death, was crippled with rheumatism; but with this exception her family appear to have been healthy, long-lived, and free from any forms of hereditary disease.

The patient's personal health has always been remarkably good. She has never had rheumatism, nor any serious illness. She has had twelve children and two miscarriages. The twelfth child was born when the patient was 44 years of age, *i. e.* after she had developed evidences of the bone affection. This child was very delicate, suffered from a severe form of rickets, never walked, and died when two years and two months old. Four other children have died; they were among the earlier pregnancies, and all died in infancy. In two of the surviving children, born when the patient was respectively 28 and 35 years of age, there were some slight evidences of rickets. With these exceptions all her family have been remarkably healthy. Patient is still menstruating. Some five years ago patient began to be troubled with aching pains in her legs after walking or prolonged standing; her legs felt weak and—as she expresses it—unable to carry her. The pain was not considerable and only observed after exercise, being quite absent at night and when she was resting. Four years ago patient's sister drew her attention to the fact that her left shin was growing out. She then observed, for the first time, that the lower part of the left tibia was more prominent than the right. As, apart from the sensation of weakness and the occasional pains, she suffered no inconvenience and enjoyed perfect health, she consulted no medical man, and only came to the London Hospital for advice in April last. Since that

[1] See paper by the author 'Trans. Roy. Med. and Chir. Society,' 1877, vol. lx p. 192.

Digitized by Google

time she has been under my care, and her condition has but little, if at all, changed during that period. The following is her present condition :—Patient's height is 5 feet 4 in. ; her complexion is fair; she is well nourished and enjoys good health ; she has not lost flesh ; her teeth are sound and regular, and she remarks, as a curious fact, that about six years ago the upper lateral incisors broke off, although apparently quite sound ; she has lost four molars from caries ; digestive functions good and urine normal ; she has not been exposed to cold or damp. Patient complains of not being able to walk far ; her legs feel weak and inclined to give way, and exercise now causes so much pain in the limbs that she cannot comfortably walk more than half a mile.

The left tibia is much bent forwards, especially at its lower part, and is so greatly increased in size as to give her leg an unwieldy appearance. There is a tendency also to slight outward curvature. The bone feels smooth, the adjacent soft parts healthy, and there is no tenderness on pressure. The width of the inner surface of the left tibia, so far as it can be measured through the skin, is from 2⅛ to 2 inches. The right tibia presents a somewhat similar change, although much slighter in degree ; the circumference of the limb at the middle of the calf being 13½ inches as compared with 15½ inches in the left leg. The width of the middle of the inner surface of the right tibia is 2 inches. The bone is therefore much increased in size, but the degree of curvature very slight at present. The right femur is greatly increased in size, and is bent forwards and a little outwards, especially at its lower and middle parts. The left femur appears to be unaltered, but the left tibia bends outwards so sharply just below the knee as to produce the appearance of a peculiar but slightly bowed leg. The patient states that the size of the limbs is less in the morning and after prolonged rest in the recumbent posture ; they have never been œdematous. She has no enlarged veins to be seen on the lower extremities ; the inguinal glands are not obvious ; the muscles appear well developed.

Her mode of progression has been much impaired ; she considers the right limb to be shortened, and walks clumsily, dropping the pelvis on the right side at every step, and turning the left foot out a great deal as it is brought to the ground. These defects in walking are becoming more marked. Both ulnæ are prominent ; the right bone is decidedly thickened, and has a prominent posterior curve, giving the bone a clumsy appearance. No changes are obvious

Digitized by Google

in other bones. The skull is evenly enlarged, square and flattened at the vertex; the frontal eminences are prominent. She has of late years commenced to stoop a little, and this stoop is associated with some bending of the spine in the upper dorsal region. She states that her friends have remarked that during the last year or so she has actually decreased in height, a decrease she estimates at about three or four inches. The resemblance of the case to those described by Sir James Paget is, in its chief features, so precise that I presume that it might be regarded as a good example of the disease he has named osteitis deformans. *December 7th*, 1880.

---

9. *Sarcoma of the lower extremity of the femur extending into the knee-joint, and simulating destructive disease of the joint.*

By Frederic S. Eve.

A young woman, aged 25, was admitted into St. Bartholomew's Hospital, April 7th, 1881, under the care of Mr. Willett. The right knee-joint was hot, tender, tense, swollen, and there was a well-marked prominence on the outer side of the joint, having the appearance of an abscess about to point. The leg was flexed. Four months before she struck her knee, and subsequently the appearances of inflammation of the joint showed themselves.

The swelling of the joint and about the lower end of the femur increased rapidly, and after a time it became evident that the enlargement was due to the growth of a tumour. Amputation through the middle of the thigh was performed.

A section through the lower extremity of the femur showed a soft, brain-like growth originating in the cancellous tissue, which had completely destroyed the external condyle, and protruded as a fungating mass into the knee-joint, infiltrating the synovial membrane and the ligaments. The cartilaginous covering of the external condyle alone remained.

Histologically the growth consisted of round, closely crowded cells and nuclei, with occasional strands of spindle-cells.

The chief interest of the case lay in the close similarity which the disease at first presented to disease of the synovial membrane,

Digitized by Google

and in the history of an injury preceding the development of the morbid growth, which rendered the diagnosis still more difficult.

May 17th, 1881.

---

10. *Symmetrical exostoses of the inferior maxilla.*

By Frederic S. Eve.

The specimen was found in a churchyard, it is evidently the lower jaw of a young person, since the "wisdom" teeth have not yet appeared. Two symmetrical eburnated exostoses spring from the inner surface of the alveolar portion of the bone on either side of the symphysis, corresponding in position to the bicuspids and first molar teeth. The markings and slight lobulations of the bony outgrowths are also more or less symmetrical. The rami of the jaw are unusually widely separated.

The specimen is preserved in the Museum of St. Bartholomew's Hospital, No. 3257.

November, 1880.

---

11. *Case of long retention of the ivory pegs in Dieffenbach's operation for pseudarthrosis.*

By W. Anderson.

[With Plate XX.]

The following case of pseudarthrosis, treated by a modification of Dieffenbach's operation, is of interest, as showing the conditions under which the ivory pegs used to stimulate the osteoplastic process may become permanently retained in the tissues.

The brief account of the clinical history is extracted from notes taken by the Surgical Registrar of St. Thomas's Hospital. The case was under the care of Mr. Sydney Jones, to whose kindness I am indebted for permission to report upon the specimen produced.

The patient, a man aged 33, was admitted into St. Thomas's Hospital on the 12th of May, 1880, for an ununited fracture of thirteen months standing in the upper third of the humerus.

Digitized by Google

Digitized by Google

Fig II.

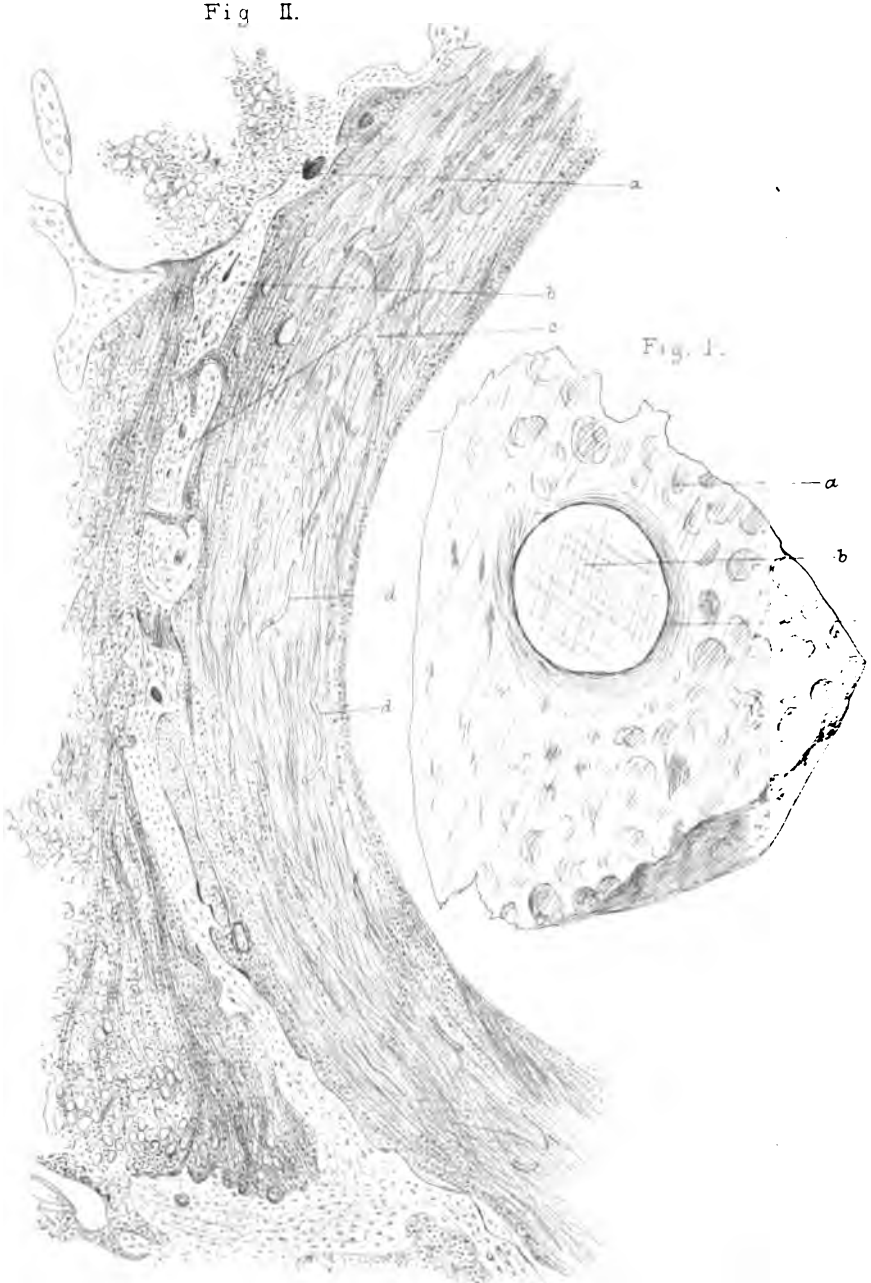

Digitized by Google

DESCRIPTION OF PLATE XX.

Illustrating Mr. Anderson's Case of Long Retention of Ivory Pegs, and showing Encapsulating Material embracing buried Ivory Peg used in an operation for Pseudarthrosis of Humerus.

FIG. 1.—*a*. Condensed bone surrounding peg. *b*. Section of ivory. *c*. Fibrous ring. (Magnified 4 diameters.)

FIG. 2.—*a*. Medullary tissue. *b*. Portion of bony ring. *c*. Fibrous encapsulating material. *d*. Vessels. (Magnified 30 diameters.)

From Drawings by Mr. Anderson.

Digitized by Google

Digitized by Google

On the 19th of May the fracture was exposed, under antiseptic precautions, and, after the removal of a portion of the soft, atrophied ends of the fragments, two ivory pegs of about an inch and a half in length were driven into apertures drilled in the opposed extremities of the bone. The incision was closed and the upper arm was unmobilised in a plaster splint. The case went on well, and at the end of three weeks the wound had completely cicatrised, closing in the pegs.

On examination at the end of June union was found to be unsatisfactory. The loose extremities were rubbed together, and a new splint was applied.

On the 13th of September, nearly four months after the first operation, as no improvement had resulted, a portion of bone with the lower peg was excised. The ends of the fragments were then connected by means of thin wire, and the arm was again put up in plaster. The upper peg was left undisturbed.

At the end of the year the fracture was still loose. The piece of ivory left in the tissues had set up no irritation.

On examination of the specimen removed in September, the following condition of the structures was revealed:

The osseous tissue had undergone considerable hyperplasia, and was now of more than normal density, but in the immediate contiguity of the peg it was replaced by a ring of rather dense fibrous tissue, which tightly embraced the foreign body, and had apparently formed portion of a complete capsule. The ivory, when withdrawn, showed no signs of having suffered loss of substance during the four months of its retention in the tissues, and no line of demarcation was perceptible between the portion that had been fixed in the bone and that which had projected beyond into the soft parts.

Histologically, the elements of the condensed bone were normal. The encapsulating material appeared in a section made at right angles to the line of the ivory peg, as a zone of $\frac{1}{30}$th of an inch in depth, formed of immature fibrous tissue, tunnelled by large, thin-walled vessels, and intermingled, especially in the neighbourhood of the peg, with area of cell growth. The bone immediately bounding this structure formed a narrow ring, perforated by vascular channels, and connected with the adjacent osseous structure by means of processes of various shapes (see drawing). The minute structure of the ivory was unaltered.

The process seen to have taken place around the ivory peg, a

Digitized by Google

kind of encapsulation similar to that which may isolate the foreign bodies embedded in the tissues, is probably not new in connection with Dieffenbach's operation.

The procedures of the operation have been considerably modified by the surgeons who have followed the inventor. Dieffenbach, inspired by the observations of Flourens and Duhamel as to the hyperplasia set up by foreign bodies, such as bullets, when lodged in bones, merely used the pegs as a convenient form of local irritant, and removed them as soon as they had induced a certain amount of action, generally at the end of ten or twelve days; other operators, however, have left the pegs to be thrown off by suppuration, or have not extracted them until many weeks after their introduction, and in some cases have allowed the soft parts to heal over them. In Mr. Stanley's well-known case ('Lancet,' 1851, vol. ii), one of the pegs used was discharged spontaneously two weeks after the operation, apparently none the worse for service. In Mr. Bowman's case ('Lancet,' 1852, vol. ii), one peg was expelled at the end of two months, and is described as "eroded," a second, removed a few days later, carried with it a small sequestrum. In several other cases the expulsion or removal of the pegs is mentioned, but unfortunately all description of the condition of the material is omitted. Nearly all of the recorded examples of cicatrisation of the wound over the pegs were instances in which healing had been preceded by a period of acute inflammation. In Mr. Stanley's case, three out of four pegs were so covered in after profuse suppuration, and a second operation was performed two months after the first for the purpose of removing them. It was then found that the extra-osseous portion of each peg was apparently unaltered, while the extremity that had been driven into the bone had almost entirely disappeared. The aspect presented by these disinterred pieces of ivory is generally quoted as representative of the changes to which the substance is liable if retained for a sufficient length of time. In Mr. Bowman's case, two out of four pegs were buried by the healing of the operation wound; and in a case of Mr. Erichsen's, two pegs were in like manner enclosed. Two cases are reported by Dr. Heine (von Langenbeck's 'Archives,' 1878), in which broken extremities of pegs were left in the bone, the wound subsequently healing over them; and in another case, by Bergmann, of Dorpat, one peg inserted in such a way as to nail together the opposed ends of the fragments was presumably also retained, as nothing is

Digitized by Google

said as to its removal. In all of these examples, however, with the exception of Mr. Stanley's, the ultimate fate of the foreign material after its concealment by the cicatrisation of the superficial tissues can only be conjectured. The present case, and another to be hereafter referred to, indicate that encapsulation is a necessary condition for the permanent toleration of the substance by the living structures. Billroth, however, in alluding to the subject, seems to imply that the pieces of ivory so retained become in time completely dissolved by granulations, and his view is apparently supported by the disappearance of so large a portion of the pegs in Mr. Stanley's case, but in this instance the disintegration may have taken place, and probably did so, during the long suppurative process preceding cicatrisation, and ceased with the healing of the wound.

The operation now under notice is one of the few in which complete antiseptic precautions have been used, and it is probably to the resulting limitation of the inflammatory action that we may attribute the rapid encapsulation of the foreign body.

Another somewhat similar case was brought forward by Professor Trendelenburg at the Surgical Congress at Berlin in 1878 ('Verhandlungen der Deutschen Gesellschaft für Chirurgie,' 1878). The patient, a man aged 56, was suffering from an ununited fracture of the femur of nineteen weeks' standing, involving the lower extremity of the bone, and extending into the knee-joint. The lesion was exposed under partial antiseptic precautions (spray omitted), and a long ivory peg was inserted into a hole drilled through the opposed bony fragments. The wound closed quickly, but about four weeks after the operation a small abscess appeared over the back of the thigh. The resulting sinus subsequently healed, shutting in the ivory, and firm union of the fracture followed. I have lately learned from Mr. MacCormac that the death of the patient from internal disease a few months since, and about eighteen months after the operation, has allowed an examination of the parts, the condition of which is to some extent shown in the sketch. The fracture was firmly united; the ivory peg was found *in sitû*, but had been divided, at a line corresponding to the surface of the femur, into two portions, one remaining embedded in the condensed bone, the other lying in the soft parts. Judging from a hasty examination of the specimen, and from the representation in the drawing, the material appeared to have undergone no further change. Full details have

Digitized by Google

not yet been obtained, but the facts stated are sufficient to prove the possibility of long retention of the pegs in the tissues, without the occurrence of irritation in the adjacent parts, or sensible change in the foreign material. There is little doubt that toleration was here established by means of encapsulation, as in Mr. Sydney Jones's case.

With regard to the influence of the application of antiseptic surgery to this operation, there is every reason to believe that Listerism would diminish the danger, and would favour the process of encapsulation of the pegs; but a question may be raised whether the reduction of local irritation so secured would interfere with the attainment of the desired end — whether rapidly established "toleration" of the foreign body would so far limit the amount of new bone-formation as to diminish the prospects of union. In the present case considerable osseous hyperplasia was induced, but it would not be easy to say how far this result was attributable to the exposure, drilling, and sawing, forming a part of the first operation, and to the friction process that succeeded it. Professor Trendelenburg's case had a prosperous issue, but the circumstances were in some respects far more favorable, as the fracture was of comparatively recent date, and its situation and direction allowed the apposition of extensive bony surfaces; there was, moreover, evidence of a certain amount of active irritation in the part for some weeks after the operation, and it was probably during this period that the partial absorption of the peg and the formation of new bone took place. *May 17th*, 1881.

---

12. *Tubercular disease of synovial membranes, and tubercular disease of joints.*

By JOHN CROFT.

[With Plates XXI, XXII, & XXIII.]

IN the adjoining room are exhibited microscopical preparations from six cases of diseased joints, these consist of three cases of hip-joint disease, two cases of knee-joint disease, and one of disease

Digitized by Google

Digitized by Google

Trans. Path. Soc. Vol. XXXVI. Pl. XX.

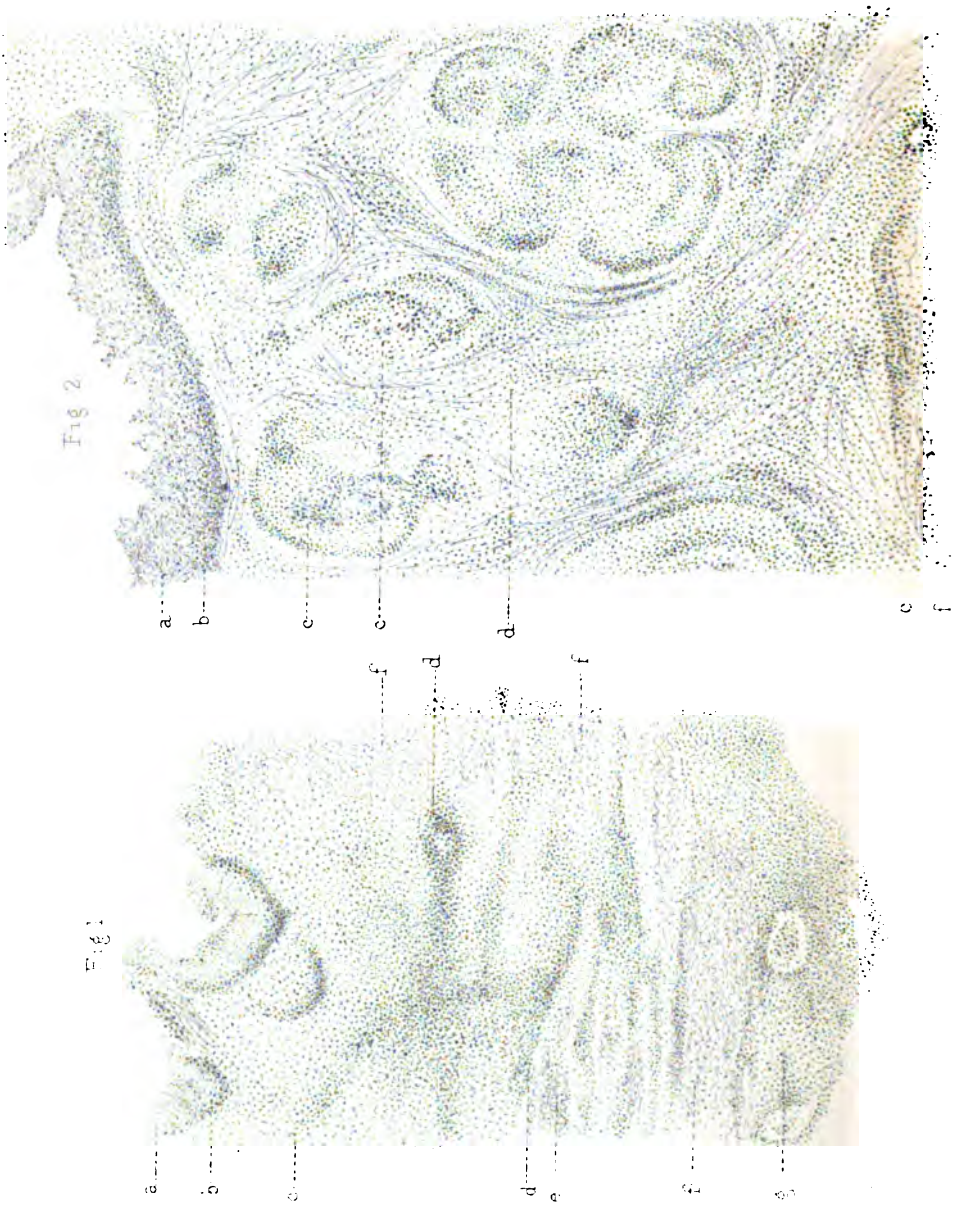

Fig. 2

Fig. 1

W. Anderson del.

Mintern Bros. lith.

Digitized by Google

Digitized by Google



Fig 1

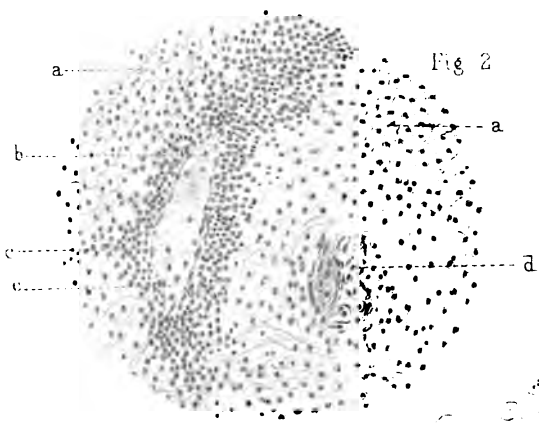

Fig 2



Fig 3

Digitized by Google

DESCRIPTION OF PLATES XXI AND XXII.

Illustrating Mr. Croft's paper on Tubercular Disease of Joints.

PLATE XXI.

FIG. 1.—Case of Pennett. *a, b.* Superficial stratum consisting of granular amorphous material (caseating mass) resting upon a layer of densely aggregated cells. Some cells have made their way from the aggregation through the caseating mass to the surface. *c.* Layer of granulation tissue. Cell forms most numerous in places parallel with the surface. *d.* A rudimentary tubercle follicle. *e.* Tissue of fibro-cartilage; interlaminar spaces show planes of cell growth.

FIG. 2.—Case of Pennett. *a, b.* Superficial stratum as in 1. *c, d.* Tubercle follicles embedded in granulation tissue. This specimen shows the tubercle follicle in various stages of formation, commencing as a somewhat circumscribed cell aggregation of spherical or ovoid form, without special differentiation of elements. With increase of age and growth the more central portion of the collection under the influence of imperfect nutrition undergoes retrograde changes terminating in caseation, and commonly producing in transition the phenomenon of "giant cells." The region of tubercle follicles and granulation tissue is non-vascular. *e.* Vessel at junction of granulation layer with *f.* tissue of fibro-cartilage.

PLATE XXII.

FIG. 1.—Portions of superficial stratum, highly magnified (× 500). The deepest portion of the stratum is seen to consist of cells of granulation type. Some of these tend to assume an elongated form and insinuate themselves through the caseating material to make their appearance upon the surface. The caseating mass is seen as a *débris* in which, on close examination, vestiges of effete cell forms are still distinguishable. This stratum appears to correspond in origin to the tubercle follicle, and may be looked upon as an open follicle, if the expression be allowed; the area of caseation, instead of being enclosed by the cell layer, lies on the free surface of this, and owing to its different relations, shows no giant-cell structures.

FIG. 2.—Section of portion of the fibro-cartilage showing vein and artery. *d.* Artery-lumen almost obliterated by contraction of the walls. *b.* Vein. The surrounding tissues infiltrated with leucocytes. Some white corpuscles appear to be in the act of passing through the interstices of the endothelial coat.

FIG. 3.—Portion of centre of a tubercle follicle, highly magnified (× 600), showing "giant-cell" structure; the appearance is that of a number of nuclei embedded in a granular amorphous mass, which at its periphery is continuous with the intercellular retiform tissue of the more highly vitalised cell layer of the follicles. The nuclei present three peculiarities: firstly, they are nearly all elongated, contrasting with the more spherical forms lying at the margin of and outside the follicle. Secondly, they show for the most part indications of a progressive diminution in their power of fixing colouring matter; some are as deeply tinted as the granulation tissue nuclei, but the greater number are paler, and many are so indistinct as to require careful focussing for their detection. Thirdly, they have lost their proper protoplasmic envelopes, except in the case of a few of the more outlying examples. The protoplasm, and probably many of the nuclei themselves, have apparently melted into the substance forming the original intercellular material, and now constitute the basis matter of the "giant cell."

From Drawings by Mr. Anderson.

Digitized by Google

Digitized by Google

Digitized by Google

Fig 1

Fig 2



Fig 3.

Fig 4

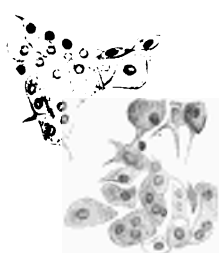

Fig 5

Digitized by Google

DESCRIPTION OF PLATE XXIII.

Illustrating Mr. Croft's paper on Tubercular Disease of Joints.

FIG. 1.—Case of Roach. Hip-joint. Synovial membrane. Part of a tubercle follicle, showing giant-cell growth and tubercular infiltration.

FIG. 2.—Case of Fiddler. Section from head of femur. *a*. Osseous trabeculæ. *b*. Tubercle granulation containing giant cells. *c*. Fat cells of marrow.

FIG. 3.—Case of Roach. Hip-joint. Synovial membrane. Tubercle follicle, showing giant cell and branching stroma.

FIG. 4.—Case of F. Roche. Hip-joint. Synovial membrane. Epithelioid cells from interior of a tubercle follicle in early stage of growth.

FIG. 5.—Case of Powell. Knee-joint. Synovial membrane. Giant cell from margin of caseous zone of tubercle in synovial membrane.

Drawings by Dr. Greenfield.

Digitized by Google

Digitized by Google

of ankle-joint. All these specimens show tubercle in various stages, more or less perfectly. Beside them is one preparation from a diseased hip-joint, which shows granulation tissue without tubercle; that is taken from the round ligament.

I would premise that in speaking of tubercular disease or tubercle, I mean the new growth which histologically presents in its younger form small-celled growth surrounding epithelioid cells (or intermediate cells), and giant cells, and more or less of a delicate reticulum. The growth is devoid of blood-vessels, and leads to caseation in its older forms.

I would premise, also, that the cases to which the six exhibited specimens belong were marked by some peculiarities which distinguished them from cases of common simple inflammation, such as tedious progress, hyperplasia, or white swelling, formation of abscesses yielding caseous pus, and delicate general health.

I must beg leave, too, to say that I do not bring this subject forward because I have a large array of facts. It is because facts *are wanting* on this particular subject that I venture to come before you.

If I succeed in showing the necessity for our examining into the subject of tubercle as it affects joint structures; if I succeed in stimulating my fellow surgeons, particularly the younger ones, to report facts with regard to the question, then I shall have successfully commenced a work which I shall hope will bear good fruit at a future season.

I have been greatly assisted in this piece of work by my colleague Dr. Greenfield, and by our pupil, Dr. Mercer, of Syracuse (United States). Dr. Mercer was an assistant of Dr. Greenfield's at the Brown Institution, and took great trouble to make the microscopical preparations under Dr. Greenfield's instructions. I feel that I owe these gentlemen at least public thanks for their able assistance and kindness.

The stock preparations had been in pickle for some years.

Cases.

The first case is that of a man, aged 20, who had suffered from symptoms of synovial disease of the knee-joint with effusion for three months. The leg was amputated. Tuberculosis of the

Digitized by Google

synovial membrane exclusively was found. He died thirteen months afterwards of symptoms of intestinal phthisis. His grand parents had been consumptive.

Next are three cases of chronic hip-joint disease in children of 4, nearly 6, and 12 years respectively. One had suffered for six months, one for nearly one year, and the third for nearly two years. The two last cases were subjected to excision. The girl, who had suffered for two years, was a well-marked instance of tuberculosis of articular bone. She died of tubercular meningitis. The boy, aged 12 years, died of rapid tuberculosis. He was not operated on. He died of miliary tubercle in various organs and tissues. In two of these children, near relatives were consumptive; in the other the history was doubtful.

The fifth case was that of a young woman, aged 20, who had suffered disease of the knee-joint for at least two years. The joint was excised, and she died from the effects of the operation, being already the subject of tubercle in the lungs and spleen, which had been overlooked. The chest had been previously examined by a physician. The family history as to phthisis was imperfect.

The sixth case was one of chronic disease of the ankle-joint in a girl aged 8 years. The disease had been in progress for three years and four months. The joint was excised freely. Tubercle was found in the sub-synovial tissue. The grand parents were consumptive.

Four of the six were ascertained to belong to consumptive and scrofulous families. In the other two the reports were, unfortunately, imperfect.

The report on the microscopical examination of the parts removed from the joint are of chief interest, and I will now read them.

Dr. Greenfield has kindly drawn them up.

Arranged in order of interest they take the following sequence:

1. Tuberculosis of synovial membrane exclusively (Pennett, knee).
2. Tubercle in bone and synovial membrane (Wm. Roach, hip).
3. Tubercle in synovial membrane (F. Roche, hip).
4. Tubercle in synovial membrane (Powell, knee).
5. Tubercle (Waller, ankle).
6. Tubercle in articular bone (Fiddler, hip).

Dr. Greenfield's report is so concise and condensed, that I must

Digitized by Google

beg permission of the Society to read it as he has arranged it. An abstract would fail to do it justice.

CASE 1. *Knee-joint.* — Pennett. I. First series of sections through the semilunar cartilage and a mass of fungating granulations growing from it (see Plates XXI, XXII).

The outline of the fibro-cartilage is distinct at the lower part, and its structure there appears unaltered. On the upper surface there is a mass of granulation tissue more than half an inch in thickness, from the edge and free surface of which vegetations project, some being polypoid.

The upper layers of the fibro-cartilage show some signs of inflammation, the fibres are separated by rows of leucocytes. Continuous with this surface is a layer of granulation tissue of ordinary character, which resembles in every respect organising cicatricial tissue, and contains vessels of new formation. This layer of granulation tissue is about half an inch thick, and forms by far the larger proportion of the thickened mass. Towards the surface it becomes somewhat more cellular in structure.

Completely covering it both on the surface and at the edges, and penetrating for a short distance between the granulation tissue and the fibro-cartilage, near the free edge of the latter is a layer of tissue of entirely different structure and abruptly defined. This has the structure usually seen in rapidly caseating tubercular infiltrations. This layer has the following characters:

At the surface, it consists of amorphous granular material containing a few nuclei and the remains of cells (caseating mass).

At the deeper surface, where it is in contact with the granulation tissue, it is limited by a more or less uniform and dense layer of small round cells, which stain deeply with reagents (leucocytes).

In the intermediate layer are seen all grades of rapidly growing and degenerating tubercular granulations. These are as usual made up by the aggregation of small rounded, or ovoid masses (tubercle follicles), united by a more or less perfect adenoid tissue.

Only very few of the tubercle follicles present the perfectly developed typical form. These have the usual characters of one or more multinucleated cells (giant cells), with branching protoplasmic processes which are continuous with a reticulum, formed mainly by branching, flattened endothelial cells, and containing in

Digitized by Google

the interstices rounded, ovoid, and variously shaped cells, with relatively voluminous protoplasm.

In many the reticulum is indistinct. They consist of one, two, or more giant cells, spheroidal or polygonal cells, spindle cells, especially at the periphery, all massed together.

In others, two or three enormous giant cells form the greater part of the mass.

Caseation is common at an early stage, and fibrous change rare.

The caseated follicles have the usual appearance—an amorphous central mass, containing sometimes the remains of a persistent giant cell, towards the edge ovoid or elongated nuclei running outwards and merging in the tissue around.

In some parts of the mass, and especially in torn edges, there are seen as composing the growth many large spheroidal or polygonal cells with a single or double nucleus (so-called epithelioid cells), many large spindle cells with ovoid nuclei and large multinucleated cells.

In fact, in all its characters this layer is identical in appearance with a layer of tubercular infiltration of the peritoneum or of any organ.

Scarcely any capillaries are visible in this layer of the granulations; it is almost entirely non vascular.

II. Second series of sections, through the edge of the articular cartilage and the bone, and a mass of vegetating granulations at the free margin.

The bone and articular cartilage show no marked change.

The structure of the vegetations is identical with that seen in the first series of sections, the deeper layers being ordinary granulation tissue, the more superficial consisting of imperfectly formed tubercular granulations.

In some places the synovial membrane is continuous over the layer of tubercle, and appears but little altered.

Case 2. *Hip-joint.*—William Roach. I. Sections of thickened synovial membrane (Plate XXIII).

The thickened membrane formed a mass about a quarter of an inch in thickness, nearly smooth on the surface. In this could be distinguished a thin deep layer consisting of the remains of the synovial membrane and ordinary granulation tissue, and a superficial somewhat dense layer of *caseous material*, but by far the

Digitized by Google

greater part is composed entirely of a mass of tubercular granulations.

These are extremely typical; the follicles being very well developed, the giant cells and reticulum large and prominent, as seen in the drawings.

There is scarcely any caseation except at the surface, and the growth of the tubercle is orderly and apparently gradual.

In the intermediate tissue between the tubercle follicles a relatively large proportion of newly-formed vessels are seen, and towards the caseating superficial layer, these gradually become blocked by concentric proliferation of their walls which are entirely cellular.

II. Sections of the bone from the head of the femur near the epiphysis. Perpendicular sections of the bone after softening in chromic and hydrochloric acid.

A few gray granulations are visible with the naked eye, in the sections near the surface.

Microscopically they present the same characters as the tubercle in the synovial membrane; they are entirely situated in the medullary tissue, *i.e.* they do not appear to affect the bony trabeculæ (see Drawings).

Case 3.—F. Roche. I. Sections through articular cartilage of head of femur, and a cauliflower-like mass of vegetations on its surface, and projecting at the edge (these formed a ring at the margin of the cartilage (Plate XXIII, fig. 4).

The cartilage itself but little altered, except some small cavities filled with granulation tissue. The chief substance of the vegetations composed of granulation tissue.

At the surface the condition closely resembled that in Pennett's case, viz. superficial caseation, and a layer composed of imperfectly formed tubercular granulations. Here, however, they are even less perfectly formed, and caseation is more advanced.

Many consist merely of masses of epithelioid cells, varying much in size and shape, contained in an ovoid or rounded cavity formed of imperfect lymphoid tissue. Only a few contain giant cells fully formed or a complete reticulum.

II. Sections of bone from the head of the femur show no tubercle.

Case 4. *Knee-joint.*—Harriett Powell. Two series of sections from thickened synovial membrane (Plate XXIII, fig. 5).

Digitized by Google

In one series there is a deep layer of fat which is unaffected. In other respects the two series show very similar changes.

The fibrous layers are swollen and show ordinary inflammatory changes, and upon the surface is a layer of ordinary vascular granulation tissue. Here and there in this layer are seen isolated tubercle follicles.

Superficial to this is a layer of much greater though variable thickness consisting of ordinary tubercular infiltration. Upon the surface of this is a caseous layer of variable thickness.

It is not easy in all parts to distinguish the tubercular zone from the zone of ordinary granulation tissue; the two seeming to shade off into one another in some parts, or the tubercle follicles to be embedded in the layer of granulation tissue. But in the completely formed tubercular zone the structure is very perfectly developed.

Case 5. *Ankle-joint.*—Waller. Sections of a rounded mass of tissue consisting largely of fibrous bands. Owing to imperfect preservation the structure is not well brought out, but there is apparently an infiltration of the tissue with tubercle. In some parts the tubercular structure is very clearly seen.

Case 6. *Hip-joint* (*bone*).—Fiddler. The sections are from the head of the femur, in the same position as in the case of Roach, and they show a similar condition, viz. the presence of scattered tubercular granulations, very few in number, and best seen near the surface of the bone. The periosteum over the one part where it remains shows merely inflammatory thickening (Plate XXIII, fig. 3).

Synovial membrane.—No tubercle was found in any of the sections of the small piece examined.

Case 7.—Webb. Sections apparently of the round ligament somewhat irregularly swollen.

These sections consist entirely of ordinary newly formed young connective tissue, which is highly vascular, and in many places of myxomatous type.

Summary.

It appears from a comparative examination of these specimens from the hip-, knee-, and ankle-joints, that in all the six in which the synovial membrane and bone were examined tubercle was found, whilst in one in which only the thickened round ligament was examined none was present.

Digitized by Google

In the thickened synovial membrane, a combination of common inflammatory changes with tubercular infiltration is present, and usually three zones may be distinguished, a superficial caseous zone, a zone of tubercular infiltration, usually forming a large proportion of the entire mass, and a zone consisting of the fibrous structures of the synovial membrane in a state of chronic inflammation. In the latter zone as well as in the bone, isolated tubercular granulations are seen.

In the articular cartilage in these cases nothing beyond some spaces filled with granulation tissue was seen.

It is of course often a question whether the fungating mass examined is synovial membrane or newly formed fibrous bands, as the structure of the synovial membrane, if present, is quite obscured.

I have not hesitated to call the structure in all these cases tubercular, on the ground that it is identical with that seen in tuberculosis in whatever organ it may be examined, and that microscopically it is indistinguishable from tubercular infiltration of a serous membrane, whilst it is entirely distinct from the ordinary products of inflammation whether acute or chronic.

With regard to the majority of the specimens in which the growth is made up of rounded masses, themselves in turn composed of grouped follicles in which the structure of tubercle, giant cells, reticulum of flattened epithelioid cells, &c., can be distinguished, I suppose there will be little doubt.

But in the other cases where, although the structure is similarly arranged, the follicles contain giant cells and epithelioid cells without definite visible arrangement of reticulated stroma, there may be some who would prefer to call the change scrofulous inflammation.

I have adhered to the term tubercle for these reasons.

1. That the same structure is met with in the rapid growth of tubercle elsewhere. It appears in fact to be a question of completeness of organisation before caseation occurs.

2. That a like condition is found in some parts of nearly all tubercular infiltrations in other organs, and is especially common in some, *e. g.* the spleen and liver.

3. That in the specimens of parts where there are the most typical tubercular granulations, this condition also shows in many places.

Digitized by Google

4. That in other respects these specimens are precisely similar to the unquestionably tubercular, differing only in more rapid caseation.

Additional evidence in favour of this view is found in the fact, that in the case of F. Roche, where this imperfect organisation was most apparent, there was the most extensive tuberculosis of other organs, including tubercular tumour of the cerebellum, and tubercular meningitis, and tubercle in lungs, liver, kidneys, and peritoneum.

Having put before you the facts of these cases, I would add some remarks, and have arranged them under seven headings.

1. Are these cases of tubercle and not of simple chronic inflammation?

2. What light do these cases throw on the question of tubercle being a primary disease, or one secondary to chronic inflammation?

3. How do these cases bear on the question of local caseous inflammations becoming the foci from which systemic infection takes place?

4. Premising that these are cases of tubercular disease involving caseous nests, does this bear on the subject of the surgical treatment of such cases?

5. Are there grounds for stating that a class for primary tuberculous synovial disease should be erected?

6. Are there grounds for stating that a class for tubercular arthritis should be erected?

7. Frequency of tubercular disease of synovial membrane and joints?

1. Are these cases cases of tubercle and not of chronic simple inflammation?

No one can doubt that they are cases of tubercle, when to the microscopical appearances in each case are added the clinical and family history. If chronic, simple inflammation exhibits such histological changes and appearances (which I do not admit) then instances of tubercular pulmonary disease, tubercular peritoneal disease, tubercular disease of testis, tubercular meningitis, possess no features to distinguish them from common inflammations.

2. What light do these cases throw on the question of tubercle being a primary disease, or one secondary to chronic inflammation?

Digitized by Google

This question is one of great interest from the pathological point of view as well as from a clinical one, and I wish that the evidence were positive. It seems impossible to demonstrate certainly that no inflammatory movement whatever preceded the growth of tubercle in any given case. Indeed, from the history, from the cause assigned in each case in which the joint affection was primary in point of time to the growths in other parts of the body—from the cause assigned in such cases, cold, or slight injury, or scarlet fever—the presumption would be that the cause set up a slight inflammatory change and the tubercle followed. How soon tubercle began to grow it is also difficult to guess.

3. How do these cases bear on the question of local caseous inflammations becoming the foci from which systemic infection takes place?

In five out of six cases, viz. Pennett, Roach, Frank Roche, Waller, and Fiddler, there is no reason to suspect from the previous symptoms that there was any other disease in the body when the symptoms of joint disease first manifested themselves. In other words, there were not any already existing caseous foci. The joint affection constituted the primary lesion in these five cases. In the sixth, that of Powell, it may be presumed that the caseous glands in the mediastinum containing cretaceous material were of older date than the joint affection, which had lasted two years. I cannot speak positively about this. Roach and Waller are living, the former is improving in health, and the latter is quite well. Pennett, Roche, and Fiddler died from tuberculosis of other organs, viz. intestines, pia mater, peritoneum, and lungs. These cases bear directly on the question, and would lead one to think that the local caseous inflammations which are shown by the gross morbid anatomy and the microscopical preparations did prove to be the foci from which systemic infection took place.

4. Premising that these are cases of tubercular disease involving caseous nests, does this bear on the subject of the surgical treatment of such cases?

The few cases which I show here this evening and the clinical character of the question suggest that I should not attempt to answer the question here. Nevertheless, I would ask (*a*) if it be true that tubercle is not vascular, and is incapable of undergoing development or organisation and (*b*) if it be true, as is very generally

Digitized by Google

admitted, that caseous foci are possible sources of tubercular infection of the lymphatic or vascular systems, is not a relatively early removal of caseous foci and tubercle growths indicated?

5. Are there grounds for stating that a class for primary tubercular disease of synovial membrane should be formed?

Professor Volkmann admits the existence of a primary synovial tubercular disease, but states that it is far more rare than the secondary form, is almost confined to adults, and is always due to primary tuberculosis of the synovial membranes. The cases in which it occurs are the most unfavorable. The inflammation of the joint assumes a marked purulent character, there is great disorganisation of the articular tissues, and the patients generally die of phthisis or of tuberculosis of the bowel. In this I thoroughly agree. The case of Pennett, which I have already given, is an instance of this description. I have notes of two (at least) other cases, but as I cannot show microscopical preparations from them I think I must forbear giving them. Messieurs Cornil et Ranvier describe this form of tuberculosis as a special class. These authors write that Virchow only mentions this form, that Köster had collected a certain number of cases but had not published them. Drs. Wilks and Moxon give a case of tubercular disease of synovial membrane, and add that similar cases have been recorded by other observers. Perhaps I ought not to say positively, that there are grounds for making a class for tubercular diseases of synovial membrane, yet I cannot help thinking that there should be such a class. If surgeons would look over their note-books, they would recall cases the symptoms of which were similar to Pennett's more or less precisely, and which ended fatally somewhat later by consumption in one form or another. I trust that this paper may have the effect of leading our more active and energetic (perhaps younger) brethren to look for tubercles in any suspicious cases, such as Pennett's, and such as those referred to by Professor Volkmann.

6. Are there grounds for stating that a class for primary tuberculosis of joints should be formed?

I think that the question and the following may be answered together.

The 7th query is:

7. With regard to the frequency of *tubercular disease of synovial*

Digitized by Google

membrane and bone of joints. This leads one to say a few words on the existing classification of joint diseases in the English text-books on surgery. As this is a pathological subject perhaps I may be allowed to say a few words.

Mr. Erichsen makes a class which he has called chronic strumous arthritis. He does not describe tubercle as occurring in the synovial membrane, but states of the articular bone that "in some cases tuberculous matter is deposited in it, and it is that that gives rise to the vomica and circumscribed abscesses."

Under the head of pathology of hip disease, a case is given which occupies the whole paragraph. A child in University College Hospital, about eight years of age, died of pneumonia, under Dr. Hare's care. That child was said to have suffered for six weeks only from hip disease. Dr. Wilson Fox made a careful *post-mortem* examination of the diseased structures of the hip-joint, and found miliary tubercle in the sub-epiphysial portion of the femur, but none in the synovial membrane. Dr. Wilson Fox has kindly shown me the notes of that case, as I felt very curious to know whether tubercle had been found in the synovial membrane.

That is the only case of tuberculous arthritis described by Mr. Erichsen, and as it fills the whole of the chapter on the pathology of hip-joint disease, it must have made a strong impression on the author's mind. Nevertheless, no chapter is devoted to tubercular disease of joints.

Mr. Erichsen describes what has been called strumous disease of joints, but he does not lay down that tubercle is an essential element in such disease. From a comparison of his definition of tubercle and struma, I cannot understand that the two designations mean the same thing.

Mr. Holmes, in his work on 'Surgery,' does not give a chapter to tubercular disease. Tubercular disease of synovial membranes is not mentioned. Tubercle in bone is described in the chapter on diseases of articular ends of bones; it is spoken of as crude tubercle, though the appearance of this, he says, is in his experience very rare.

Mr. Holmes deprecates the use of the term "strumous." In defining tubercle and struma, Mr. Holmes adopts Rindfleisch's views. According to this scrofula or struma is the constitutional diathesis which leads to, or tends to, lead to the deposit of a substance called tubercle.

Digitized by Google

Mr. Holmes does not give any descriptions of microscopical examinations of diseased joint structures.

Mr. Bryant, in his 'Practice of Surgery,' does not dispute the fact that at rare intervals we do find tubercular deposit in some of the tissues building up a joint and particularly a bone, but I must repeat, he says (1879 edition), what I wrote many years ago in my work on 'Diseases of Joints,' "that such preparations being so rare are to be regarded as pathological curiosities. They are discovered, also, accidentally, and cannot clinically be recognised by any characteristic features from other cases of chronic inflammation of bone.

Under the head of "Pathology of Hip Disease," this same writer states: "It may also be repeated that it is a very rare thing to find strumous or tubercular matter in a diseased hip-joint."

I have said enough to show that none of the three leading text-books on surgery devote a paragraph or a class to tubercular disease of the synovial membrane exclusively, or to tubercular arthritis.

Turning to works on pathology, I will first quote from Dr. Wilks and Dr. Moxon's work. Dr. Moxon writes that "in January, 1870, he examined a knee-joint which had been removed for caries of the head of the tibia, and that it showed tuberculous ulceration of the synovial membrane in a most interesting way. Lenticular ulcers, of a size from millet seed to hemp seed, being distributed closely and regularly over the synovial membrane, which otherwise was little altered. The joint was only secondarily implicated in the disease. This, however, although it suggests, yet would not prove such tubercles to be present when the knee-joint is the primary seat of the disease."

Dr. Moxon adds, "Similar cases of tubercle in the synovial membrane have been recorded by other observers."

This case is one of the very few found recorded in our literature. It seems a very astonishing statement, but it is nevertheless true.

In the 'Transactions' of this Society, the only records accompanied by microscopical examinations are those by Mr. Rickman Godlee and Mr. J. H. Morgan, in the 'Transactions' for 1877 and 1879. The title of the former's paper is "Granulation Tissue from White Swelling of Knee."

A boy, aged four and a half years, suffered from acute white swelling of the knee-joint. The length of his illness is not given.

Digitized by Google

The advance of the disease was very rapid, and the joint with the limb was amputated. The boy died on the eighth day from septicæmia. No tubercle was found anywhere in the organs. The bones of the joint seemed healthy, so the report says, but apparently no microscopical examination was made.

The granulation-like tissue over the cartilage of the femur was submitted to microscopical examination. Giant cells, reticulum, nucleated cells of various sizes, and free nuclei were found. Dr. Godlee calls this structure identical with adenoid or cytogenous tissue, and says that the circular arrangements are absolutely identical with what was at one time considered to be special to the growth of tubercle. Mr. Godlee's opinion was that unless "one is to maintain that we are dealing with actual tuberculosis of the synovial membrane of the joint, we are almost driven to the conclusion that this complicated structure has nothing special about it, but simply represents a very lowly organised form of inflammatory tissue.

The case was not studied by the help of the clinical history. The family history could not be obtained as the parents were rovers. Yet its aspect led the surgeon to see that it was not a case of ordinary inflammation of the joint.

I cannot doubt that it was a case of rapid tubercular disease of the synovial membrane following catarrhal inflammation.

I now turn to French and German pathologists. Messieurs Cornil et Ranvier, in their 'Manual of Pathological Histology,' devote a very short page to tubercle of the synovial membrane. They refer to it as a neoplasm of the synovial membrane which is *common but has not been sufficiently described.* They say (1869) that the arthritis which accompanies and follows this tubercular disease has been confounded with scrofulous arthritis. They think the two affections are distinct. The symptomatology of tubercular arthritis had to be worked out.

König, of Gottingen, has communicated an article on "Tuberculosis of Joints," to the 'Deutsche Zeitschrift,' 11th volume. He had examined 71 cases of joint disease, and found by microscopical investigation that out of the 71 cases tuberculosis existed in 47. Primary tuberculosis in *bone* was more common than in the synovial membrane.

At a meeting of the German Surgical Society at Berlin, in the early part of last year, speaking in a discussion on the "Results of

Digitized by Google

excision of tuberculous joints," König refers to 117 excisions for tuberculous disease.

Bidder, in a paper on "Early Excision of Fungous Disease of Hip-Joint," in the 'Centralblatt für Chirurgie,' Nov. 29, 1879, describes two cases of tubercular disease of the synovial membrane and bone.

At a discussion on tuberculosis in the Vienna Medical Society ('Mediz. Jahrb.,' 1880, Heft. iii), Professor Billroth reported 713 cases of *tumor albus* occurring during a sixteen years' experience. Billroth stated that 181, forming 25·3 per cent., had died of phthisis, and 15, or 2·1 per cent., with miliary tuberculosis of meninges of brain. In these cases there were cheesy centres in the bones, and these he believed to result from miliary tubercles and to be the origin of the general disease. Here then are 713 more cases of tubercular disease of joints, making in all 832 cases.

Volkmann, of Halle, is a well-known investigator in this direction and a most skilful surgeon. He published a set of clinical lectures in 1879 on "The Character and Interpretation of the Fungous Inflammation of Joints." An abstract and translation of these lectures appeared in the 'Med. Times and Gazette,' of November 8th, 1879. I quote from that. The joint affections of which Volkmann wrote include hip-joint diseases, tumor albus, and scrofulous inflammation of joints, to which Billroth has assigned the term "fungous." He shows that his clinical experience, founded on the examination of large numbers of very early cases of this diseased condition, excised and treated antiseptically, is opposed to the ordinary view of their pathology, or, at any rate, of the process underlying their initial stage. According to Volkmann the disease does not begin in the synovial membrane; it begins in the bone itself, and is throughout of a tubercular character. He admits the existence of a primary tuberculosis of synovial membrane, though it is relatively rare. Here again we have a statement of a great number of cases investigated and proved to be of a tubercular character.

Are English surgeons wrong and German surgeons right? Is tubercular disease of the joints more common than we have supposed?

I exhibit to the Society this evening a small contribution of six cases, the result of the examination of a few excision cases, and I have collected four cases from our literature, one described in Erich-

Digitized by Google

sen's Surgery,' one in Drs. Wilks and Moxon's 'Pathology,' and two from the 'Transactions.'

I venture to hope that we shall ere long have more facts brought to bear on this question with regard to the frequency of tubercular disease of the joints and synovial membrane, and be enabled to give a positive answer that tuberculosis of synovial membrane and tuberculosis of joints should be erected into two distinct classes. *February 15th*, 1881.

Note (November, 1881).—The parts from *twelve* other cases of disease and excision of the hip-joint have been examined and found as *tubercular* as those cases described in the paper.

An independent and extended examination has been made of Hector Webb's case, and its non-tubercular nature confirmed.—John Croft.

---

13. *Case of tubercular disease of the elbow-joint.*

By G. H. Makins.

The specimens were obtained from a case of synovial disease of elbow-joint, of nine months' standing, occurring in a stone-mason aged 42.

The joint was excised three weeks after the patient's admission into the hospital. The interior of the joint was loaded with proliferating granulation tissue of a dark reddish-grey colour, and this was continued into the sinuses, opening externally. The joint contained synovia, but there were several localised purulent collections within the synovial capsule, shut off by adhesions from the cavity.

The articular ends (with the exception of one or two small spots where it had been absorbed) were covered with adherent but softened cartilage, which in places was covered by adherent synovial membrane. The posterior surface of the olecranon was carious, and there were numerous small stalactitic masses of bone deposited. The same condition was presented along the internal condyloid ridge. On section of the removed articular ends no caseous deposits or inflamed spots were discoverable.

The patient did not come of a tubercular family, and there were no discoverable signs of the deposit of tubercle in his lungs.

The accompanying drawings were made from sections of the

Digitized by Google

granular synovial membrane removed from the joint. The specimens were somewhat injured by the shrinking resulting from the use of a too strong chromic acid solution.

No. 1.—Typical isolated synovial tubercle.

No. 2.—Aggregation of several such growths less distinctly marginated, and with the giant cells more irregularly situated.

Six months after the operation sinuses still existed, and there was such free mobility as to render the arm useless. At this time the chest was still free from abnormal signs. *June 29th*, 1881.

---

14. *Congenital malformations of hand and feet.* (*Card specimen.*)

Exhibited by SIDNEY COUPLAND, M.D., for MORTIMER BALDING, M.D.

THESE photographs and sketches were made from plaster-of-Paris casts taken by me whilst attending this patient for Mr. Cornwall, of Fairford.

Annie W—, aged 2½.

Right hand.—Normal. *Left hand.*—Fourth finger quite rudi-

WOODCUT 8.

Left hand (from a photograph of a cast).

Digitized by Google

mentary ; third finger measures a quarter of an inch in diameter at the seat of the constriction, and two thirds of an inch in diameter beyond the constriction.

Right foot.—Second and third toes rudimentary, similar to the fourth finger of the left hand. *Left foot.*—Circumference of calf at A eight inches ; circumference of constriction (B), which is situated

WOODCUT 4.

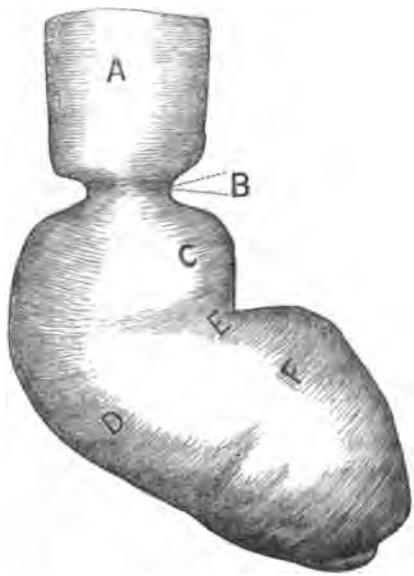

Left foot (for references see text).

two inches above ankle-joint, three and three quarter inches. Circumference at C below constriction and above ankle-joint ten inches. Circumference from heel to instep (D E) ten inches. Circumference of front of foot at F eleven inches. Cutaneous structures at the seat of constriction (B) have a cicatrix-like appearance, and are somewhat adherent to the tibia beneath. Above and below the constriction on the outer side a hard mass having a well defined edge can be felt, apparently the upper and lower edges of the divided fibula. At the back of the constriction, during flexion and extension of the foot, of which the child has considerable power, the tendo-Achillis can be distinctly felt to move under the finger, but no pulsation can anywhere be detected at the seat of the constriction. The only change that has taken place since birth is a relative increase in the size of the left foot. About fourteen months ago, owing it is believed to exposure to cold, a slough about two inches in diameter formed on the dorsum of the left foot which, under care and careful supervision, slowly healed. At the present

Digitized by Google

time the child walks as well as most children of her age, and no inconvenience is caused by the deformity (which does not depend upon œdema) beyond that due to the bulk of the foot.

April 19*th* 1881.

15. *Disease of right shoulder and right hip-joints in an infant.* (*Card specimen.*)

Exhibited by JOHN ABERCROMBIE, M.D.

THESE joints were removed from the body of a male child 13 months old at time of death.

The capsule of the shoulder-joint seemed a little thickened. On opening the joint a small quantity of thin serum was found in its cavity; the synovial membrane presented several small, red granulations. A considerable portion of the head of the humerus has disappeared, leaving an irregular margin lined by cartilage; the head of the bone thus exposed is not rough.

The hip-joint likewise contained a little thin serum; the synovial membrane was reddened as in the shoulder-joint, but the vascular granulations were not so large. About half of the head of the femur has disappeared. The ligamentum teres is intact.

The child came under treatment for an empyema, which probably dated from an attack of measles three months previously.

A month before she brought him, his mother had noticed that his right hip was swollen and painful, and she thought that his right shoulder was growing out.

He came under observation three weeks before his death, it was then noted that very distinct grating could be felt in right shoulder and hip-joints on manipulation. There was flattening of right buttock and shortening of right thigh, but no swelling or tenderness about the joints; he moved all his joints with perfect and equal freedom, and manipulation produced no signs of pain.

May 3*rd*, 1881.

16. *Sequestrum of clavicle.* (*Card specimen.*)

Exhibited by JONATHAN HUTCHINSON for MACNAUGHTON JONES, M.D. (of Cork).

THE patient, a girl aged 17, had received an injury to her clavicle some months before she came under Dr. Jones's care. Almost the entire clavicle was removed. The specimen shown being, at the time of the operation, quite loose. A good new bone was formed.

The case is of interest chiefly on account of the large size of the sequestrum.

Three months after the operation "there appeared to be a perfect new clavicle formed." *April* 5*th*, 1881.

Digitized by Google

17. *Old outward dislocation of the patella.* (*Card specimen.*)

Exhibited by CHARTERS J. SYMONDS.

THIS specimen was removed from a woman, aged 32, who died in Guy's Hospital, under the care of Mr. Golding-Bird, from tetanus following upon a burn. Eight years before she had been injured by an omnibus.

The patella rests upon the outer surface of the external condyle of the femur. The inner half—now anterior half—of its articular surface is alone in contact with the femur, and retains the normal appearance of the cartilage, except that it presents a slight grooving from friction against the edge of the condyle. From the outer half the cartilage has almost entirely disappeared, being replaced by a glistening fibrous material. The opposed surface of the external condyle is covered with a thick, rough, in parts shaggy, fibro-cartilaginous tissue, developed from the synovial membrane, which has been stretched upwards three quarters of an inch upon the femur. At the articular margin of this surface is a long fringe of fibrous material, which appears to have been carried backward and forward in the movements of the joint. The ligamentum patellæ is directed inward and downward, and the tibia is somewhat rotated outwards.

The cartilage covering the upper part of the femoral articular surface (patella site) is deeply wasted, the yellowish colour of the bone being visible in places through it. The surface here also is roughened, while the rest of the cartilage, and the other joint structures, present no departure from the normal condition.

April 5th, 1881.

18. *Parts of joints showing the changes characteristic of gout and rheumatic arthritis from the same patient.* (*Card specimen.*)

Exhibited by JONATHAN HUTCHINSON.

THESE specimens were obtained and given to me by Mr. McCarthy from the *post-mortem* room of the London Hospital. In the great toe-joint there is abundant deposit of white lithate of soda, whilst both in the knee and great toe are also seen in perfection the usual changes of senile arthritis.

The patient was a woman, aged 62, who was admitted insensible in consequence of apoplectic hæmorrhage into the right ventricle. She was said to have been of sober habits and to have enjoyed good health. No details were obtained as to gout. Her kidneys were contracted and granular, and the arteries atheromatous.

Digitized by Google

VII. MORBID GROWTHS.

1. *Dissection of a congenital hydrocele of the neck.*

By Frederick Treves.

[Plate XXIV.]

The subject of this tumour was a male child born at the full term. The labour was uncomplicated. The child lived three weeks, and during this time the tumour grew merely in the same proportion as the rest of the body. The child was perfectly developed in every other respect; its height at the time of its death was 19½ inches; it was much emaciated; the umbilical cicatrix had quite healed. The tumour measured 8 inches in its transverse diameter and 6 inches from the chin to its lowest point. When the body was placed upon the back the tumour reached to the lower border of the ribs, and at the sides concealed the shoulders and arms. As regards its surface connections, it was limited above by the ears (which appeared to rest upon the growth) and by the inferior border of the lower jaw; below it came off at the line of the upper border of the sternum and clavicle, and behind it was limited by the posterior border of the sterno-mastoid. It was remarkably symmetrical. The mass projected into the floor of the mouth and had almost filled it, the tongue being pressed up against the palate.

Dissection.—The skin was readily dissected off the whole of the tumour, which was, indeed, freely movable beneath it. The connection between the skin and the growth was everywhere maintained by a loose and scanty filamentous tissue, except at the upper part of the tumour, about the line of the lower jaw, where the adhesion between the integuments and the growth was very intimate. Many vessels ran from behind forwards over the surface of the mass, conspicuous among them being a large artery, which, issuing from beneath the sterno-mastoid on either side, crossed the tumour

Digitized by Google

Digitized by Google

F. Burgess lith

West Newman & Co imp

Digitized by Google

DESCRIPTION OF PLATE XXIV.

This Plate represents Mr. Treves's Case of Congenital Hydrocele of the Neck.

From a Photograph.

Digitized by Google

Digitized by Google

transversely about its middle. A single vein (anterior jugular), commencing about the chin, ran vertically down the middle line of the cyst and disappeared behind the sternum. On the surface of the tumour were also seen the superficial cervical, and great auricular nerves, while over its lower part some traces of the platysma were found. The mass was evidently cystic, and on incising it in the middle line a large quantity of clear yellow serous fluid escaped. It was then found that the main bulk of the tumour was composed of one large cyst that extended equally on either side of the middle line. On the deeper aspect of the wall of this cyst were some eight or ten smaller cysts, that had no connection with the cervical cyst, and that, when opened, discharged the same clear serous fluid. These smaller cysts projected forwards, *i. e.* into the great cavity; for when the deeper or attached wall of the great cyst was exposed by dissection, it was found to present no projections that would correspond to the smaller cysts on its inner wall. The anterior surface of the cyst wall was smooth, but the posterior wall was most irregular, presenting, in addition to the cysts just mentioned, many depressions and recesses of various sizes, and many irregular bars and bands. In three situations, viz. below the hyoid bone, in the floor of the mouth, and in the line of the second branchial cleft, certain secondary cysts were discovered, of which a separate description is given below.

The great cyst.—Its connections and relations were the same on the two sides. *Behind* the cyst wall was limited sharply by the posterior border of the sterno-mastoid as far down as the middle of the muscle, but below that point the limiting border crossed the muscle obliquely, and was represented by a line drawn from the middle of the posterior border of the muscle to the sternum. *Below* the cyst was limited by the last-mentioned line and by the upper border of the sternum. Its anterior wall was continuous with a fascia attached to the anterior border of the sternum and clavicle, and its posterior wall with a like fascia attached to the posterior borders of those bones. The cyst had therefore no connections with the cavity of the thorax. The posterior and inferior boundaries of the mass can be best understood by the fact that the sternal branch of the descending cervical nerves ran precisely along its inferior limits, while the small occipital nerve marked out its upper posterior border. The clavicular and acromial branches of the descending cervical nerves had no connection with the cyst wall.

Digitized by Google

The sterno-mastoid muscle was therefore quite outside the cyst cavity, although the anterior and posterior walls of the cyst were continuous with fasciæ that passed respectively in front of and behind the muscle. *Above* the anterior cyst wall was in front loosely adherent to, and limited by, a little of the lower border of the jaw, but behind it passed over the masseter muscle and was attached to the whole of the zygomatic arch, while beyond it extended up to the under surface of the external auditory meatus, and ended abruptly at the posterior border of the sterno-mastoid muscle. The posterior or deeper wall of the cyst extended up under cover of the lower jaw, and was abruptly limited by the alveolar border; behind the alveolus it ended in a *cul-de-sac* that extended as high up as the sigmoid notch, and beyond that embraced the external auditory meatus. This meatus, as well as the ear on either side, were perfectly normal.

On dissecting off the cyst from its deep attachments, the sterno-hyoid, sterno-thyroid, and anterior belly of the omo-hyoid muscles were exposed, together with the carotid vessels. These muscles were remarkably pale and wasted, and were somewhat adherent to the cyst wall. The anterior belly of the omo-hyoid contrasted in a striking manner with the posterior belly, which was of normal aspect. The carotid vessels were free from all adhesion to the cyst. The descendens noni nerve could not be found on either side. In the middle line the main cyst wall was very adherent to the hyoid bone, and above that point it covered in the mylo-hyoid muscle and anterior belly of the digastric. These muscles when exposed were found to be pale and wasted, and somewhat adherent to the cyst. The cervical and submaxillary branches of the facial nerve, together with the termination of the facial vein, ran beneath the cyst, and were only exposed when the mass was dissected off. The submaxillary gland was also covered by the cyst, and to its wall the fascia of the gland was very adherent.

The three secondary cysts.—1. A small round cyst, about the size of a Spanish nut, was found to dip down in the middle line between the two sterno-hyoid muscles, and to extend from the hyoid bone nearly to the cricoid cartilage. It communicated with the great cyst by a large opening.

2. A second cyst was found beneath the mylo-hyoid muscle and projected into the floor of the mouth. It was thin walled, multilocular, contained a clear yellow serum, and had no connection with

Digitized by Google

the great cyst, which completely covered it in. The cysts on the two sides were quite symmetrical. Each cyst was limited precisely by the middle line, where it passed beneath (*i.e.* on the deep surface of) the genio-hyoid muscle. Behind it was limited by the posterior border of the mylo-hyoid muscle and above by the mylo-hyoid ridge. It caused a considerable projection in the mouth, and beneath it ran the gustatory nerve.

3. After the large cyst had been dissected off a little cyst was found beneath it in the line of the second branchial cleft. This cyst contained some thick bloody fluid, was long and narrow, and extended obliquely from that part of the hyoid bone touched by the digastric tendon to the base of the skull just to the inner side of the joint of the lower jaw. It was club shaped, being large at the hyoid bone and tapering off towards the ear, and was sharply limited by the middle line. The walls of this cyst were thin, and on its superficial surface rested the facial vein, while beneath it passed the ninth nerve and the posterior belly of the digastric muscle. Its inner surface presented many bands and bars, that were, however, obliterated by extension. The cyst wall was everywhere adherent to the deeper parts, and also to the hyoid bone. The cavity of this little cyst communicated with that of the main cyst by an aperture at its inferior part. The cysts of the two sides were precisely similar to one another in size, shape, and relations.

I forbear making any observations upon this specimen beyond drawing attention to the relations of the main mass to the cervical fasciæ, and the existence of the small cyst in the line of the second branchial cleft. *March 3rd*, 1881.

---

2. *Congenital sacral tumour.*

By Samuel G. Shattock.

[With Plates XXV and XXVI.]

The tumour forms a faintly lobulated ovoidal mass, 6 inches by 4½ in its chief diameters, distinctly circumscribed, isolable, and loosely invested with the skin, which is everywhere grown so as to maintain its natural thickness.

Digitized by Google

The tumour projects upwards for a short way into the pelvis, between the terminal portion of the rectum and the coccyx; but neither of these parts is implicated in the growth. The main mass of the tumour projects downwards, with a slight direction backwards, between the lower limbs, which it equals in length: the rectum terminates in front of its base, being displaced slightly forwards, whilst the coccyx is over-extended.

The section of the tumour shows it to be composed throughout of lobe-like parts (recently pinkish yellow), formed of numerous close-packed, smooth-walled cysts, varying in size from a nut-shell to the smallest spaces visible to the naked eye, and of various mutually adapted forms.

A few of the cysts contain small intra-cystic growths, these growths being themselves minutely cystic. All the cysts contained a ropy mucus.

In a few spots cartilaginous and osseous trabeculæ have been produced in the larger partitions of the tumour.

The skin is extensively undermined (chiefly on the anterior aspect), from an ulcerated aperture near the summit of the growth.

Morbid histology.—The tumour is composed of regular and involuted cysts and duct-like passages, lined for the most part with cubical epithelium, and held together by young, richly-celled connective tissue. In many situations the epithelium is columnar, set upon flatter cubical cells.

In a few spots flattened trabeculæ, or branching plates of hyaline cartilage, occur in the intercystic partitions, and in a few spots these have undergone ossification.

From a child 5 weeks old, under the care of Mr. Beck.

There was no obstruction to defæcation or micturition.

This specimen (of which half is in the Museum of the Royal College of Surgeons) is nearly identical in position, form, and structure with that described by Mr. Hutchinson,[1] and in most points corresponds with the "mixed tumours" of Cornil and Ranvier, presenting, amongst its constituents, cartilage, bone, and cysts, and canals lined with pavement or cylinder epithelium.

Another specimen, of a similar kind, is probably one in St. Bartholomew's, which has arisen in connection with the tissues lying over the sacrum; to the naked eye its structure is precisely similar to the one here described. *March 3rd*, 1881.

1 'Illustrations of Clinical Surgery,' fasciculus xiii.

Digitized by Google

Digitized by Google

DESCRIPTION OF PLATE XXV.

Illustrating Mr. Shattock's description of a Congenital Sacral Tumour. From a drawing by himself.

The drawing represents a vertical section of the pelvis and tumour. A piece of glass rod has been passed through the anus to mark its position.

Digitized by Google

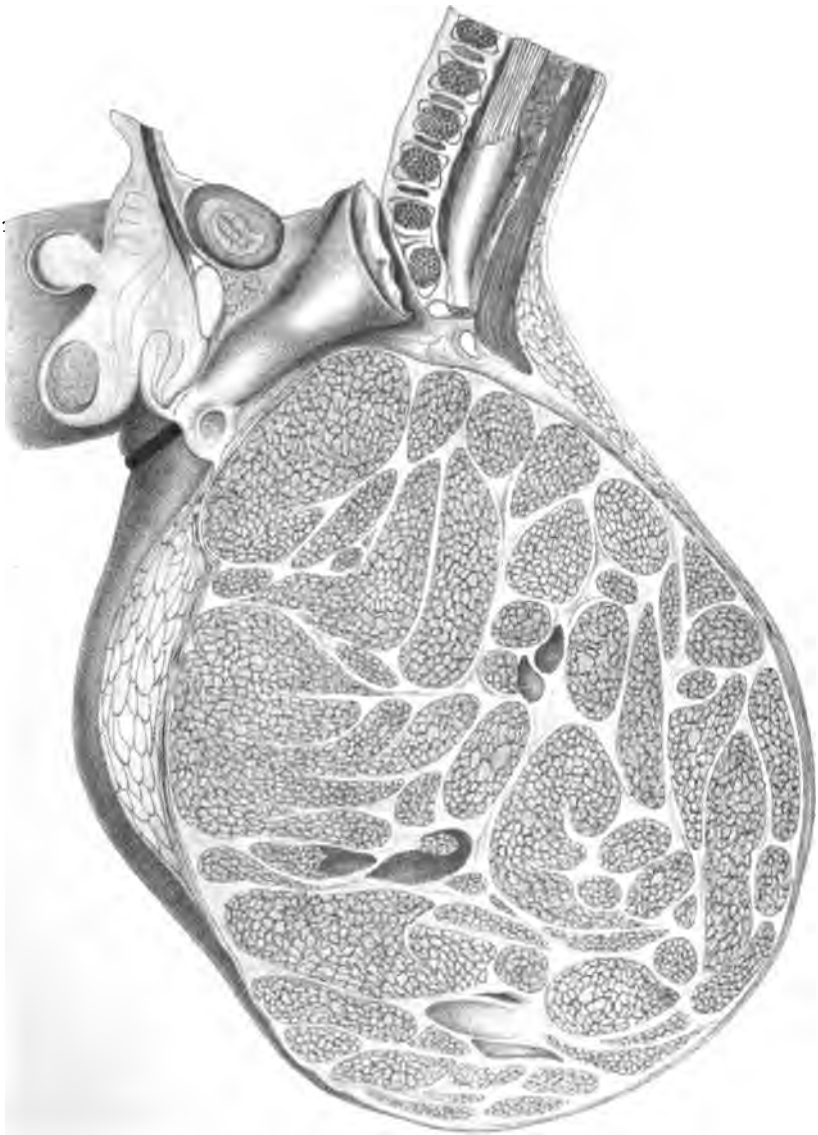

Digitized by Google

S G Shattock del

F Huth Lith.

Digitized by Google

Digitized by Google

DESCRIPTION OF PLATE XXVI.

Illustrating Mr. Shattock's description of a Congenital Sacral Tumour. From drawings by himself.

FIG. 1.—A section of the tumour as seen under Hartnack, oc. 2, ob. 4.

a. A trabecula of cartilage in one of the fibrous partitions of the tumour. The section displays mutually adapted cysts holding mucus and lined with epithelium.

FIG. 2.—Portion of the same tumour under Hartnack, oc. 4, ob. 8, showing the margin of a large cyst, and sections of duct-like passages lined with cubical and subcolumnar epithelium, held together by richly-celled connective tissue.

Digitized by Google

Fig. 1.

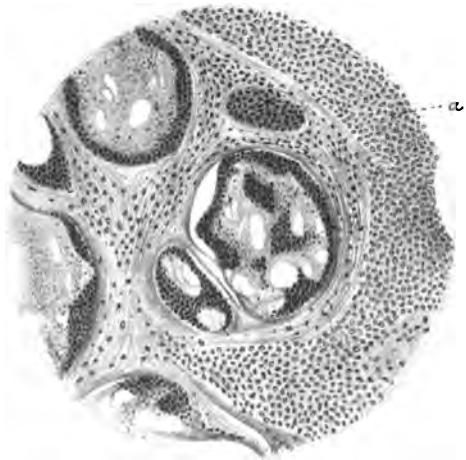

Fig. 2.

S. T. Shattock del

Digitized by Google

F. Huth, Lith^r Edin^r

Digitized by Google

3. *Congenital tumour containing fœtal structures, removed from the sacrum of a child.*

Exhibited by C. MACNAMARA.

THIS is an example of one of those comparatively rare but interesting specimens of a parasitic growth, or tumour containing fœtal structures growing from the body of an otherwise healthy and well-formed female child. Cases of this kind are interesting to the surgeon, because it is sometimes a nice point to determine how far the contents of the tumour are connected with some of the important viscera of the child to which it is attached, and also if it is safe to remove it. To pathologists these tumours are interesting, because they serve as a connecting link between those cases in which twins have been born united to one another, and the ordinary form of congenital dermoid cysts. There can be little doubt as to the specimens before us having been an ovum which had been impregnated but had not arrived at maturity, the blighted ovum at an early stage of its development became attached to the fœtus, of which it subsequently formed a part, increasing in size with the fœtus, and after birth growing in proportion to the infant.

The child from whose back this tumour was removed was three months old when she was sent into the Westminster Hospital by Mr. W. Ross, of Alderney. The patient was a healthy, well-formed infant, with the exception of this tumour, which was observed at the time of birth growing from the left side of the median line of the sacrum. At its attachment to the body of the child it measured 10 inches in circumference, and 12 inches round its largest part; it measured 14 inches from before backwards.

On examining the child's sacrum, per rectum, it seemed normal. Firm pressure over the tumour did not diminish its volume or appear to cause the child any inconvenience. At the same time it was evident that the tumour contained cartilage if not bone at its attachment. Projecting from either side of the morbid growth there were two processes, each of them being about 2 inches long; they resembled fingers. There was also a peculiar fold of skin surrounding the tumour.

Digitized by Google

On the 22nd of January, having applied an Esmarch bandage round the mass, I transfixed its base with a needle and wound an elastic ligature over this so as to stop the circulation of blood into the growth. Flaps of skin were reflected from the tumour, and it was then separated from the body of the child by means of the écraseur. The little patient made a rapid recovery from the operation, and left the hospital with the wound in her back almost healed on the 9th of February.

My friend Mr. Pearce Gould has examined the morbid growth, and reports that the tumour is ovoid in shape with a general even surface. Running half way round close to the base of attachment is a fringe-like band of skin, ½ to ⅓ inch broad, with a narrow, uneven edge, and terminating in a knob of skin at either end. Almost in a line with this, and on the left side of the mass, is a curved, conical projection, something of the size and shape of the little finger semiflexed.

On section the tumour is seen to be partly solid, partly cystic. There is a large cyst the size of an orange at the upper part of the mass, with a slightly sacculated wall lined by a smooth membrane. Another sacculated cyst, the size of a walnut, is seen close to the pedicle, and other smaller ones were divided at the time of the operation, or have been found in the dissection of the tumour.

The solid portion of the tumour, which forms the greater part of it, is almost entirely composed of firm, pale yellow, granular fœtal fat. Embedded in this fat is an irregular piece of cartilage which has to a great extent undergone ossification, which has started from several centres. The cartilage is branched in a peculiar manner, bijointed, and has no resemblance to any of the normal bones. Its longest offset is about 3 inches long and consists of a tapering chain of cartilages extending to the end of the finger-like process. Chiefly, in more or less close relation to this irregular cartilage, bands of reddish tissue are found, which, from microscopical examination, are seen to consist of cellular tissue and unstriped muscle. *March 1st*, 1881.

Digitized by Google

Digitized by Google

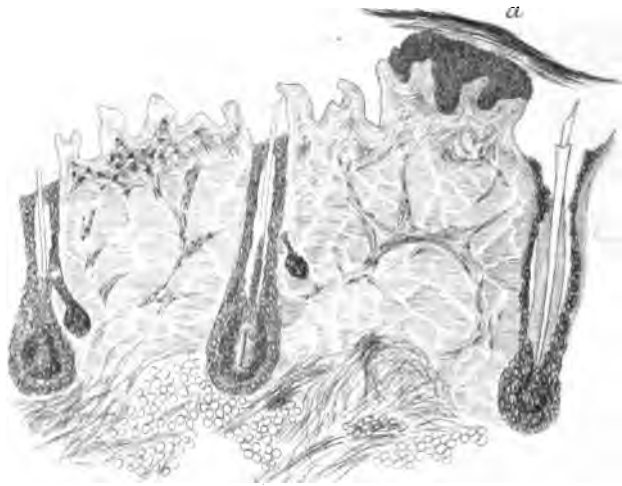

1

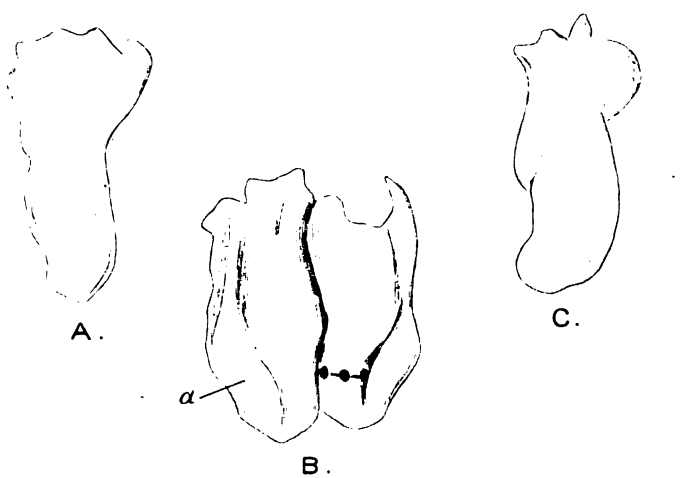

E. Nos & F. Langlois Sc.

Mintern Bros. imp.

Digitized by Google

DESCRIPTION OF PLATE XXVII.

Illustrating Dr. Hale White's Case of Dermoid Tumour.

FIG. 1 represents a vertical section of that part of the tumour just superficial to the cartilage; it shows its structure to resemble exactly that of ordinary skin with hairs and sebaceous glands. Throughout the greater part of the section the epidermis is knocked off the papillæ, but it is adherent at *a*. (Hartnack, ob. 3, oc. 3.)

FIG. 2.—A and C are back and front views of the tumour, natural size, the lower extremity is that which hung down the pharynx. B shows the growth in section *a*, being the plate of cartilage just under the surface.

Digitized by Google

Digitized by Google

4. *Dermoid tumour, probably growing from soft palate or base of skull.*

By W. Hale White, M.D.

[With Plate XXVII.]

A. B—, aged 3 years, brought by a friend on August 30th, 1880, to the medical out-patient department at the Evelina Hospital. The child was said to have some difficulty in swallowing, especially solids, and to make a good deal of noise in breathing, more particularly when asleep. It was also said "to have something in its throat."

The child was well nourished, and apparently healthy. No other complaint was made.

On depressing the tongue with a spatula, and looking into the mouth, a body was seen, which at first sight appeared to be an immensely hypertrophied uvula, the end of which passed too far down the throat to be at once visible, though the whole was plainly seen when efforts at swallowing were made. Closer inspection showed that the uvula was in front, and more in the middle line than this body, and that it was normal in every way. The tumour was about two inches long, and about the size of one's first finger, and was probably attached to the soft palate behind the uvula. It was of a brighter red than the surrounding mucous membrane, and moved freely with the palate. It apparently had a broad base, and was somewhat smaller towards the free end, which projected into the throat. All the parts around were perfectly normal in appearance. It was freely movable, and could be hooked forward into the mouth or moved from side to side.

Three days after the first examination the grandmother brought the child. Chloroform was given, the mouth held open, and Mr. Morrant Baker firmly tied some silk round the base of the tumour, and cut it away. The next day the case was doing well, and also about five days afterwards; since that nothing has been heard or seen of the child, who was throughout treated as an out-patient.

On examination of the piece removed it was found, after it had been in preservative fluid for some months, to measure 1⅛ inch in length, ½ inch in breadth at the base, with a slightly tapering and

Digitized by Google

rounded apex. Generally it was of soft consistence, like that of fat, but contained, just under one surface, a plate of cartilage, running vertically through the whole tumour, about $\frac{1}{16}$ inch thick, and $\frac{1}{2}$ an inch wide at least. Unfortunately the exact width was not measured before the growth was partly cut up for microscopical examination.

Microscopical examination of a section, cut horizontally through the growth on that surface, which is just over the cartilage, shows that it is in structure almost identical with ordinary skin.

Thus externally there is epidermis composed of cells, indistinguishable from those of the cuticle, as found in its usual positions, the cells being most stratified near the surface, whilst those adjacent to the papillæ are vertical. The ridge of one cell adjoins the ridge of the one beneath. Each has a large nucleus, and processes of epidermis dip down between the papillæ. Underneath this layer we find the structure of the growth to resemble the corium of true skin, being composed of connective-tissue fibres, which, immediately under the epithelium, are so closely packed as to form an almost homogeneous layer, whilst lower down they spread out. Fat cells appear between the bundles, and thus the skin-like structure gradually blends with the fat, of which the tumour is mainly composed. No yellow elastic or plain muscle fibres are visible. There are numerous papillæ, none of which are compound; each contains a vessel, but in none have I been able to see any nerves; but no special stain was used.

Many hairs are present, but they are so fine that they were not seen till sections were cut. Each hair is covered with imbricated scales, within which comes a fibrous, translucent substance, and then, in all cases, a medulla of good width, in proportion to the smallness of the hair. Where the hairs end on the free surface this medulla is always prolonged further than the translucent substance, which diminishes in quantity from below upwards. The medulla, as seen by transmitted light, is dark below, and gets lighter towards its free termination. The root of each hair is slightly bulbous, and is planted at the base of the follicle in which each hair is placed. The epidermic coat of the follicle or root-sheath of the hair is closely adherent to the bulb, and distinctly formed by a dipping into the follicle of the epithelial covering of the tumour. In none of the hairs was any papilla to be detected. Most of the hair follicles have opening into them the ducts of

Digitized by Google

sebaceous glands in about the middle, but there is only one gland to each follicle. These glands do not seem in any respect to differ from those of ordinary skin, and bear about the same proportion in size to the follicle as is usually the case. The follicles just reach the uppermost fat-cells.

Sweat-glands are scanty, for in all the sections examined I have only been able to detect three, and those very small. One of these was peculiar from the fact that, instead of being situated in the fat, as usual, it was placed in the lower part of the corium.

The general fatty portion of the tumour does not call for any special mention, consisting simply of a meshwork of fibrous tissue with fat in the interstices.

The plate of cartilage is surrounded by a layer of condensed fibrous tissue, and has large vessels running alongside it. In structure it is very peculiar, consisting of cells much smaller than is usual, and so numerous that it is difficult to make out any intercellular substance. The cells are much more abundant at the margins of the cartilage than in the centre, being, in the former position, packed so closely that it is almost impossible to make a definite outline to each cell, and the whole appearance reminds one of the stratified arrangement of the cells of the epidermis. The fact that the cells are more numerous and smaller at the margin shows that the cartilage is growing peripherally. In some cases two cells are so arranged that it is obvious they have resulted from the division of one. Each cell has a distinct nucleus.

The intercellular substance is very scanty, but appears to be composed of fine fibres; but in no case have the cells dropped out, as they generally do, from the interstices in elastic cartilage.

As far as I have been able to make out, examples of a similar tumour in this situation are rare, one having been recounted by Mr. Abraham, both in the 'Journal of Anatomy and Physiology,' vol. xv, and the 'Brit. Med. Journal' for December 18th, 1880, as occurring in a young woman, growing from the basilar process of the occipital bone. This tumour very nearly resembled the present one in microscopical structure. Another is recorded by Dr. G. H. Kidd, in the 'Dublin Hospital Gazette' for 1856, p. 82, in which a huge tumour, 8 inches long, 6 broad, grew from the palate of a newborn child. This was covered with skin, and contained rudiments of intestine, bone, and cartilage.

Although I have looked carefully, these are the only instances

Digitized by Google

I can find of tumours of this description growing on or near the palate.

Judging from the cartilage, which resembles that of the Eustachian tube, it seems probable that this growth may have had some connection with that organ. Embryologically, there is no difficulty in accounting for the position of the tumour, for the involution of epiblast, which takes place at the mouth, reaches back to the posterior wall of the pharynx; and, in fact, in rabbits, there are four tufts of hair at the posterior part of the epiblastic involution—two on the inside of each cheek—one being at the junction of the inside of each cheek at the base of the skull, the other at the junction of the inside of the cheek with the floor of the mouth. This tumour is probably the homologue of one or more of these tufts of hair. Thus, I think we have here an example of atavism, this child showing a tendency to resemble her rodent ancestors.

April 5th, 1881.

---

5. *Congenital mucous polypus of umbilicus.*

By A. Pearce Gould.

W. J. J—, a male infant, aged 5 months, was brought to the Westminster Hospital, on October 25th, 1879, with a bright red, soft, pedunculated growth the size of a large currant, springing by a narrow pedicle from the cicatrix of the umbilicus. At its upper part was a small hole admitting a probe for one eighth of an inch. The tumour was moistened by thin mucus, and there was no discharge of urine or fæces from it. It was first noticed when the cord fell off and was then nearly its present size. A ligature was applied round the pedicle, and the polypus cut off and prepared for microscopical examination by Dr. H. Gibbes.

Thin sections show the growth to be composed of branched mucous glands, lined by a single layer of columnar epithelial cells, and opening on the surface; a similar epithelium covers the surface. Between the acini of the glands is a fine fibrous and richly nucleated stroma containing blood-vessels. No fat-cells are seen.

Digitized by Google

These tumours are mentioned by nearly all modern writers on the surgical diseases of children, and have been spoken of as "wart-like" by Mr. Holmes, and as consisting of "exuberant granulations" by Mr. Bryant. Mr. Cooper Forster describes one which he examined as consisting of fat-cells and without any vessels.

The structure of the growth is inconsistent with the theory that it is produced by some abnormality in the process of separation of the funis, and the history of this case renders additional weight to the view that these polypi are truly congenital. Their small size accounts for their not being noticed before the cord falls off. The structure of the polypus is so closely like that of the soft mucous polypus of the rectum, also met with in children, that it is probably a safe conjecture that it originally developed from a similar embryonic tissue, the remains of the umbilical vesicle.

November 2nd, 1880.

---

6. *Extra-renal growth.*

By JOHN ABERCROMBIE, M.D.

[With Plate XXVIII.]

THE drawing which I have brought here this evening represents the kidneys taken from the body of Charles D—, aged 18 months, who was admitted into the Hospital for Sick Children, September 15th, 1880, under the care of Dr. Gee.

Owing to the death of his mother a few days before he came under observation, but little history could be obtained; we learnt that he had been gradually getting weak and losing flesh for about eight months, and that his stomach had got bigger during that period.

State on admission.—Very pale and wasted. Anterior fontanelle widely open. Some purpuric spots on trunk and extremities; sharp, moist râles over right back, no dulness. Ribs markedly beaded. Abdomen tumid; liver somewhat enlarged; spleen much enlarged and hard. Blood shows no increase of white corpuscles. For a little while he seemed to improve, but then fever set in accompanied by swelling of hands and feet and followed by a general anasarca. No urine could be obtained.

Digitized by Google

He died on October 20th, 1880.

Autopsy eight hours after death. — Body anasarcous, weight 13½ lbs. Rigor mortis slight.

Thorax.—No pleural adhesions.

Both lungs show small purpuric spots on surface, otherwise natural; each weighs 2½ oz.

Slight excess of fluid in pericardium; some purpuric spots on surface of heart which is otherwise natural. Heart weighs 1¼ oz.

Tracheal and bronchial glands not enlarged.

Abdomen.—A little effusion into peritoneum. Alimentary canal natural.

Liver enlarged, slightly pale.

Spleen very large, firm, no capsular thickening, on section no abnormal appearance to the naked eye; weight 6½ oz.

Kidneys large, firm, very pale; demarcation between cortex and medulla indistinct; no iodine staining. Pelvis of each kidney filled up with soft, deep purple growth beneath the lining membrane, appearing externally as a small button-like mass, no connection between the two kidneys.

Radiating from medulla to cortex are numerous, variously sized, wedge-shaped purplish blocks, paler in the centre, appearing on the surface as raised, more or less round purple patches, yellowish in centre; weight 5 oz.

Præ-vertebral gland in neighbourhood of kidneys enlarged and soft.

Suprarenal bodies natural.

Some mesenteric glands slightly enlarged.

Microscopical examination of a section of the growth (after hardening in chronic acid and spirit) shows that it consists of small nucleated cells, mostly round, embedded in a loose meshwork of areolar tissue; towards the centre of the growth the cells are closely aggregated, at the circumference they are much more scattered, and the space between them is for the most part filled up by extravasated blood.

The cortical portion of the kidney shows well-marked parenchymatous nephritis.

The spleen shows nothing more than a hypertrophy of its normal constituents.

At the last meeting of the Society last session I brought forward three cases of extra-renal growth, invading both kidneys indepen-

Digitized by Google

Digitized by Google

DESCRIPTION OF PLATE XXVIII.

Illustrating Dr. Abercrombie's Case of Extra-Renal Growth.

The upper figure represents a section of the kidney, showing an infiltrating growth in its substance.

The lower shows, from outside, the new growth surrounding the pelvis of the kidney.

Digitized by Google

Fig. 1.

Fig 2.

Digitized by Google

Digitized by Google

dently, occurring in young children; the present case appears to resemble those exactly both in its naked-eye characters and in its microscopical changes. *May 3rd*, 1881.

---

7. *Fibro-cellular tumour removed from the interior of the knee-joint.*

By Rickman J. Godlee.

The patient from whom the specimen exhibited was removed, was a married woman, of somewhat sickly appearance, aged 38, who was admitted into University College Hospital, on July 1st, 1880. Her right knee had, she said, been swollen for eight years, the amount of swelling and pain being subject to considerable variation; but when much swollen the inconvenience in walking was very great. She could assign no cause for the commencement of the swelling; she did not seem to be the subject of any definite diathesis, though there was some reason to suspect rheumatism. There was, for example, a slight mitral murmur, and moreover, some irregularity of the catamenia.

The affected joint was much distended with fluid, and a hard body was distinctly to be felt above and external to the patella, movable to the extent of almost an inch diagonally or from side to side, but apparently more fixed if attempts were made to move it in the vertical direction. The pain complained of at the time was pretty considerable and of a dull aching character.

The joint was aspirated in the first instance by Mr. Heath, and when I took charge of his wards the case came under my care. As no relief was gained by the aspiration, I removed the tumour on July 7th, 1880, making an incision over it through the soft parts, and then through the capsule, and dividing the pedicle after fixing the tumour with a hook. It turned out to be a mass of an ovoidal shape, with a long diameter of one and a quarter inch and a short diameter of three quarters of an inch, fixed to the outer condyle of the femur by a broad thick pedicle. The surface of it was smooth and obviously covered by synovial membrane, the interior on section

Digitized by Google

white, firm, and glistening, and showing under the microscope a simple fibro-cellular structure.

A large amount of yellow serum escaped from the joint. A short drainage tube was inserted, (but not, as it turned out, into the joint) the wound was treated strictly antiseptically, and healed without any suppuration, or indeed inflammation the temperature never rising above 99·4°. Afterwards the joint refilled with fluid, and the temperature on one day reached 100°.

On one subsequent occasion, the 26th July, some fluid was drawn off from the joint. By August 9th the knee seemed perfectly healthy, but was stiff from recent adhesions; so an anæsthetic was administered, and these were broken down, with the result of causing a fresh effusion into the joint. This took a week or two to subside, at the end of which time the joint became comfortable and has remained so ever since. This fact I ascertained the day before reporting the case.

The case is brought forward as an example of a very uncommon, indeed, as far as I know, a unique form of loose body in a joint. One may hazard the guess that it arose from the inflammatory thickening of one of the synovial fringes. A tumour of this kind cannot, of course, be removed except by making a free incision into the capsule of the joint. *November 2nd*, 1880.

---

8. *Myeloid tumour of the head of the tibia.*

By Jeremiah McCarthy.

A young woman, aged 25, of strumous aspect, but well nourished, was admitted into the London Hospital for pain in the right knee. This pain had existed for about four months, and had latterly been so severe as to prevent her using the limb. She was, however, able to walk for a short distance with the aid of a stick.

On examination, it was found that the joint was apparently normal, but that there was an ill-defined superficial swelling near

Digitized by Google

the insertion of the Sartorius tendon at the inner side of the head of the tibia. The skin over it was red and œdematous. It was very painful on pressure, and there was most distinct fluctuation. Rest in bed for a few days produced considerable improvement. The redness and œdema disappeared, the tenderness considerably abated, and the swelling itself became smaller.

On careful examination, it was found to pulsate, and this pulsation was not accompanied by any bruit. By the insertion of a hollow needle connected with a syringe some blood was obtained in which microscopic examination disclosed some very characteristic myeloid cells. The patient consented to amputation, if an attempt to enucleate the growth should fail. On the operation table, however, the application of an Esmarch's bandage, fractured the tibia, so that amputation through the knee-joint was at once performed; and as the crucial ligaments and the intercondyloid notch of the femur were found to be involved, the lower end of the femur was also removed.

The upper fifth of the tibia had been almost entirely replaced by the myeloid growth. Only at the back was a thin layer of bone remaining, and even this was so soft as to admit of being easily cut with a knife. The articular cartilage of the tibia was normal, but in the median line the growth had spread up along the crucial ligaments to the back of the femur. The articular cartilage of this bone presented well marked lateral lips, and the cartilage of the patella was soft and pulpy.

The operation was done antiseptically. For several days there was a profuse discharge of dark-coloured fluid, and on the twelfth day the patient died, apparently from exhaustion. No disease was discovered in any other part of the body at the *post-mortem* examination. *May 20th*, 1880.

Digitized by Google

9. *Round-celled sarcoma with hyaline degeneration (cylindroma) of the popliteal space.*

By Henry T. Butlin.

[Plate XXIX.]

G. M—, a bootmaker, aged 19, was admitted into St. Bartholomew's Hospital, on the 18th of November, 1879, under the care of Mr. Willett. He was suffering from a tumour of the popliteal space about the size of a plover's egg. It grew apparently from the posterior ligament of the knee-joint, from which it was removed on December 4th. Recurrence was very rapid, and on the 25th of February, 1880, the thigh was amputated high above the disease. Further details of the case will be found in Mr. Cripps's account of three cases of multiple sarcoma in another part of this volume.[1] A separate account is made of the case thus far because of certain peculiarities which were present in the primary tumour, and which were not known either to Mr. Cripps or to the writer till after his communication had been made.

To the naked eye the first tumour of the popliteal space appeared like a quickly growing sarcoma, but was perhaps rather more gelatinous than usual. To the microscope it presented the characters of the disease which has been described by Billroth[2] as cylindroma, and has been made the subject of an able monograph by Sattler.[3] The sections were traversed by bands or cylinders of cells, varying in thickness, irregular in their disposition, and separated by a more or less abundant hyaline or finely fibrillated substance. The cells of which the cylinders were composed were tolerably equal in size, polygonal in shape, and so closely packed that no intercellular material could be distinguished. They were rather larger than granulation cells, and most of them were furnished with a single nucleus. In the hyaline substance were also scattered cells, round, oval, or elongated; and midway between the cylinders were vessels, the walls of which were sometimes hyaline, like the substance in the midst of which they lay. Tumours bear-

[1] The publication of these cases has been deferred at Mr. Cripps's request.—Ed.

[2] 'Pathologie,' 8te vermehrte Auflage, p. 734. Berlin, 1876.

[3] 'Ueber die Sogenannten Cylindrome und deren Stellung im onkologischen Systeme.' Berlin, 1874.

Digitized by Google

ing a structure similar to this have been described in the interior of the skull, in the orbit, and in the salivary glands; but I believe not in the trunk or limbs.

The origin of the hyaline substance and the nature of the disease have excited much discussion. This case does not throw any light on the former point, unless the disposition of the hyaline substance and the affection of the vessel-walls renders it probable that it is due to a transformation of the latter and of the fibrous structures of the tumour.[1] But the nature of the disease is very clearly shown; for the recurrent tumour, and those which were disseminated in different organs and tissues of the body, were typical examples of round-celled sarcomas, without a trace of hyaline degeneration.

It appears, then, that this is a case of round-celled sarcoma, and that the characters of the primary tumour were obscured by a transformation of certain of its constituents, probably the fibrous tissues. On this assumption all the peculiarities of its structure may be explained. The hyaline substance, occupying more space than the tissues it has replaced, has gained that space at the expense of the cells. These have been pressed more and more closely together until the intercellular substance has disappeared; the rounded outline of the cells has been lost, and they have become polygonal by mutual pressure. By the same cause the characteristic arrangement of the groups of cells has been produced.

The name cylindroma applied to the disease is singularly unfortunate, for it does not well express the structure of the tumour, and it is frequently misapplied to cylindrical-celled epithelioma. Nor is the term sarcoma carcinomatosum (Sattler) more happy, for this disease is in no respect carcinomatous. It is in the first place of the utmost importance that it should be recognised as a round-celled sarcoma, and if it be thought necessary to express the peculiarities of its structure in its name, this may be done by calling it a round-celled sarcoma with hyaline degeneration, or a plexiform sarcoma (Billroth). *April 19th*, 1881.

[1] Maier, 'Archiv der Heilkunde,' Bd. vii, s. 145. 1866.

Digitized by Google

10. *Squamous epithelioma of the upper jaw.*

By Henry J. Butlin.

[Plate XXIX.]

In November, 1880, a man, named Joseph S—, aged 62, was admitted into St. Bartholomew's Hospital on account of two small carbuncles of the back. About the middle of December he complained of great pain in the right cheek and in the alveolar process of the upper jaw, and, on being questioned, stated that he had been suffering from pain in these parts for some months past, and that for a long time he thought it had been toothache. On examination, a small fistulous opening was discovered in the situation of the alveole of the second molar tooth, from which a foul discharge proceeded. With this exception nothing abnormal was discovered, but most of the teeth on this side of the upper jaw were gone. On the 29th of December an exploration was made with the design of removing some carious bone, but no such bone was discovered, and the orifice of the fistula, which had previously seemed so small, was found easily capable of admitting the finger of the operator (Mr. Willett) into the antrum, which was filled with pus, débris, and what appeared to be firm granulation tissue. The free opening of the fistula did not relieve the patient's pain, and on the 1st of January a puffy swelling appeared of the tissues between the malar bone and nose immediately below the orbit. Towards the end of January some of the granulation tissue within the antrum was scraped away with a Volkmann's spoon and examined microscopically, with the result of finding ill-formed epithelial cells of various shapes and portions of cell-nests. This left no doubt of the nature of the disease, and on February the 8th the upper jaw was removed by Mr. Butlin in the hope of affording relief to the sufferings of the patient, who was in a very feeble state. Five days later he died from exhaustion, and the autopsy discovered no affection of the lymphatic glands or of any part of the body other than the upper jaw. In spite of the absence of the ordinary signs of tumour of the antrum, the jaw was entirely destroyed with the exception of a part of the alveolar process. The disease extended

Digitized by Google

Digitized by Google

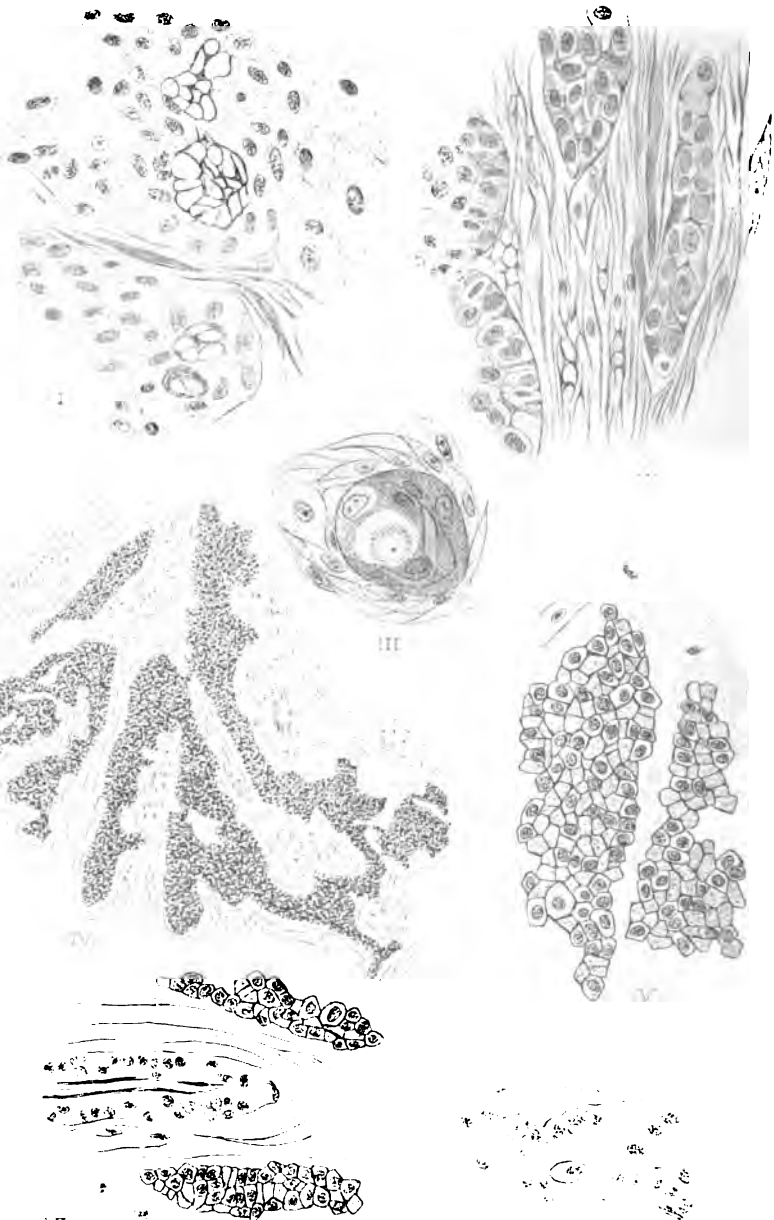

Digitized by Google

DESCRIPTION OF PLATE XXIX.

Illustrating Mr. Butlin's Cases of Epithelioma and Round-celled Sarcoma. From drawings by himself.

FIGS. 1 and 2.—Epithelioma of upper jaw, "epithélioma térébrant." (Hartnack, oc. 3, ob. 7, *t.d.o.* × about 260.)

FIG. 3.—A cell-nest from the same. (× about 260.)

FIG. 4.—Round-celled sarcoma with hyaline degeneration. Cylindroma of Billroth. (× 90.) The darkly shaded granular parts represent the masses or cylinders of cells; the lighter parts the hyaline material between them.

FIGS. 5, 6, 7.—Portions of the same tumour more highly magnified. (× about 260.) Figs. 5 and 6 show the characters of the cells composing the masses. In 6 is seen a vessel with hyaline degeneration of its walls. In 7, the characters of some of the cells in the hyaline material are exhibited. The hyaline material is more often finely fibrillar than absolutely hyaline.

Digitized by Google

Digitized by Google

through the lower wall of the orbit to the eye, into the sphenomaxillary fossa and up between the temporal and masseter muscles, and beneath the temporal aponeurosis. Sections made from different portions of the tumour showed everywhere the structure of squamous epithelioma, containing many cell-nests.

This is the only case of squamous epithelioma of the upper jaw in the Society's 'Transactions,' and is of special interest because it appears to be one of a class of cases characterised in every instance by similar clinical symptoms. The disease has been admirably described by Reclus in the 'Progrès Médical' for 1876,[1] under the title of "Epithélioma térébrant" (boring or burrowing epithelioma), on account of the manner in which it burrows its way from the alveolar process into the antrum, but without widening the bone or distending the antrum. Reclus suggests that it has its origin in one of the cysts which are so frequently attached to the roots of the teeth, and which are probably themselves derived from epithelial débris, vestiges of the budding of the temporal or permanent teeth. But this explanation appears strained, especially since the disease may be as easily derived from the deeper layers of the epidermis of the mucous membrane covering the socket of an extracted tooth. Spreading upwards instead of sprouting into the mouth, it destroys the bone and fills the antrum.

The only case I have found in English medical literature is one recorded by Mr. Lawson in the 'Transactions of the Clinical Society' (vol. vi. p. 20, 1873). In that case as in the present, and in those recorded by Reclus, the earliest symptom was violent toothache. In every case the progress of the disease was for a long time very insidious; and in more than one instance its nature was not discovered until it had entirely destroyed and extended far beyond the bone. In all the cases a fistulous passage existed in the alveolar process through which fetid pus escaped, and which gave access directly to the antrum. *April 5th*, 1881.

[1] T. iv, p. 795.

Digitized by Google

11. *Case of colloid cancer of peritoneum invading the spleen.*

By W. M. Ord, M.D.

The subject was a man, aged 35, who had suffered from various kinds of abdominal distress from the age of 17. These symptoms had become rather rapidly aggravated two years before his death. He had then pain all over the abdomen, increased after eating, and often accompanied by diarrhœa. A year later he noticed that the abdomen was swollen on the left side. The swelling speedily involved the whole abdomen, and vomiting was now of frequent occurrence. The swelling steadily increased, the vomiting became more severe, particularly after food; he began to have much pain in the back, and lost flesh rapidly.

When admitted he was much emaciated in the face, thorax, and upper limbs; the abdomen was greatly enlarged; the legs were œdematous. He suffered much from pain, from sensations of distension of the abdomen, from shortness of breath, and from weakness.

The abdomen measured 43½ inches in circumference at its greatest girth, and 19 inches from the ensiform cartilage to the pubes; the umbilicus was protruded by a flabby, indistinctly fluctuating tumour; a similar smaller tumour protruded in the median line an inch above the umbilical swelling. There were two flattened, bun-like thickenings to be felt in the abdominal walls, one on each side of the umbilicus. The superficial abdominal veins were enlarged and prominent.

The belly was tense, and fluctuated as freely as if it contained fluid; it was dull on percussion everywhere, and in every position of the body.

There was no disease of the thoracic viscera and no indication of renal disease.

An exploratory tapping brought away a small quantity of colloid matter. The tapping was subsequently repeated at various points of the abdomen with varying results, quantities ranging from half an ounce to three pints being removed.

In spite of the temporary relief afforded by the tapping, his condition steadily became worse. The girth of the abdomen increased to 44 and 45 inches, and the vomiting was more frequent. He died after four months' stay in hospital.

Digitized by Google

At the *post-mortem* examination the abdomen was found to contain about fifteen pints of albuminous fluid mixed with innumerable small masses of jelly-like stuff. The parietal peritoneum was thickened to a depth of from two to four inches with colloid growth, which projected like a hernia through the umbilicus and through a median perforation in the linea alba above. These projections displaced the structures of the abdominal wall without infiltrating them. The omentum was a dense honeycomb-like mass of colloid. The liver and stomach were encased by dense capsules of colloid growth, but were not invaded. The intestines were compressed backward, but were not invaded. The kidneys were also free, but the spleen was both encased and abundantly invaded, so that little of its own structure was left.

The specimen of invaded spleen was shown on account of its rarity. This condition was clearly one of invasion and not of infiltration. Two cases of the kind only are recorded in the 'Pathological Transactions,' one by Sir William Jenner and one by Dr. O'Connor. I have found only one other case, which is recorded by Schweninger ('Bairisches ärztliches Intelligenzblatt,' No. 32, 1876).

May 3rd, 1881.

---

12. *Cystic degeneration of breast.*

By C. Mansell Moullin, M.D.

[Plate V, figs. 3 and 4.]

The tumour was removed from the breast of an unmarried woman, 40 years of age. It had grown rapidly, having only taken six months to attain a size three or four times as great as the opposite one; in other respects it was in no way remarkable —smooth, conical, soft and uniform, with skin and nipple quite natural, except for some enlarged veins.

After removal, the tumour presented on section no trace of normal breast structure, it seemed to consist of nothing but a mass of fibrous tissue studded in every direction with minute cysts, the largest as big as a pea, spherical, with a distinct lining membrane,

Digitized by Google

and containing a clear gelatinous fluid, sometimes stained green or brown. There was no trace of intracystic growth. Here and there the cysts were grouped together more closely than elsewhere, but that was the only trace of arrangement; and sometimes, between them could be seen triangular patches of softening (? mucous) in the fibrous tissue. The minute structure, and especially the way in which the change arose, were best seen in some outlying lobules dissected away subsequently.

Sections made through these, after hardening, showed that the change was not limited to any one point but commenced in many scattered places simultaneously; here and there lobules, already far advanced in degeneration, being seen surrounded by others quite normal. In all places the interlobular tissue remained unchanged.

The first thing visible was a rapid growth of small round cells in between the acini of a lobule (sometimes near the duct, not nearly always), so that each terminal dilatation was soon separated off from those round it by rows of cells which developed into fibrous tissue and formed layer on layer of concentric rings. At the same time the acini dilate, so that there appears a central cavity, which only exists in name in the natural resting gland, and the epithelium lining their interior alters its character and multiplies with such rapidity, that sometimes long columnar cells may be found heaped up three or four deep. In general the proliferation is only sufficiently rapid to furnish the interior of each acinus with a single layer. Later, as the cavity enlarges, many of these cells become spherical, granular, and melt away, while the rest form a layer of squamous hexagonal cells lining the cyst wall.

Sometimes two or three acini join together, or, with the end of a duct to form one cyst; more often each acinus developes separately.

The most characteristic change is that which concerns the membrana propria. On the outside of the acini may be seen delicate nuclei, faintly marked with a little granular protoplasm round; as the acini enlarge these become more definite, and the cell substance assumes a stellate form. Later, when the acinus becomes a cyst, these cell-like bodies assume a spindle shape, and then each little cavity is hooped round by parallel rows of long spindle-shaped cell-like structures, nucleated and well marked in their centres, fainter and more granular at their ends, lying side by side and fitting in to one another, but not nearly touching. For filling in the space between them, connecting them together is a delicate, but

Digitized by Google

strong hyaline membrane, staining with difficulty, bearing such a relation to these cells that they are but thickenings on, or rather in, its substance, projecting in relief on either surface (like the ribs on a leaf), so that when cut across obliquely their ends being thicker project beyond the line of section of the intervening membrane; and this membrane, which is capable of being isolated (with its cellular thickening) in long strips, is as separate from the fibrous tissue on its outer side as it is from the epithelium on its inner.

All these changes, the ingrowth of fibrous tissue between the acini of a lobule, the dilatation of the acini, the proliferation of the epithelium, and the alteration in its shape, first to columnar and then to squamous, and the development of the membrana propria of the acinus into a cyst wall, taking place together, cause the tumour itself to assume the appearance of a mass of fibrous tissue, studded everywhere with small cysts.

The changes themselves are similar in direction to those that take place in a chronic mammary tumour. For in this form of tumour I have succeeded in demonstrating a basement membrane similar to the earlier stages of what has here been described as the cyst wall, and resembling the account given by Franz Boll in 'Stricker,' of the basement membrane of the lachrymal gland; but as the change progresses beyond that generally seen in that form of tumour, and is general in the breast tissue, not limited to any one point but commencing in many, I have simply left the name of cystic degeneration. *March 15th*, 1881.

Report of the Morbid Growths Committee on Mr. Moullin's specimen of cystic degeneration of the breast.

We have examined sections of Mr. Moullin's specimen, and can confirm his observations on the cysts with epithelial lining and clearly-defined and thickened membrana propria; also, that the substance between the cysts is almost entirely fibrous tissue. But we have not succeeded in tracing the process by which he believes the cysts and fibrous tissue to have been formed. Indeed, we are inclined to regard the changes as essentially of the lining membrane and epithelium of the ducts and acini of the gland. We do, indeed, see collections of cells, such as the reporter (Mr. Moullin) describes, which are apparently outside the ducts. But, after a close examination, we have convinced ourselves that these are but sections of ducts

Digitized by Google

which are completely full of altered epithelium. We think, therefore, that the disease is really ill-developed carcinoma; first, on account of the great thickening of the membrana propria and the alteration in the character of the epithelium, together with well-marked signs of cell proliferation; while the adjacent fibrous tissue exhibits scarcely any signs of activity. Secondly, because many of the smaller sacs are filled, or almost filled, rather than lined, with epithelium, and there are appearances which indicate endogenous cell formation. Our view is strengthened by the age of the patient and the diffuse character and rapid progress of the tumour. A well-marked membrana propria may occasionally be distinguished around the cell masses in carcinoma of the breast, and, we believe, exists always, as Langer[1] has more than hinted, in the acini of the normal gland. If we ventured to suggest a theory of the formation of the cysts it would be as follows:—That the changes in the epithelium block up the smallest ducts; that with the proliferation of the cells there is also in the acini a slight secretion of fluid; that this fluid, finding no escape through the occluded ducts, collects within the acini, and distends them into tiny cysts.

HENRY T. BUTLIN,
May 11*th*, 1881. JAMES F. GOODHART.

---

13. *On the connection between disease of the nipple and areola and tumours of the breast.*

By GEORGE THIN, M.D.

[With Plate XXX.]

IN the following paper I give an account of two cases in which a diseased condition of the nipple preceded the development of a tumour in the breast. They belong to the class of cases which have been recently described as instances in which cancer of the mammary gland followed a condition of the nipple described as eczematous. I have previously examined and have, in a paper read

[1] Stricker's 'Handbuch,' vol. i, p. 629. 1871.

Digitized by Google

Digitized by Google

DESCRIPTION OF PLATE XXX.

Illustrating Dr. Thin's paper on Disease of the Nipple in relation to Mammary Tumours. From drawings by himself.

Figs. 1, 2, 3, and 4 are drawn from sections of the tumour and from the nipple in Mr. Morris's case.

Figs. 5, 6, 7, and 8 are from sections of the breast in Mr. Lawson's case.

FIG. 1 shows the arrangement of the epithelial growth in round masses. (× 25 diameters.)

FIG. 2 shows the columnar epithelium which forms the outermost cells in some of the masses. (× 500 diameters.)

FIG. 3.—An epithelial mass, in which the *débris* of the central cells is bounded externally by columnar epithelium. (× 150 diameters.)

FIG. 4.—Transverse section of a lactiferous duct in the nipple, which is filled with new epithelial growth. (× 75 diameters.)

FIG. 5.—*a*. Epithelial growth in which a disposition to the formation of columns could be observed. *b*. Fat. (× 14 diameters.)

FIG. 6.—Showing the relations of the epithelial growths to the fat and connective tissues of the breast. *a*. Tubular-shaped mass of epithelium, from which the cell *débris* has partly fallen out. *b*. Fat.

FIG. 7.—Showing the small columnar cells which bound the epithelial masses. (× 500.)

FIG. 8.—The epithelial growth in its early or formative stages, showing the tubular nature of the structures of which it is composed. (× 100 diameters.)

Digitized by Google

Fig. 1.

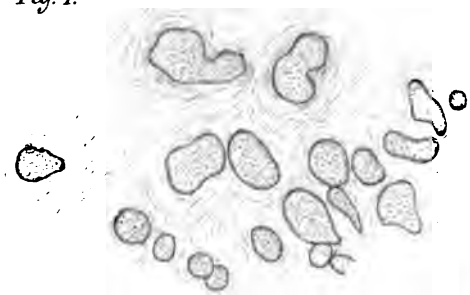

Fig. 2.

Fig. 3.

Fig. 4.



Fig. 5.

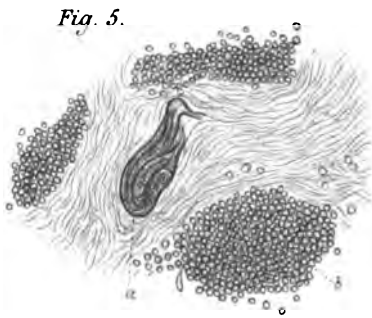

Fig. 6.

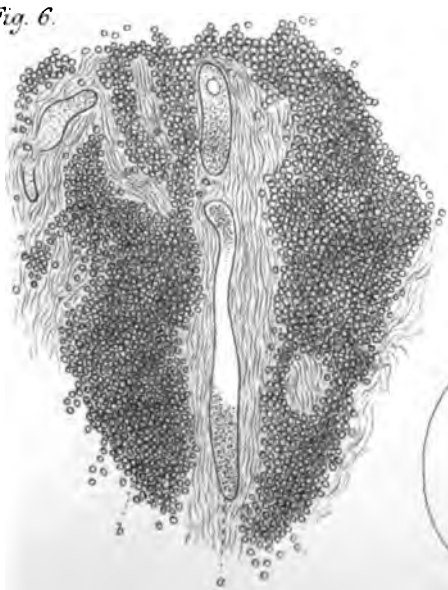

Fig. 8.

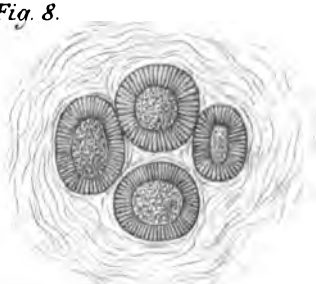

Fig. 7.

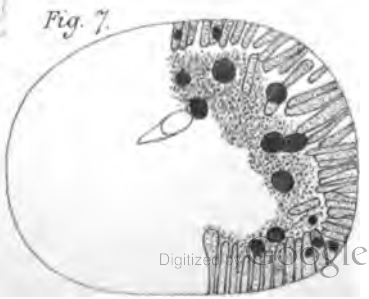

Digitized by Google

Digitized by Google

before the Roy. Med. and Chir. Society, reported on four such cases,[1] and shall conclude this paper with a statement of the points on which the whole six cases agree.

Margaret K—, a single woman, aged 49, was admitted into the Middlesex Hospital on July 8th, 1880. Six years previously the nipple of the left breast had been pricked more or less for some days, "perhaps a week or two," with a needle, which she afterwards found in her stays. During this time there had been slight bleeding. After all external cause of irritation was removed the linen was often found glued to the irritated surface by a yellowish, watery discharge. The nipple then began to swell. Six weeks after the injury it was found "raw" by a surgeon at the Westminster Infirmary, where she had gone on account of a cut hand, and was poulticed and dressed with zinc ointment.

The sore spread, and, although continually under treatment by ointments and lotions, it never healed. Two years before admission nitrate of silver was applied, and the nipple disappeared. The raw surface then spread more rapidly, and quickly attained its present area.

On admission, it is reported on the hospital case sheet that there was "a nearly circular superficial ulceration, two inches in diameter, of which the centre point is now a depression. The hole is glazed over with a gelatinous, yellowish secretion, and is large enough to admit the tip of the index finger. It is shallow, and has an irregularly ulcerated margin. Beyond the hole, on all but the lower and inner side, and continuous with its margins, there is a bright-red, eczematous surface, for the most part moist and glistening, but in numerous places interspersed with dull, cicatrix-like spots, which are more numerous and larger near the circumference of the diseased area .... Everywhere the margin of the disease is sharply marked off from the healthy skin .... The whole of the mamma to the outer side of the sore is fuller, harder, and more resisting than the rest of the gland. The axillary glands on this side are enlarged and hard."

The breast was removed by Mr. Morris and sent to the Museum of the Royal College of Surgeons.

On microscopical examination the diseased skin was found in the central parts to be completely denuded of epidermis. The free surface

[1] See a paper on "Malignant Papillary Dermatitis of the Nipple," &c., in the 'British Medical Journal,' May 14th and 21st, 1881.

Digitized by Google

was here formed by a connective-tissue framework filled with cancerous epithelium, covered with a very thin stratum of granulation tissue. It was, in effect, an ulcer with cancer elements for its base. Beyond this cancer area, outwards towards the healthy skin, there was for a short distance a part in which the epidermis was preserved, ragged and disintegrated on the inner margin, but fairly entire and normal beyond this immediate margin. In the part to which I now refer the connective tissue of the *pars papillaris corii* had disappeared, and its place was occupied by a thick, dense stratum of exudation cells. The cancerous epithelium formed the inner boundary of this stratum, and was evidently advancing horizontally into it.

The tumour in the breast was composed on its periphery of dense fibrous tissue. Towards the centre it was found to consist, on section, of numerous round or oval masses of cells lodged in an alveolar framework. There was very little cell exudation observed, and there was a complete absence of small columns of cells penetrating the connective tissue irregularly in different directions, as is the case in ordinary scirrhus tumours (parenchymatous cancer). In many of these cell clusters the central cells had broken down, and on the wall of the cavity in which the cell mass lay the bounding cells assumed more or less the columnar type. In some of the cavities the lining cells were typical columnar epithelium.

In another part of the tumour which was examined the extreme edge of the epithelial zone was found to consist of dense fibrous tissue, with thinly scattered, circular cell columns of small size. In these columns a slight lumen had been formed by breaking down of the central cells, the peripheral cells being a columnar epithelium.

The essential features of the tumour were to be found in the amount and denseness of the fibrous tissue on the periphery and in the columnar type of the epithelium.

The above description will suffice to enable pathologists who are familiar with breast tumours to refer this one to a class of growths which are variously named by different pathologists. The circular cell groups, the round columns, and the columnar epithelium, mark it as one of those growths that take their origin in the duct epithelium, and which, I believe, would most appropriately be termed duct cancers.

The parts of the tumour in which the columns were round, small,

Digitized by Google

and characterised by a lumen, present similar appearances to those figured as examples of so-called *adeno-fibroma*.

The parts in which the cell groups were large and numerous would be generally considered as characteristic of developed cancer.

The other case is that of a patient of Mr. George Lawson, who excised the breast and sent it to the Museum of the Royal College of Surgeons.

An unmarried woman, aged 57, had suffered for more than twelve months from a superficial affection of the nipple, which was termed by Mr. Lawson "eczema," and was recognised by him as similar in its nature to a case previously under his care, in which the affection of the nipple was, after three years, followed by a tumour in the breast. The disease of the nipple lasted more than twelve months, although various remedial measures were tried. There was no pain in the breast and no enlargement of the axillary glands.

Mr. Lawson informs me that neither Sir James Paget, who saw the patient in consultation, nor himself, discovered a tumour in the breast. The operation performed by Mr. Lawson was purely prophylactic, and was intended to forestall the formation of a breast tumour.

The breast as I saw it at the College of Surgeons Museum, seemed to be simply a large mass of solid fat. On its being cut into two pieces, the surfaces exposed confirmed this supposition. The fat was permeated by delicate streaks of fibrous tissue.

The area of diseased skin over the areola could be still recognised; even after the long maceration of the tumour in spirit being distinguished by a rugged, shrivelled appearance, which extended for a considerable distance beyond the nipple, and it had a distinct margin. Microscopical examination of a part of it which was excised showed that the epidermis was thickened and entire. The *pars papillaris corii* was destroyed, and its place occupied by a dense mass of exudation cells.

Microscopical examination of the tumour displayed the same general structure which was seen by the naked eye—large unmixed lobules of fat permeated by narrow tracts of white fibrous tissue. In the tracts of fibrous tissue an epithelial cell formation was found, which I regard as giving a key to the nature of the tumour. These cell structures were sometimes found in long solitary columns, sometimes in rounded masses, composed of a conglomeration of tubular formations, and sometimes as well-defined round tubes lying

Digitized by Google

close and parallel to each other, and having a central lumen. The cells were all small, and had so little stability that they were very badly preserved. The border cells of the larger tracts were columnar, and the sections of the smaller tubes showed that they were formed of columnar epithelium, the long axis of the cells being directed to the central axis of the tube.

The epithelial structures were those usually described by English pathologists as characteristic of adenoma.

These epithelial structures, as was evident from their size, arrangement, and form, were not parts of the normal gland more or less modified, but were new formations, and were probably all connected together, as each fibrous band lodged one or more epithelial growth.

The three elements—fat, fibrous tissue, and epithelial structures —which formed this large mamma must all have been more or less of new formation. The most important element in such a case is the epithelium. The quantity of fibrous tissue or fat in a breast may vary considerably from time to time without producing any change that need be considered abnormal. With the epithelium it is different. A free and abundant growth of epithelium in a quiescent mammary gland is in itself disease, and is certain to effect secondary changes in the connective-tissue elements. In this case the changes effected by the growing epithelium were an unusual formation of fat and a very moderate, but constant, formation of fibrous tissue. The epithelium never came into immediate contact with the fat, but always stimulated a growth of fibrous tissue around it as it grew.

The tumour would probably be termed by some pathologists an *adeno-lipoma*.

These two cases are the fifth and sixth in which I have examined the skin and mammary growths in this peculiar condition, and the number is sufficient to afford material for an attempt at generalisation.

First, as regards the skin. It was natural that a red, moist surface, which did not ulcerate, should be considered as eczematous, and the term eczema of the nipple was applied to the affection when the first cases were described. In none of the six cases with which I am cognizant, however, could this term be applied in the strict scientific sense of the word. In all of them the area of the affected skin extended beyond the cancerous infiltration of

Digitized by Google

the ducts, in some of them to a considerable distance. In all there was more or less affection of the epidermis, which varied in extent, however, in the different cases. In some of them there was thickening, with elongated papillæ, and with comparatively little actual destruction; in others there was great destruction of epithelial cells and disintegration of the epidermic membrane. In none of them, however, had the epidermis completely disappeared. The essential features of the disease are to be found in the papillary layer of the corium. The distinction of the *pars papillaris corii* and the thicker and stronger *pars reticularis corii* must be borne in mind in order to appreciate the changes in this affection.

It is a distinction of importance in the pathology of the skin. Several morbid processes in which the *pars papillaris* is destroyed leave the *pars reticularis* in its integrity. In lupus erythematosus, for example, there may be actual destruction of tissue in the papillary layer, but the deeper structure of the corium remains entire. So in some cases of rodent ulcer. The epithelial cell growth, which is characteristic of this disease, completely destroys in some cases the papillary layer and leaves the thicker layer uninjured. It is in this weaker layer of the connective tissue of the cutis that the change takes place which produce the disease of the nipple and areola which I am discussing. These changes consist in a complete destruction of the connective tissue of the layer, the space which it occupied being filled with a dense mass of exudation cells. The persistence of the epidermis, in a more or less complete state, distinguishes the condition from that of ulceration.

It is very desirable that a distinctive name should be given to this affection, and that the name should, at least for the present, not involve any theory that is likely to be subject of dispute. Such terms as eczema and psoriasis are open to the objection that they are already applied to definite and distinct diseases. To speak of this affection as eczema of the nipple or psoriasis of the nipple is likely to convey the idea that the superficial skin affection is really eczema or psoriasis. The histological examination of these six cases has shown that this is not the case. In eczema and in psoriasis the integrity of the connective tissue of the corium remains undisturbed, in both affections the seat of disease being in the epidermis.

The distinction between the condition I have described and

Digitized by Google

that which is characteristic of eczema and of psoriasis, is not only established by microscopical observation but is borne out, as I believe, by clinical facts. In an advanced case which I had the opportunity of observing before operation, the participation of the connective tissue in the disease was very evident to me, and in a case which I have recently seen in the very earliest stage the subepidermal character of the affection was beyond question.

It will probably be convenient to speak of this disease as *malignant papillary dermatitis of the nipple*. The term *malignant* would, in this case, imply nothing as regards the anatomical changes in the skin, but would mark the incurable nature of the affection, and its association with cancer of the breast, whilst the words *papillary dermatitis* would indicate the seat of the disease in the cutis, and mark its distinction from eczema. These terms, applied to the nipple, would specify an affection which is different from all other known morbid conditions of that part.

Secondly, the nature of the breast tumours.

While not one of these tumours exactly resembled any one of the others, they had yet certain negative and positive points of agreement.

When an ordinary scirrhous cancer of the breast is examined with sufficient minuteness it will be found that the epithelial growths not only increase by direct extension of the newly-formed epithelial tracts and masses, but that the normal epithelial elements in the acini adjoining the tumour take on morbid growth.

The cells primarily involved are the secreting cells of the terminal vesicles of a lobule. Waldeyer,[1] who has enlarged on this fact with great detail, has therefore proposed to term such tumours *parenchymatous* cancers of the breast. I have gone over the same ground in a few cases, and I can testify to the fact. Most, but not all, of the tumours termed by surgeons scirrhus are of this kind, and the appearances seen in sections of such tumours are too well known to make it necessary for me to refer to them further.

There is another variety of cancer of the breast described by Waldeyer under the name *fibro-carcinoma cysticum mammæ*, which he has traced to the epithelium of the lactiferous ducts as its point of origin. I believe this to be the same kind of growth which is described by Cornil and Ranvier[2] as *carcinóme villeux*. These

[1] Virchow's 'Archiv,' vol. 41, p. 470, and vol. 55, p. 76.

[2] 'Manuel d'Histologie Pathologique,' vol. ii, p. 1167.

Digitized by Google

observers remark that this tumour probably takes its origin in the epithelium of the lactiferous ducts, and refer to the layer of columnar epithelium which lines the wall of the cavity in which the cell masses are contained.

It is to this form of cancer, to which I believe no better name than *duct cancer* can be given, that all the six tumours which I have examined belong. It is very remarkable that in none of them has the tumour been of the *parenchymatous* variety—the ordinary scirrhous type.

Whilst they differ in many respects from each other, they agree in three essential features.

The cells form, more or less perfectly, round columns and masses, with comparatively little tendency to diffuse infiltration of the connective tissue. There is a tendency, more or less pronounced, to the formation of columnar epithelium, and the ducts are blocked and distended with epithelial cells. In some of the tumours (those which had been examined in sufficient detail), new growths are found springing from the ducts.

These characters are not constant in every part of a tumour, but will always be found when a sufficient extent of the growth is examined. In the skin and central parts of the tumour they may be missed entirely, the appearances in these situations being frequently the same as those found in parenchymatous cancer, but if the deeper surface and border of the growth are examined they will be discovered.

The tumours to which Waldeyer has given the name *fibro-carcinoma cysticum mammæ*, and Cornil and Ranvier that of *carcinôme villeux*, and which I have described as examples of duct cancer, are not known by any specific term at present in use amongst English pathologists. They have either been described as common cancers or as adenomas, according as the changes were more or less marked. It must be borne in mind that the use of the term adenoma is very different in England from what it is in Germany and France. In England a tumour is called adenoma or adenoid when the cell formation is in round columns, with or without, or at some parts with, and at other parts without, a central lumen. A series of such columns, parallel to each other, representing so many newly-grown or partly-developed ducts, would in England be called an adenomatous growth. Billroth and Cornil and Ranvier, on the other hand, require for their ideal of an adenoma of the breast an

Digitized by Google

imitation of the structure of the mammary gland, that is to say, not only ducts, but ducts with terminal vesicles—lobules and acini. Such growths—tumours coming almost up to this ideal—exist, but they are, as Billroth has expressed it, "extremely rare"[1]—an expression which, as applied to adenomas of the breast, would sound to English surgeons and pathologists as a very extraordinary one.[2]

Between the ordinary adenoma of the English pathologist and the carcinôme villeux of Cornil and Ranvier there exist transitions, not only in a series of tumours but in different parts of the same tumour, and I regard a well marked case of duct cancer like that of Mr. Morris's, which I have just described as an exaggerated condition of the pathological change usually considered in this country as characteristic of adenoma.

Histologically, the two cases described in this paper represent the two extremes in my series of six cases. In Mr. Morris's case the development has, in extent of epithelial development and in the amount of fibrous change, more closely than in any of the others simulated in some respects that of the more common cancer; whilst in Mr. Lawson's case the structure is so purely that of duct-like columns and tubes[3] that I doubt whether the tumour will be considered a cancer at all.

Mr. Butlin has described, in the 'Transactions' of the Royal Medical and Chirurgical Society, four cases in which this disease of the nipple preceded the development of cancer of the breast, and has clearly shown that the lactiferous ducts are in this affection distended by cancerous epithelium. I believe from the evidence of Mr. Butlin's plates that his tumours and mine were of the same kind. Further, if Mr. Butlin's drawings are compared with fig. 15, plate vii, in Waldeyer's memoir—the figure intended to show the characteristic appearances of the fibro-carcinoma cysticum mammæ—it will be evident, as I think, that his cases are also identical in kind with those described by the German author under that name.

[1] "Ausserordentlich selten."

[2] One gentleman alone during his period of surgical registrar to a large metropolitan hospital made, as he informs me, a collection of forty tumours called adenomas in London.

[3] Therefore an "adenoma." Poroma (πορος, a duct) would have been a more accurate term.

Digitized by Google

Before the material for a final generalisation on the nature of these tumours is complete, details of more cases are required, and especially full drawings of the histological appearances. What I hold is up to the present time made out, may be briefly summarised as follows:

1. The affection of the nipple is neither eczema nor any known specific skin disease, but a destructive dermatitis of the papillary layer.

2. The breast tumours consist of epithelial growths which take their origin from the epithelium of the lactiferous ducts, and which retain the specific characters of that epithelium.

3. A complete account of an instance of the scirrhus or parenchymatous type of cancer in connection with this affection has not yet been published.

4. A local affection of the points on the surface of the nipple which correspond to the mouths of the lactiferous ducts has preceded in well observed cases the extension of the disease over the surface of the nipple and over the areola.

5. The hypothesis which best explains the incurable dermatitis of the nipple and the extension of cancerous development downwards through the ducts, is that a change takes place in the columnar epithelium at or near the mouths of the ducts, which exerts a destructive influence on the adjacent connective tissue and propagates an abnormal growth of duct epithelium. Such a change is in reality the first stage of cancer. The long duration of the local symptoms before the development of a perceptible breast tumour is analogous to the comparatively slight and very chronic cancerous changes that characterise the first stage of rodent cancer.

March 15th, 1881.

---

14. *Cancer of the right pleura, following cancer of the right mamma successfully removed two years before.*

By Samuel West, M.B.

Louisa B—, aged 43, was admitted into Victoria Park Chest Hospital on November 8th, 1880. She was a married woman, had had twelve children, all dead (eleven born dead, one died young), and had been always delicate.

Digitized by Google

Seven years ago she noticed a lump in the left breast, which slowly and steadily increased without pain for four years, and then became the seat of tearing pain. Eighteen months ago the breast was removed at the German Hospital at Dalston, the wound healing satisfactorily.

In August, 1881, she was attacked rather suddenly with dyspnœa and cough, and at the same time with severe pain in the upper part of the sternum and in the lower part of the right side of the chest, and since then she had been troubled with cough and mucopurulent expectoration, and occasional night sweats. She had rapidly lost flesh and strength, so that for the last month she had been confined to bed.

Fourteen days ago she noticed a small lump above the cicatrix on the left side and two or three other small lumps in the right axilla. Physical examination by Dr. Thorowgood established—(1) the existence of these lumps, the cicatrix in the left mammary region being perfectly healthy; (2) a considerable fluid effusion on the right side, the apex of the heart being felt and seen one inch outside the left nipple; and (3) the existence of a mediastinal tumour. This with the cachexia and history, led to the diagnosis of a malignant intestinal tumour, with secondary affection of the right pleura, and effusion. The dyspnœa increasing a trocar was introduced, and about one ounce of blood-stained serous fluid removed. A week later a second paracentesis was performed, but this time without any result.

A few days before the patient's death, some hard immovable nodules appeared along the right border of the sternum and in the inner part of the right mamma.

Beyond a slight enlargement of the superficial veins in the right axillary and mammary region, with a little œdema there, pressure symptoms were absent.

The patient gradually died of exhaustion, and the *post-mortem* disclosed the following condition of parts:

The nodule above the cicatrix in the left mammary region was of soft cancer. Those to the right of the sternum were directly continuous through the intercostal spaces, with a dense new growth occupying the whole anterior mediastinum. From this it extended in all directions over the whole right pleura, converting it into a mass of almost cartilaginous hardness. The thickness of the new growth was greatest in the lower part. The diaphragm was in

Digitized by Google

places nearly two inches thick, and on section presented the same appearance as the new growth elsewhere. Over the upper lobe of the lung the pleura was half an inch thick, embracing the upper lobe, which was partially collapsed. The lower lobe was reduced to a firm mass two inches long and two wide, compressed round the bronchi leading to it, and covered with the thickened pleura. The cavity left was filled by about 2½ pints of clear brownish-red serum, and into it projected several bosses and outgrowths of the same new growth. The whole of the posterior mediastinal glands were enlarged, though their consistence was less firm. The heart was displaced about one inch towards the left side.

The whole of the peritoneum was thickly sown with small cancerous nodules, most numerous in the reflexion of the peritoneum from the colon, and in the small omentum. There were numerous adhesions between the liver and diaphragm, and these as well as the ligaments of the liver were infiltrated with cancer. The growth had spread from them by direct continuity for a short distance into the liver in several places, but with this exception and the presence of two very small independent nodules of cancer that organ was healthy. The right suprarenal capsule was about three times its normal size, due to the diffused infiltration of cancer in the medulla, which had spread inwards from the peritoneum by the hilus.

Microscopical examination showed the same appearances in all the growths—those of scirrhus.

In the lung there was this peculiarity, that whereas in the common form of pulmonary carcinoma the matrix of the new growth is simply the original alveolar wall, the alveoli becoming filled with cancer cells, in this case, on the contrary, the cancer developed independently in the alveolar wall, matrix and cells being all of new growth, the alveoli being pushed aside and flattened as the cancer grew.

The first point of interest in the case is pathological, the relation between the mammary tumour and the mediastinal growth. Were they independent of one another, or was the mediastinal tumour an instance of the recurrence of the breast disease in a somewhat unusual seat? The latter seems to me the more probable interpretation of the case.

The second point of interest is clinical—the reason of the dry tapping. An ordinary effusion into the pleura occurs under pressure, distends the walls of the cavity, and continues until the pressure from within is equal to the tension of the walls of the cavity

Digitized by Google

and the parts around. When the chest is tapped under these conditions, the pressure from within is relieved, the tension of the parts around comes into play, and fluid is discharged until the pressure from without and within becomes again equal. With the aspirator this tension of the walls is supplemented by atmospheric pressure acting through the trachea and lungs. When an ordinary trocar and canula are used, the force which expels the fluid is the elastic recoil of the distended parts, or with the aspirator the elastic recoil and atmospheric pressure, the amount of which will depend upon the completeness of the vacuum in the exhausting bottle. If the distended parts are no longer elastic, still more if they have been so rigid as to be able to resist considerable external atmospheric pressure, the physical condition becomes such that no fluid could flow, and the result is what is called a dry tapping. A tapping may be dry because no fluid is present, or, as in this case, because the fluid present is under no pressure, the so-called hydrops ex vacuo. *March 15th*, 1881.

---

15. *An epithelial ulcer in the leg with unusual history.*

By JONATHAN HUTCHINSON.

THE subject of the case was a woman, aged 46, who was admitted into the London Hospital, with an ulcer on the side of the leg, which she said had been present and much in its existing condition for ten years. For ten years before that there had been a lump under the skin, which was, however, not ulcerated. The sore presented unusual features. It had dense, elevated, irregular edges, but was not in the least warty. It was perfectly clean and very florid. There was but very little thickening at its base, but it adhered to the deep fascia. (A coloured drawing was made of the ulcer, which was shown to the Society.) In the groin were a number of glands enlarged to the size of cherries. It was chiefly these glands, which had only recently enlarged, which had induced the patient to come to the hospital, but she had for many years been under treatment for the ulcer. I excised the ulcer with the fascia from which it grew, and also took away the enlarged glands.

Digitized by Google

The parts healed well, and six months later there had been no recurrence.

Mr. R. W. Parker was kind enough to make an examination of the structures for me, and found appearances which made him regard it as an epithelial growth springing from a sebaceous gland. From the patient's history it seemed not improbable that an enlarged gland had been present in a quiet state for many years before ulceration occurred. The surgeon who had attended the woman confirmed her statement, that it had been for long in its present condition, with but little tendency to increase in size. He stated that it had at times presented a dirty fetid surface.

November 3rd, 1880.

Report of the Morbid Growths Committee on Mr. Hutchinson's tumour of the leg.

The specimen submitted to us for examination consists of an oval, slightly lobulated tumour, about two inches in its greatest diameter. In the centre is a deep ulcerated cavity. The marginal parts are covered with a thin layer of skin. On the under surface is an adherent piece of the fascia lata of the thigh. Accompanying it are two lymphatic glands removed from the groin. The glands are considerably enlarged. The greater part of them is pink in colour, but scattered through their structure are opaque whitish patches.

Sections have been made for microscopic examination from the part of the primary tumour covered by skin and from the lymphatic glands.

Sections of the part of the original tumour covered with the skin show to the naked eye a thin cuticular layer staining darkly with logwood, beneath which lies a uniform layer one eighth of an inch in thickness. Beneath this, again, the structure is composed of a tissue having a similar appearance, throughout which are numerous rounded spaces, the contents of which are darkly stained. These spaces vary in size from one eighth of an inch to specks scarcely visible without a lens.

On microscopic examination the epidermic covering is apparently normal in structure. It is seated on papillæ of moderate size. There are no sweat glands, sebaceous follicles, or hairs. Beneath the papillæ is a layer, about one eighth of an inch in thickness, of newly-formed fibrous tissue, crowded with small round cells, and

Digitized by Google

containing a moderate supply of vessels and no recognisable yellow elastic tissue. Beneath this lie the spaces before noted as visible to the naked eye. They lie in a stroma of new connective tissue similar to that above described. The larger spaces are seen under the microscope to be subdivided by delicate processes of the stroma entering at right angles to the wall. The spaces are filled with epithelial cells. The cells are somewhat irregular in form; they are very small, sometimes rounded, sometimes approaching squamous epithelium in outline. They contain single large nuclei, and frequently show a tendency to arrange themselves in imperfect, but undoubted, nests or globules. No prickle cells are present in any part. The arrangement of the epithelial cells in rounded spaces of great size, subdivided by processes of connective tissue, has an obvious resemblance to that of a gland, but we find nothing which would justify us in forming any definite opinion as to the exact structure in which the new growth has started, though it can hardly be doubted that it has originated either in the sweat glands or sebaceous follicles.

Section of the lymphatic glands show that in most parts the reticular stroma has undergone considerable thickening, apparently as a result of chronic inflammation. The capsule is in some parts about a line in thickness. Scattered throughout the gland in numerous parts are accumulations of cells closely resembling those in the spaces of the primary tumour, but they do not show the same tendency to arrange themselves in imperfect globes. The central parts of some of the groups have fallen out of the sections, but the marginal cells in the spaces so left do not show any signs of degeneration. In the greater part of the gland, beyond the thickening of the stroma, there is nothing abnormal to be noticed.

We therefore consider the tumour to be a variety of epithelioma, differing, however, very considerably from the ordinary "lobular" type. The structure of the primary growth resembles rather closely that which has been found in some of the specimens of rodent ulcer that have been recently reported to the Society. A further point of resemblance to rodent ulcer is the extreme chronicity of the growth, but a wide difference between the two exists in the fact that in the present instance the lymphatic glands are affected with secondary deposits.

MARCUS BECK.
RICKMAN J. GODLEE.

Digitized by Google

16. *A specimen of mammary adeno-fibroma, containing an adjacent piece of carcinoma.*

By Rushton Parker.

The patient is a Mrs. J—, wife of a farmer in Anglesey, introduced to me by Dr. Hodge, of Liverpool, in October, 1880, for operation.

She was then aged 42, had been married fifteen years without issue, and had always enjoyed pretty good health, though not considering herself strong.

For three years she had noticed in her left breast a lump, which I found in the upper inner corner, about the size and shape of a small walnut, conveying to the touch a feeling of textural continuity, strangely associated with some free mobility.

Neither the nipple nor the lymph glands presented abnormal features. For reasons to follow I decided, when operating, to incise the growth, and be guided by appearances in completing the diagnosis, so as, if possible, not to needlessly sacrifice the whole breast. This was done on 19th October last, and the evidences of carcinoma appearing wholly positive, the entire gland was removed, the patient making a good and simple recovery within a month.

The pathological features of this case, taken alone, call for but slight consideration, except as a histological curiosity; but, joined to the clinical signs which they justify and explain, they will, I trust, prove as interesting to others as they have been instructive to myself. I will, therefore, refer to them with due regard to brevity and the purposes of this Society, though it will be convenient to relate them in the light of the impression which they produced upon myself.

A tumour of that size, at the age of 42, feeling to a marked degree part and parcel of the mammary gland, would, on the score of numerical probability, be likely to be a cancer; and a previous duration of three years, though somewhat long, would, I venture to think, not be inconsistent with that view. But the unmistakable though additional, mobility was in a tactile sense highly suggestive of a small chronic mammary tumour, such as the ordinary adeno-fibroma of young women—say under 30. The age of the patient,

Digitized by Google

again, was perfectly consistent with the presence of a non-malignant adenocele, though at that age I considered such a growth would have reached a greater size, or would have had greater elasticity or other features suggestive of a coarsely cystic formation. I had not previously met with a small adeno-fibroma commencing so late in life, and the great frequency of malignant tumours of all kinds, and of mammary cancer especially, in the country districts all about and near Liverpool, draws attention to the suggestions based upon numerical probability alone. If the woman had been under 30 the mobility of the growth would have been sufficient to almost exclusively suggest adeno-fibroma; if the growth had been less mobile her age would almost have excluded all but cancer—so I thought. The preliminary incision, then, was required by prudence, and the view it furnished was such as is often suggestive of a shrinking cancer—a groundwork of fruity appearance—not unlike cooked apple or pear, with yellow dots, stars, and streaks.

It is not difficult, after the event, to attach some importance to the situation of the growth in the inner and upper part of the gland, as presumptive evidence in favour of adenocele rather more than of cancer; but at the time I would not allow any doubtful considerations to permit delay on the score of possible benignity. The medical opinion she had taken was already on the side of carcinoma, and she was quite prepared to have it corroborated; while I, on the other hand, wished to save the rest of the gland, should the growth prove non-malignant.

After the operation, on dissecting the breast and its tumour from the pectoral surface, I found the growth separated from the subjacent fascia by a distinct bursa, into which projected a white nodulated lobe. This, on section, showed the most ordinary appearances of adeno-fibroma, and though contiguous to, was quite distinct from, the fragment which had presented in the first incision, and which I now had come to think was only another simple instance of cancer.

Hence the very reasonable difficulty, owing to equivocal circumstances, in the precise diagnosis. The preparation of this and some of the other specimens, which I show this evening for microscopic purposes, was undertaken for me by Mr. Paul, our pathologist, in Liverpool; while the rest were prepared by myself.

The adeno-fibroma is plain enough, consisting of wavy fibrous tissue, gland acini, and ducts, a portion of the fibrous arrangement

Digitized by Google

however, being highly charged with spindle-cells, and the ducts showing a distorsion suggestive of an incipient cystic condition.

The other lobe, while composed of columns of aggregated cells, more or less widely separating the intervening fibrous bands, and making of them a distinct alveolar stroma, and while fulfilling most of the verbal and many of the ocular conditions of carcinoma, is still sufficiently equivocal to warrant me in pausing before attempting to positively assert its cancerous nature. I suppose it is extremely rare for cancer and adeno-fibroma to be combined in molar juxtaposition. The only instances I have been able to find are two quoted by Langhans in Virchow's 'Archiv,' vol. 58, and these are unrepresented in drawing, as, alas! are all my specimens, as far as the histology is concerned.

Few practical pathological histologists would hesitate to ascribe the appearances in question to carcinoma pure and simple, had the clinical signs been purely suggestive of the same disease, and had the adeno-fibroma been absent; but should the settlement of this question be not easily possible this evening, and should you, sir, and the Society deem it worthy of further investigation, it would gratify me to have the advantage of a report by a Committee of Morbid Growths. *April 5th*, 1881.

Report of the Morbid Growths Committee on Mr. Rushton Parker's case of adeno-fibroma and carcinoma affecting the same breast.

The specimen submitted to us consists of a small piece of the tumour, preserved in alcohol. A section cut from the corner of this presents the following appearances:—To the naked eye it distinctly consists of two parts, separated from each other by a transparent band about one twentieth of an inch in width. The smaller part has the appearance of being a portion of a globular mass, which under the microscope shows the ordinary structure of an adeno-fibroma of the breast, the stroma being partly fibrous and partly spindle-celled. The larger part, on the other hand, is a typical example of scirrhous cancer. We therefore fully confirm the accuracy of the description given by Mr. Rushton Parker.

MARCUS BECK.

May 16th, 1881. RICKMAN J. GODLEE.

Digitized by Google

17. *Hyaline adeno-myxoma of breast.*

By RUSHTON PARKER.

MRS. O—, aged 45, was introduced to me by Dr. J. E. Dimond of Liverpool, in January, 1879. She had been married ten years, and had had three children, and is a strong woman. The lump had been noticed by her for seven or eight years, but by her husband when they were first married. The right breast appeared greatly enlarged, as if occupied by a good-sized orange, at the outer upper corner. The growth felt smooth, lobulated, firmly elastic, and heavy, irregularly oval, and freely movable in every way. The rest of the breast felt healthy. The tumour had grown slowly until about March or April, 1878, when the increase was more rapid and accompanied by pain. Dr. Dimond thought it was a chronic mammary tumour, and I thought the same, and agreed to remove it, probably without interfering otherwise with the breast. This was done on the 24th January, 1879, and the wound healed in about six weeks. The patient has since continued in good health, with a perfectly sound cicatrix and symmetrical breasts, and was seen by me last week free from disease.

The tumour on section showed a gelatinous structure, opalescent, pale pink in the main, and exuding a colourless juice, drawn into long strings by objects touching it. There were several lobes divided by thin fibrous septa, and a central, many-chambered cyst, about the size of a walnut, with a dull white lining and a few bands and pedunculated polypoid projections. The surrounding solid part was in concentric lobes, among which was a yellowish-white, lymphy-looking mass, about one inch by three quarters, oval in section. The rest were uniform in colour and consistence, with often a radiate structure, all shining and glistening like jelly. One superficial small cyst, with coffee-ground-like gelatinous fluid contents, was cut across. Some were unopened. Other small cysts, with intracystic, solid, pedunculated growths, were observed.

Microscopic examination showed a pure myxomatous structure of closely aggregated, multipolar cells, connected together by a delicate meshwork of fibres. In some of the sections were here and there a glandular acinus with its epithelium.

Digitized by Google

The growth is therefore an adeno-myxoma, and would appear to derive its main interest, in a pathological sense, from the fact that it is distinct, isolated, and of a hyaline character. This specimen lacked the glassy purity and absence of colour which characterises some typical myxomas seen in other localities; but from the mammary gland it is the only specimen of myxoma which I have yet seen or heard of possessing the hyaline character at all. Of chronic mammary tumours or adenoceles not showing, either to the naked eye or under the microscope, the firm structure so easily recognised as adeno-fibroma, but roughly resembling, on section, certain fruits, such as the orange or shaddock, in apparent juiciness, though exuding none under any circumstances, I have seen a number of examples. They are, in fact, well known, and appear not to be uncommon, and subsequent microscopic investigation has revealed the myxomatous structure, but none of them have been hyaline or possessed of the stringy mucus freely escaping in long ductile threads. *April 5th*, 1881.

---

18. *Acinous adenoma of right breast.* (*Card specimen.*)

Exhibited by RUSHTON PARKER.

MRS. K—, aged 62, mother of seven children, born between her twentieth and forty-second years.

Right breast: tumour spheroidal, size of small hen's egg, consisting of a fibrous groundwork, enclosing spherical spaces filled with large epithelial cells, not unlike those of sebaceous glands. Visible cysts from $\frac{1}{12}$ in. diameter downwards.

Under microscope, structure best seen in smallest cysts, which are lined with, usually, two layers of cells in regular order. Other contents granular, or a separate plug of cells and *débris*.

Duration: noticed two years before operation; attributed to a fall, in which the right shoulder and breast were struck and the skin over them blackened. Excised by Mr. J. P. Harris, Liverpool, January, 1872. Patient living and free from breast disease, March, 1881, aged 71.

Digitized by Google

19. *Tubular adenoma of left breast.* (*Card specimen.*)

Exhibited by RUSHTON PARKER.

WOMAN, aged 49, married many years, one miscarriage, no children besides.

Tumour noticed under one year; strongly attributed to a blow. Found to be a simple cyst, collapsing on issue of coffee-ground-like fluid contents.

Two small cauliflower-like intracystic protrusions, size of hazel-nut and large horse bean respectively. Latter examined microscopically; composed of dilated gland-clusters, lined with one layer of round cells and plugged in some instances with structureless gelatinous-looking material. Excised by Mr. J. P. Harris, in March, 1873. Patient alive and well October, 1880.

20. *Acinous adenoma of tip of nose.* (*Card specimen.*)

Exhibited by RUSHTON PARKER.

A MAN, aged 67, from a country place in Cheshire; healed in eight or ten days. Four years previously a little lump came on the tip of his nose, and shortly disappeared. A year later a similar growth appeared, and grew steadily till operation (three years). Subcutaneous and submucous, $\frac{3}{4}$ in. diameter, almost spherical, and in two lobes, almost equal. Fibrous stroma, highly charged with adventitious round small cells. Acini occupied by closely aggregated round cells in connected plugs, separated from stroma by a marginal space. Excised in Liverpool Royal Infirmary, June, 1880.

21. *Tubular adenoma of root and dorsum of tongue—submucous.* (*Card specimen.*)

Exhibited by RUSHTON PARKER.

GIRL, aged 16½, from Widnes, on the Mersey.

Growth the size of a walnut, projecting hemispherically, covered with stretched and injected mucous membrane; firm and slightly elastic. A portion remained, and had half the size of original tumour, in December, 1878. On 2nd April, 1881, it had dwindled to half that again, the patient being well and not inconvenienced.

Microscopic structure.—Glandular tubes lined with cubical epithe-

Digitized by Google

lium of uniform size. Tubes varying from thrice the diameter of the epithelium to several times wider; some containing a plug of gelatinous-looking material, others greatly distended with blood-corpuscles (due, no doubt, to laceration with vulsellum forceps the day before operation). Excised in Liverpool in June, 1877.

22. *Columnar epithelioma of antrum of upper jaw.* (*Card specimen.*)

Exhibited by RUSHTON PARKER.

JOHN U—, aged 19. St. Helen's, Lancashire.

In 1873 a right upper molar was extracted. Ever since the gum was swollen and ulcerated, and a perforation remained, admitting finger into antrum.

In 1876 antrum opened in front; mass of granulations scraped out, and packed with lint. It would not heal, so the whole jaw was excised in 1877.

In the antrum was a white, sarcomatous-looking mass, with a spherical nodule the size of a marble, almost free.

Under microscope, tubular epithelioma with columnar cells, distinctly shown, almost exactly like such growths found in rectum. A couple of years later he was well, and free from return of the disease. Excised by Mr. Harrison in the Liverpool Royal Infirmary, 1877.

23. *Round-celled acinous epithelioma, or adenoma of upper jaw* (*Card specimen.*)

Exhibited by RUSHTON PARKER.

THE case was that of a man, aged 54, a dock porter in Liverpool. Three years before, the right cheek and nose were severely bruised, ever since which there had been a gradual enlargement, both of the malar aspect and the outer nasal wall, with a fœtid discharge from the nose.

After removal, the growth was found occupying the antrum and projecting as an outer nasal wall, which was not otherwise recognisable. A separate mass was found at the outer margin of the nostril, and another covering the cheek surface of the bone.

Under the microscope were adenoid tubes lined with cubical epithelium. The greater part consisted of round cells aggregated as a single lining to spherical acini, but bearing a puzzling resemblance

Digitized by Google

to an infiltration of fat tissue, from which many of the acini could thus be hardly distinguished. Excised by W. M. Campbell, M.D., at Northern Hospital, Liverpool, October or November, 1878. See 'Brit. Med. Journal,' 28th February, 1880. Patient well up to a year later, when he died mysteriously (it was supposed by his neighbours of starvation).

24. *Odontoma of second lower left molar tooth.* (*Card specimen.*)

Exhibited by RUSHTON PARKER.

A YOUNG lady, aged 19, submitted in 1878 to the extraction of the tooth in question, which was broken off, leaving part of one fang. Later in the same year the extraction of the remainder was attempted, and the fragments of odontome removed. The rest of the growth, the size of a large hazel nut, was discovered embedded in the jaw, but causing no deformity either towards the cheek or the inside of the mouth. The patient refused anæstheties and extraction alike.

In 1880 the growth issued spontaneously.

One of the fragments was fastened by glue to the surface from which it had broken, and all but a small piece is now shown with the portion of tooth fang inseparably united to the centre of the tumour which springs from it, and occupies the place of the crusta petrosa. A drawing accompanies this account.

The odontome is hard, finely nodulated, the surface of the nodules being smooth. The colour is a darker yellow than the tooth, and a broken surface shows a radiate arrangement of closely aggregated stalactytic conical prisms, the bases of the cones being circumferential. From a patient of Mr. G. H. Snape, Liverpool.

25. *Congenital fibro-cystic (nævoid ?) tumour of the cheek.* (*Card specimen.*)

Exhibited by JONATHAN HUTCHINSON.

THE infant was aged 6 months.

There was a small nævus on the nose, and almost continuous with it a large tumour in the cheek, in part solid, but containing cysts.

The nævus was noticed at a week old, and had been cauterised before I saw the patient. The swelling in the cheek did not attract

Digitized by Google

attention till the child was three months old. It then increased rapidly.

The portrait was taken in order to show the remarkable appearance of bruising which these tumours often assume when inflamed. It had recently swelled and become discoloured, and, as expected, it subsequently subsided and shrivelled. The child died, however, with brain symptoms, before the cure was complete.

Oct. 19*th*, 1880.

26. *Congenital tumour at the extremity of the finger of an infant.* (*Card specimen.*)

Exhibited by JONATHAN HUTCHINSON.

THE growth consisted mainly of hypertrophied skin, which hung in flabby folds. It contained, however, a cyst, which was half filled with serous fluid, and which was divided into chambers by fibrous bands.

There were plates of cartilage in the walls of the cyst.

Oct. 19*th*, 1880.

27. *Congenital tumour on end of toe of an infant.* (*Card specimen.*)

Exhibited by JONATHAN HUTCHINSON.

THE infant was 6 months old when the sketch was taken. The tumour had been noticed soon after birth, and had continued to grow.

Amputation at last phalanx.

The tumour was solid, involved the skin, and consisted of fibroid tissue. *Oct.* 19*th*, 1880.

28. *Cartilage tumours in the bones of fingers and metacarpus.* (*Card specimen.*)

Exhibited by JONATHAN HUTCHINSON.

THE patient was a girl aged 10.

All the tumours were developed in the middle of the affected bones, expanding them until only a thin shell surrounded the growth.

They had been growing several years. They were removed by scraping them out of their beds; but some months later, on account of defective repair, it was necessary to amputate the ring finger. *Oct.* 19*th*, 1880.

Digitized by Google

29. *Sarcoma of clavicle.* (*Card specimen.*)

Exhibited by JONATHAN HUTCHINSON, for H. MACNAUGHTON JONES, M.D. (of Cork).

A WOMAN, aged 45, suffered, in Oct., 1879, from a tumour growing from the upper end of one tibia, which caused a fracture.

Other tumours formed on one parietal bone and on the sternal end of the left clavicle.

Subsequently tumours rapidly formed in connection with the bones of both forearms. Fracture in each followed, with subsequent union. The left clavicle was also fractured.

May 17th, 1881.

30. *Osteo-sarcoma of lower end of femur.* (*Card specimen.*)

Exhibited by JONATHAN HUTCHINSON, for H. MACNAUGHTON JONES, M.D. (of Cork).

THE specimen was removed, by amputation, from a young lady aged 24, in whom there was a history of four years' pain and one year's tumour.

Microscopic specimens exhibited, showing spindle-celled sarcoma with ossification in parts. *April 5th*, 1881.

31. *Cancer of the mamma, following eczema of the nipple.* (*Card specimen.*)

Exhibited by JONATHAN HUTCHINSON, for H. MACNAUGHTON JONES, M.D. (of Cork).

THE specimen (in spirit) is shown, and an oil sketch of the condition before operation. The patient, a married woman, had suffered from eczematous discharge around her right nipple for upwards of five years. During the last year another distinct tumour had developed in the axillary border of the breast. The axillary glands were enlarged.

Microscopic sections from the more recently developed tumour show it to be a soft form of scirrhus. *April 5th*, 1881.

Digitized by Google

32. *Fatty tumour from beneath scalp.* (*Card specimen.*)

Exhibited by SYDNEY JONES.

REMOVED from a child 20 months old. First noticed when two months old; then the size of a small marble; had increased rapidly some few months before removal.

It occupied the median line, over the sagittal suture, extending backwards to situation of posterior fontanelle. It gave a sensation of fluctuation; except around margin, where structure was more dense. Firm pressure did not seem to diminish it, nor cause inconvenience, but child's crying seemed to make it harder and tighter.

Removed on September 30th. It was adherent in places to the scalp, and was peeled off the pericranium, to which it was accurately moulded. The margin is very peculiarly convoluted. Weight, when removed, 2½ oz.

The specimen is in the Museum of St. Thomas's Hospital.

19th October, 1880.

33. *Fatty tumour removed from right arytæno-epiglottidean fold.* (*Card specimen.*)

Exhibited by SYDNEY JONES.

AN irregularly-lobulated mass of fat, held together by delicate connective tissue. In one part (indicated by a bristle) is a cyst, now laid open, it is about three quarters of an inch in diameter, and probably communicated with the surface; it is lined with stratified squamous epithelium, some detached pieces of which closely resemble hydatid membrane.

From a man aged about 40. It was attached to the right arytæno-epiglottidean fold, and hung down into the pharynx as a round, smooth tumour, of about two inches in diameter, covered by mucous membrane, with large veins. The patient could protrude this tumour into his mouth. An incision was made in the mucous membrane, and the mass forming the specimen at once turned out.

The specimen is in the Museum of St. Thomas's Hospital.

October 19th, 1880.

34. *Sarcoma of testis (recent).* (*Card specimen.*)

Exhibited by JOHN H. MORGAN.

THE specimen was removed this morning from a boy aged 3 years. The patient is a healthy-looking child, and comes of a family in which there is no history of phthisis or cancerous disease. His parents are alive, and there are five other children. This

Digitized by Google

tumour was noticed as a slight swelling five months ago, and it enlarged rapidly. He was brought to me two months after its first appearance, but the mother would not consent to an operation. A few days ago the swelling became suddenly large and painful.

There were no glands enlarged in the groin or in the abdomen. The cord was considerably thickened and the vessels greatly enlarged. *March 3rd*, 1881.

35. *Epithelioma arising in an ulcer of the leg.* (*Card specimen.*)

Exhibited by CHARTERS J. SYMONDS.

THE patient, J. B—, aged 62, was admitted into Guy's Hospital under Mr. Bryant. He had an ulcer of the leg for twenty years. Three years ago it had nearly healed. Six months ago the outgrowth commenced, associated with great pain and much bleeding.

The tibia is seen to have been completely absorbed beneath the centre of the ulcer. *May 3rd*, 1881.

36. *An epulis containing masses of hyaline cartilage* (*fibro-enchondroma*). (*Card specimen.*)

Exhibited by H. A. LEDIARD, M.D. (of Carlisle).

THE tumour, with four incisors, was excised from the alveolar process of the lower jaw of a woman, aged 49. It had been growing slowly and painlessly for a year.

On section of the growth it was found to consist of fibrous tissue, in which isolated masses of cartilage were embedded. It is on account of the rarity of the presence of cartilage in these growths that the case is deemed worthy of record.

December 21st, 1880.

Digitized by Google

VIII. DISEASES OF THE SKIN.

1. *Observations on the nature and affinities of molluscum contagiosum.*

By Alex. Morison, M.D., and Basil G. Morison, M.D.

In examining the subject of molluscum contagiosum, we have not had the advantage of being able to compare specimens from a large variety of cases of that disease, but those which we have examined show so clearly the characters of molluscum, as to leave no doubt of their being such. Our endeavour in this paper will be to describe as accurately as we can the essential structure of these bodies and to compare it with that of other skin growths, normal and abnormal, which are allied to them; also to throw, if possible, some light on their causation and on their not less obscure property of contagiousness.

It is not necessary now to do more than to glance at the different views advanced regarding the tissues involved in the production of molluscum contagiosum, that of most German pathologists, and of Drs. Thin, Sangster, and others in this country, that the disease consists in a downward growth of the rete mucosum at the skin surface, and that this process becomes modified and assumes the characters of molluscum, and that of Dr. Tilbury Fox and others, who hold that it consists of a hypertrophy of a sebaceous gland. These are matters of scientific history.

While we believe that the glandular theory is nearer the truth than that held on the Continent, it is, so far as we can judge, not absolutely correct, and there are points of structure which go to prove that the two views are not irreconcilable. If we look at normal skin, such as is shown under the microscope, we find numerous processes pushing downward from the deep layer of its

Digitized by Google

epithelium, and beside them hair follicles, which are epithelial processes wherein growth has developed hairs and sebaceous glands. The difference of opinion as to the place of origin of molluscum really has not reference to the tissue involved so much as to the stage of its development at which that tissue is involved. The molluscum involves processes of the rete mucosum, but not, we believe, till those processes have become hollowed out in the course of growth so as to give lodging to its causal element, whatever that may be. This will be fully gone into at a later stage. The minute structural changes which occur have been described by Prof. J. Renant,[1] who believes in the glandular origin of the growth, and states that the cells at its periphery, along with their periplastic surroundings, undergo hypertrophy, that this process goes on in the interior of the gland, and ends with the degeneration of the hypertrophied tissue and its extension on the skin surface.

The active cause of these changes, and also of the contagious properties associated with them, is said by a recent observer, Dr. Angelucci,[2] of Rome, to consist in the presence of micrococci in the interstitial material of the growth. This observation has not yet, we think, been confirmed by any other microscopist, though many have suggested its probability. Other observers have discredited entirely the contagious characters ascribed to molluscum, and their opinion receives a show of support from those cases in which a single nodule exists on the body, and not being in contact with any opposing skin surface, remains limited to the original spot. It is sufficient at present merely to indicate these various views.

The circumstances of the case from which our specimens of molluscum were obtained were the following:

The patient, a little girl, three years old, in the middle rank of life, and apparently well attended to, had been troubled since birth with a certain amount of diarrhœa, which, however, was not severe. No other clue than this could be found to the origin of the small tumours in question, which existed on the opposed surfaces of both buttocks, a little way from the anus. There were eight or ten small masses, mostly single, but one formed of several smaller masses combined. The single ones formed small, softish, rounded excrescences, slightly lobulated, covered with apparently normal skin, having a central dimple, in fact, showing all the usual cha-

[1] 'Journal de Dermatologie et Syphilographie,' sér. ii, No. 3.
[2] 'Centralblatt für die Medicinischen Wissenschaften,' 15th Jan., 1181.

Digitized by Google

racters of molluscum contagiosum. They were not pediculated. They were snipped off and examined more minutely. The following points were then noted :—1. A layer of epithelium formed their only covering. 2. A kidney-shaped and perfectly white body, tense, and marked as if with lobules, was attached to the deep epithelial surface by a narrow pedicle. A little loose connective tissue lashed the reniform body to the epithelial layer.

The whole body was epithelial, outside of the cutis vera, and appeared like a gland in its general characters.

In order to find out whether these bodies are glandular, as they seem to be, or what their nature is, we have examined a number of sections, both of them and of other structures formed by the skin epithelium, which seemed likely to throw light upon this subject. These other structures are :

1. The hair follicles and sebaceous glands of normal skin, and the normal skin surface generally.

2 The hair follicles and sebaceous glands of the external meatus of the ear.

3. Some sections of an ordinary wart from the scalp.

All these structures are purely epithelial, and are originally derived from the cells of the rete mucosum. These cells, unaltered, form the envelope or most peripheral layer of the hair follicles and sebaceous glands, and by their modifications give rise to their contents, and they form the growing root of the wart. We shall describe first the hair follicles and skin surface, and compare the molluscum with them afterwards.

The sections of normal skin were obtained from the outer part of the perineum near the anus of a man of about thirty. It was impossible to get them from a child's perineum, as would have been preferable. It is evident from these preparations of skin that the hair follicle and sebaceous gland adjoining it are one and the same structure, the latter being merely a blind diverticulum of the former, and both being formed by a dipping down and hollowing out of the process of rete mucosum.

Besides the follicles, there are seen distributed at regular intervals in the surface epithelium and dipping down into the cutis vera *crypts* of considerable size and walled by growing epithelium. Some of these are evidently the atrophic survivors of a former generation of hair follicles. Their position in the skin, their structure, their wide central cavity opening on the surface, and their

Digitized by Google

contents, which consist of old cuticular *débris*, with, in some cases, a small atrophic fragment of hair in the position of growth, all point to this conclusion. Others which resemble these, but in which we have found no hair, may be the same, or they may be interpapillary depressions of greater depth than usual ; we are not sure which, though we incline to the former view. The only other structures which they could be are adult hair follicles cut obliquely so as to show only the orifice, but in that case segments of divided follicles would be more numerous in the deeper parts of these sections than they are.

One other form of tissue change presents itself, namely, what are evidently young hair follicles. The rete mucosum between the crypts and mature follicles is seen to send down a number of narrow cellular processes. These appear to be normal, and in all likelihood represent, as has been said, the first stage of hair growth.

The usual degree of papillary waviness is seen at some points on the skin surface. It will be necessary before describing the characters of molluscum itself to consider the appearances seen in a section of the hair follicle and sebaceous glands of the external meatus of the ear. The condition here is one of hypertrophy.

The sebaceous gland tissue is massed at the sides and fundus of the hair sheath, and is greatly in excess as compared with the amount in the normal skin described above. The hair sheath is also much wider. The hair is present in some cases, in some it has fallen out. In these there is a marked resemblance in shape and general characters to molluscum contagiosum. The epithelial characters and relations of these structures, though altered in various ways, are unmistakably the same as we have already noted. The sebaceous glands being here the principal feature, it will be necessary to enter into their structure in some detail. Peripherally there are the cells evidently derived from the rete mucosum, rounded, single-nucleated, and traceable continuously from the fundus of the gland to the skin surface. Internal to these come a layer or two of large, irregular, squamous-looking, cells apparently the result of over growth of cells of the former series. They have delicate but well-defined walls; in the centre what appears to be one of the cells of the peripheral layer becomes granular, is superimposed in the place of the nucleus; sometimes there are two of these. The whole mass of the large cell is dimly translucent, but

Digitized by Google

here and there are seen rounded spots more translucent than the rest, resembling globules of sebum, and suggesting the description of the "mollusc bodies" which Dr. Tilbury Fox has given in his paper on molluscum contagiosum. In the central parts of the gland large spaces appear. From their characters it is plain that these represent a later stage in the history of the large translucent cells already mentioned; they are filled with rounded globules of sebum for the most part, but some contain a homogeneous and rather highly refractory material, which seems to have been formed by the coalescence of particles of sebum. Here and there, in interstices of the gland, glistening sebaceous globules are to be seen in a free state.

In the last place the arrangement of periplastic material in these specimens is noteworthy. It intervenes between the primary epithelial cells at the periphery of the gland, then forms the boundaries of the large cells internal to these, centrally again adjacent boundaries coalesce, thicken, and form tolerably thick septa between the spaces filled with sebum. At the very centre the septa break down and their contents are liberated. The epithelial and degenerated contents are well brought out by staining with picric acid, as is also the case with some of the periplastic material round the cells.

It is to be noted particularly that this whole description is that of epithelial hypertrophy followed by degeneration.

After the foregoing remarks we shall be better able to understand the details of structure which are found in—

Molluscum contagiosum itself. In regard to our specimens of this disease we repeat the statement made before, that only epithelial tissue is concerned in it; a strip of this tissue in its young state, varying in breadth at different points, derived from the rete mucosum adjoining that layer above, can be traced downwards all round the molluscum tumour, the whole internal formation of which arises from modifications in the development of the cells in that strip. The changes will be best understood if we take up first, as in describing the sebaceous gland of the ear, the cellular elements of the molluscum, and then consider the periplastic material which encloses them.

Beginning as before at the periphery, the zone of earliest change, we see the cells to be essentially the same as those of the rete mucosum at the skin surface, but with this peculiarity, that a large

Digitized by Google

number of them appear to have vacuolated in the whole area of their protoplasm, the rod-like nucleus lying in the middle or to one side. This apparent vacuolation we hope to prove does not really indicate a disappearance or emptying out of the protoplasm, but a transformation of it into a pellucid material. These pellucid cells we take to be the "mollusc bodies" of Dr. T. Fox.

The rest of the peripheral cells resemble the normal cells of the rete mucosum.

It is noticeable that those cells which have apparently vacuolated have at the same time become rounder in shape and slightly larger than those in which the change has not occurred. Rather more centrally the pellucid cells have increased in size to two or three times their original dimensions, or even larger; some have become granular, and in some on careful focussing, the area is seen to be occupied by small rounded bodies, which recall the mode of formation of sebum in the sebaceous gland. These bodies are, we believe, homologous with sebum globules. In some of these cells a rod-like nucleus is distinguishable, in some two.

In the centre of the molluscum, bordering on the free cavity which exists there, are irregular spaces, each, it would appear, the ultimate phase of development of one of those cells whose progressive distension we have studied, but exceeding any of them in the extent of that distension. These spaces are distinctly walled, contain a transparent homogeneous material only apparent after staining with picric acid, and contain no nucleus which we have been able to discover. They resemble cuticular cells, as said by Dr. Fox.

The arrangement of the periplast in these specimens is not their least interesting feature. Its distribution corresponds in all particulars to that of the hypertrophic sebaceous gland of the ear meatus, but can be even more precisely studied than in that organ. Peripherally it forms a delicate reticular casing for the cells; as these become distended and approximated to one another the periplastic material thickens, and forms a series of very well-defined loops, which are arranged round about the cells and separate one from the other. These loops have a fibrous appearance. More internally the same periplastic matter forms septa of even greater thickness and fibrous looking, which enclose the spaces above mentioned, but ultimately break down on the edge of the central cavity and liberate their contents. These septa are stained yellow by

Digitized by Google

picric acid. The loops and septa show but little tendency to coalesce by fusion.

The appearances we find, therefore, in molluscum contagiosum are those of epithelial overgrowth, followed by degeneration of elements into sebaceous matter, the globular character of which is preserved in some parts, while in others (the central spaces) it appears as if the globules had run together to form a homogeneous mass which dries and resembles a cuticular scale. That the change is a purely hypertrophic one we consider to be proved, not only by the structure of the molluscum itself, but by the close correspondence between the appearances in it and in the specimen of glandular hypertrophy from the meatus of the ear, by the absence of malignant characters, and, so far as we have seen, of any germ or fungus which would distinguish it as a septic growth. Moreover the appearance of vacuolation is characteristic of epithelial cells actively growing. It is seen in the roots of hairs, in the growing rete mucosum, in warts in a very marked degree, and it is mainly to show this that we have exhibited a specimen of wart structure from the scalp; it is also seen in the epithelium of malignant tumours. We have stated our opinion that these "vacuolated" cells are not really void of their contents. We have done so because, on careful focussing, an appearance as of translucent contents is distinguishable, because in some parts where a cavity seemed to exist a closer view shows a material stained with picric acid, and because the large central spaces which are brightly stained by this means appear perfectly transparent unless so treated. Besides, it is difficult to conceive how an empty cell wall should go on distending as if swollen by its contents.

We have not yet referred to the horizontal rete mucosum. It is evident from the specimens shown that this is hypertrophied as compared with that of the normal skin. It is hypertrophied uniformly, and to a less extent than the epithelium, resembling it at the cortical zone of the molluscum. It is noteworthy that we do not observe transitional stages between the general horizontal thickening at the skin surface on the one hand, and the complete molluscum on the other. We should expect these in the shape of mollusca of various sizes in the sections cut, if the growths in question began by developing as buds from the horizontal rete mucosum.

These facts lead us to think that the epithelial thickening at the

Digitized by Google

skin surface and at the molluscum respectively are parts of a common process, depending on a common cause of irritation, but that the one is not the result of the other. Also that the point most severely and primarily irritated is that where the molluscum grows. Whether any body or what body existed previously at this point we shall now consider.

It is necessary now to show, if possible, in what segment or in what development of the surface epithelium it is that molluscum arises. Reasons have been given for believing that it does not arise from the horizontal rete mucosum, like an ordinary wart, but that at all stages it appears to be completely subjacent to this layer. Turning to the appearances seen in normal skin, we find depressions of epithelial tissue in it at regular intervals in the interpapillary areas, namely, the hair follicles, with their diverticula the sebaceous glands, and those deep crypt-like hollows which have been mentioned, and some of which contain atrophic hairs. Now either of these, we believe, can, in certain circumstances, form a molluscum contagiosum. With regard to the hair follicles, it seems much more likely that they are altered in their entirety to form it than that the sebaceous glands alone are. The glands in question are small lateral diverticula of the hair follicles and come off nearly at right angles to them. Foreign bodies, such as probably give rise to molluscum, are even more likely to find a lodgment in the follicles themselves than in the glands. The absence of hair, too, as a part of the growth (in our case at least), is what would naturally occur if its roots were loosened by a general degeneration following hypertrophy of the surrounding epithelium. Again, the uniformly rounded shape of molluscum points rather to the overgrowth of a whole follicle than to that of its little granular diverticulum.

While, therefore, it is not impossible that accident may sometimes lead to the gland alone being affected, we think that usually the whole follicle is so. The specimens of sebaceous gland hypertrophy from the ear meatus, which most resembles molluscum, are the ones in which the hair has dropped out of its sheath, and this is enlarged along with its adjacent gland. With reference to the crypt-like depressions already mentioned, we believe that these are even more liable to molluscous growth than the majority of hair follicles, from their much greater patency.

Although it would appear, therefore, that molluscum contagiosum is not limited to the sebaceous glands alone, it is nevertheless true

Digitized by Google

that the changes which occur in its cells in the course of growth resemble those which take place in cells designed to form sebum. This is not remarkable when we remember that the essential change in both cases is a rapid cell proliferation into a more or less closed cavity. The degeneration which follows in both cases is a natural consequence of this. It is probable that if a sebaceous gland were everted and exposed to the air, we should find it forming cuticle instead of sebum. What is to be noted in these various changes is their common character of cellular hypertrophy, the consequences are the result of varying circumstances. This is our view of the rationale of molluscum and its affinities, a view which tends, as we have said, to reconcile apparently opposite theories regarding it.

The cause of the growth and contagious properties of molluscum contagiosum has long been a matter of speculation.

Dr. T. Fox's theory may be correct, viz. that the "molluse bodies" are concerned in its propagation, these bodies being, according to him, epithelial cells containing altered sebum.

Dr. Angelucci's observations have been mentioned on a previous page. We have seen a good deal of granular material such as he describes, not merely in the interstitial but also in the cellular structure of molluscum. To us, this appears to be the result of degeneration rather than an accumulation of micrococci. It is found between the central and peripheral zones of the growth where degenerative change is well marked, and is particularly evident in a specimen of the tumour of very advanced development.

If, however, molluscum contagiosum is to be regarded as an overgrowth of epithelium progressing to degeneration, and we cannot form any other judgment regarding it, it appears hardly reasonable that some one special infective element should be necessary for its production, and that no other foreign body should have the same power. We think rather that any body possessed of considerable irritative properties, whether vital, chemical, or even mechanical in its nature, is capable of giving rise to the growth which will propagate itself by transference of its contents to suitable points, such as we have indicated, on any skin with which it is in contact. The fact that sebaceous or other animal impurity seems to be able to bring about the disease, its occurrence in dirty people, its occasional occurrence in a diffuse form, and the peculiarities of normal skin which have been mentioned as provid-

Digitized by Google

ing so many receptacles for foreign matter, all alike tend to confirm the view that irritation is the cause of the disease.

We have come to the conclusion, therefore, that molluscum contagiosum is an hypertrophy of previously existing depressions or involutions of the rete mucosum, whether these are blind interpapillary crypts, exaggerations of the normal depressions, or old hair follicles, or hair follicles in a normal condition, together with their sebaceous glandular appendages accompanied, as in our case by an uniform hypertrophy of the uninvoluted or superficial Malpighian layer, or not so accompanied. We do not adhere to the views of Lukomsky and his followers, believing that an hypertrophy proceeding on the principles laid down by them would result in a superficial wart or verruca, and not in the more deeply-seated, though also warty, condition of molluscum contagiosum.

May 3rd, 1881.

---

2. *The histology and pathology of molluscum contagiosum.*

By H. Radcliffe Crocker, M.D.

As so much has been recently written with regard to the views of different authorities as to the question whether molluscum contagiosum commences in the sebaceous glands or in the epidermis, I will only state the observations and deductions from them which appear to me to support the theory of the origin of the process in the epidermis.

Two tumours were removed from the skin of an infant, one only just perceptible above the skin, the other about the size of a pin's head. Vertical sections of the smaller tumour, stained with picrocarmine, presented the following appearances:—There was no defined tumour, but only changes in the epidermis; most of the corneous layer over the affected part was shed, but some was left, in which translucent colourless cells were embedded; the cells were not numerous, and were larger than healthy rete cells; the stratum lucidum was normal with the exception of one or two large cells in it; immediately below this layer numerous much enlarged cells, which did not stain so readily as the rest, were aggregated; the uppermost pre-

Digitized by Google

sented in the most marked degree the so-called molluscous change; they were three or four times larger than the normal cells of the rete, and the most changed were homogeneous in aspect; a little lower the molluscous change did not occupy the whole of the cell, and going deeper down the change became less marked in the individual cells, consisting only in some of an abnormal translucence in some part of the cell, usually in the periphery; few cells were affected in the deep parts of the rete; in short, in the granular and upper layers of the rete lay all the most changed cells, and between, not over, the papillæ, the rete was thicker as a whole in the affected part, though there was not the marked protrusion downwards into the corium that is seen in a more advanced stage, but the papillæ were narrowed and elongated.

In some parts, in the corneous and subjacent cells, minute circular granules were seen, which may perhaps be the micrococcus described by Angelucci:—A few portions of very small sebaceous glands were seen, but none were abnormal. It was different, however, as regards the hair follicles; both in transverse and vertical sections of the follicles, many showed the same mollusc bodies in them, most marked here also near the central hair shaft, but never immediately adjacent to it, and the change could be traced, varying in degree up to and including the palisade cells of the periphery of the follicle; those affected hair follicles were usually close to the epidermis most involved, but no direct connection with the tumours was traced. The larger tumour showed the process more advanced. The tumour was well defined, projected a little upwards above the level of the skin, but the greater proportion dipped into the corium. Sections made through the centre of the tumour showed the absence of a corneous layer over the centre of the tumour, and in this centre was a hemispherical mass of large cells pressed together and staining deeply with picric acid; below this there were the typical mollusc bodies in layers, stained but little or not at all, and deeper, the change became less marked in the cells, until healthy rete cells were reached, which formed a layer two or three cells deep over the palisade cells, these being continuous with the healthy adjacent rete cells of the normal skin. The tumour consisted of lobes separated by thin fibrous septa, and viewed in relation to the smaller tumour the lobes evidently consisted of the interpapillary processes of the rete deepened and widened by the centre being more filled with mollusc bodies, while the papillæ

Digitized by Google

were compressed into the fibrous septa alluded to. The sebaceous glands, as might be expected of an infant under twelve months old, were small in proportion to what they become at and after puberty, and not many were seen, but nothing abnormal was detected in any of them. The above facts appear to me to warrant the following deductions:—1. That while we have no evidence of the origin of the tumours in the sebaceous glands, we have distinct evidence of the commencement of the process both in hair follicles and in the epidermis. 2. That the slower growth and expansion of the interpapillary processes of the rete and the consequent compression and elongation of the papillæ between them, account for the appearance of lobes with intervening fibrous septa in the larger tumours, which is so strongly suggestive of gland structure. 3. That the vertical sections through the centre of the tumour show the deepest part of the tumour continuous with the normal rete. 4. That the throwing off of the plug of cells which stain deeply with picric acid will produce the central hole which is such a noticeable clinical feature of the tumour. 5. That although the diseased process is most advanced in the cells lying in the granular layer and the upper adjacent layers of the rete, it does not prove that the process commences there, and works its way downwards, but it may be, and I am inclined to regard it as more probable, that the process begins in the cells of the more physiologically active deeper layers of the rete, and as they are gradually extruded the molluscous change advances until the whole cell is enlarged and presents the homogeneous aspect of the mollusc bodies; they accumulate close to the surface, and become compressed into the mass alluded to, which stains deeply with the picric acid; the cells multiplying below, owing to the resistance to upward growth offered by this plug, produce further down growth of the rete into the corium. What is the agent that starts the process? Dr. Angelucci states that he has found micrococci in the affected parts, and infers that they are the morbific and contagious agents; if they should prove to be so, they would explain satisfactorily many points which have hitherto been inexplicable.

Certainly I have seen minute round bodies in the horny layers and in the cells of the superficial layers of the rete mucosum, and at the mouths of some hair follicles; whether the process is excited by these organisms working their way into the hair follicles, and the change then extending to the adjoining rete, there is no definite

Digitized by Google

evidence to prove. I am, however, inclined to think that it may arise either through extension from a hair follicle, or independently in the rete, but further investigation is needed to prove these points. *Jan. 4th*, 1881.

---

3. *On the histology of the molluscum contagiosum of Bateman.*

By George Thin, M.D.

The author presented to the Society the results of an examination of a number of molluscum contagiosum tumours, excised from different parts of the trunk of a young adult man, by Mr. Hutchinson. The size of the tumours examined varied from that of a pin-head to that of a small pea.

Only one unmistakable hair follicle was found in all the sections, although every tumour was thoroughly examined.

A tumour begins by a group of small isolated abnormal growths in the horny layer of the epidermis, which coalesce on the surface. The downward expansions of the resulting tumour, which encroach on the connective tissue, enlarge laterally: hence a tendency to coalesce by obliterating the dividing septa of connective tissue.

There are chemical and physical differences between the central and peripheral cells of the molluscum growth. The intermediate cells contain granules.

There are no ducts in the growth, and the cells do not contain sebum. A cavity is sometimes formed by the central cells breaking down, the appearance thus produced possibly having suggested to some observers the idea that the structure is glandular and that it contains a duct.

Several sections through the smallest tumours examined, presented appearances that render it highly probable that the specific change begins in the hair follicle, and in one section this was seen to be the case.

In this section the centre of the tumour was formed by a widened hair follicle, from which the hair had disappeared. A number of

Digitized by Google

molluscum cells were found in the cavity, and at the deeper part of it they were in intimate connection with the inner root sheath of the hair.

The identity of the follicle was shown by the hair sheaths being still recognisable, and by the remains of a shrunken sebaceous gland.

If the molluscum cells possess contagious qualities the origin of the small separate centres of new growth which are found around the follicle, and which by subsequent coalescence form the tumour, is accounted for.

The result of the examination is thus confirmatory of the opinion of Virchow, who stated in 1865, that these tumours are epidermic in their nature, and that they take their origin in the hair follicles. The author found no appearance which can justify the belief that the sebaceous glands take any part in the new growth.

The epidermic cells which undergo the molluscum change first become filled with granules, the nucleus remaining entire and being generally close to the cell-wall. In the granular substance clear spaces—so-called vacuoles—are seen. The granules become larger and coalesce, and the nucleus loses its spherical form and becomes lost. By the coalescence of the granules, a new substance which is the so-called "molluscum body" is formed. The cell-wall retains its epidermic character.

The cells in which the early molluscum changes are found are "prickle" cells. *January 4th*, 1881.

---

4. *A case of abnormal pigmentation of the skin following jaundice.*

By JOHN CAVAFY, M.D.

THE patient is a man, aged 29, with a good family history. He was never ill until eight years ago, when he had shivering and slight cough after exposure to cold, soon followed by jaundice. This was not severe enough to confine him to bed, but the bright yellow colour of the skin, after lasting about two months, gradually

Digitized by Google

changed into a much darker brown tint, the conjunctivæ at the same time resuming their natural aspect. The discoloration was universal, including the face, hands, and feet, but was darkest over the lower part of the abdomen and upper part of the thighs; it was accompanied by intense itching (which still persists in a milder degree), but there was no desquamation. Occasionally wheals made their appearance preceded by stinging sensations, and he was told in Germany (of which country he is a native) that he had urticaria.

The dark colour remained unchanged for about nine months, and then began gradually to fade from the face, chest, upper and lower extremities, becoming at the same time a little lighter over the rest of the body. Soon afterwards (seven years ago) patches of light skin made their appearance on the abdomen, buttocks, thighs, neck, arms and legs, beginning as discs, from a quarter to half an inch in diameter, and gradually spreading and becoming confluent so as to form oval and irregular gyrate figures. Fresh light patches have appeared, and the older ones have enlarged during the seven years for which the affection has lasted.

Four years ago the patient had a chancre three weeks after connection, followed by headache, sore throat, and a general erythematous and papular rash. He married a year and a half ago, and his wife aborted at three months. She has had no skin eruption.

Present state.—The patient is well nourished, with light brown hair and grey eyes. The face is slightly dusky, this tint stopping short on the front of the neck, with an irregular map-like border. There is no recognisable discoloration on the chest, but the skin gradually becomes darker over the abdomen, without any abrupt line of demarcation, and is of a rich liver colour over the hypogastric, inguinal, and iliac regions. The same rich tint exists over the loins, buttocks, and back, being lighter in the upper dorsal and nuchal regions. The pigmentation is everywhere occupied with circular, oval, and gyrate patches of light skin, which are largest over the lower abdomen, hips, buttocks, and loins. The larger light patches are studded with a few irregularly scattered pigmented islets, from a sixth to a quarter of an inch in diameter. The upper and inner part of the thighs is richly pigmented, and the genitals very dark, with a light island on the upper surface of the penis. The rich tint gradually shades off into a light dull grey over the remainder of the lower extremities, chiefly recognisable by

Digitized by Google

the contrast it presents with the rounded patches of light skin which are also present in this locality. A similar barely perceptible pigmentation with interspersed light islets occurs over the arms and forearms, the hands and feet being unaffected.

The light patches are always bounded by convex borders, but are nowhere surrounded by rings of intenser pigmentation. During the month for which the patient has been under observation, fresh islets of light skin have appeared over the front of the abdomen. Itching has been constant, and on several occasions bright red or pale grey wheals of urticaria have been noticed on the trunk.

The pigmentation in this case obviously had its starting-point in the jaundice with which the patient was affected eight years ago, and is probably in part due to some chemical change in the bile-pigment which was at that time deposited in the skin; but that the nervous system has been chiefly instrumental in the production and maintenance of the affection is suggested by the constant itching and urticaria which have characterised the case throughout, and which are sufficient evidence of continual irritation of the terminal filaments of the cutaneous nerves. *February 1st*, 1881.

Report of the Committee on Dr. Cavafy's case of abnormal pigmentation of the skin.

We have examined Dr. Cavafy's patient, and have come to the conclusion that the disease of which he is the subject is one, essentially, of leucoderma. At the same time the following points of difference between this case and the more ordinary examples of leucoderma may be enumerated:

1. The fact of the symptoms of leucoderma having followed an attack of jaundice.

2. The well-marked pigmentation which preceded the leucodermic appearance by many months. It is possible that this was partly confounded with the icteric discoloration, or that it was produced by itching.

3. The intense itching throughout, which was accompanied by symptoms of factitious urticaria.

4. The asserted gradual fading of the pigmentation from the thorax and from the hands and feet.

JONATHAN HUTCHINSON.
P. H. PYE-SMITH.
W. MORRANT BAKER.

July 21st, 1881.

Digitized by Google

5. *Circumscribed Scleroderma affecting the face and scalp.*

By W. Morrant Baker.

[With Plate XXXI.]

The patient shown to the Society is a woman (Elizabeth N—), aged 45, who has suffered from disease of the skin of the face and scalp for nearly five years.

(For the details from which the following note has been abstracted I am indebted to Dr. Herbert Stowers.)

Extending from the right inner canthus, downwards and outwards over the malar bone, is a dense tough deposit or new growth, somewhat raised above the surface, conveying the impression to the finger of Scleroderma, but not differing much in colour from the surrounding skin. It measures about an inch and a half at its widest part, but tapers off at the upper and lower ends. Below this patch and extending towards the chin are several raised, pinkish, hard nodules with similar characters, and varying in size from that of a small shot to a large pea. Another hard flat lump, irregularly circular in outline and measuring about an inch in diameter, is situate in the submaxillary region immediately under the chin and has characters similar to those of the tubercles on the face. Below the septum nasi there is also some thickening of the upper lip.

On the left side of the face the disease is present only on the side of the nose and, to a slight extent, on the adjacent portion of the cheek.

The face is, in various parts, but especially the cheek and nose, much scarred, as if from past ulceration, but the patient thinks this is not due to the disease, but to the effect of caustics which were applied before she came to the hospital.

The base of the nose is thickened and appears unnaturally broad, on account of the small tubercles which encroach upon it from the cheek, while the tip and bridge look somewhat distorted and, like the cheeks, present several small irregular scars, some of which form little pits of considerable depth.

Behind the left ear, immediately above the mastoid process, is a smooth hairless patch of tightly drawn, glazed, and thickened skin,

Digitized by Google

of a yellowish tint, mottled with red, and measuring about an inch and a half in diameter.

On the scalp, near the posterior end of the interparietal suture and extending more to the left than the right of the middle line, is another hairless patch the general characters of which resemble those of the patch behind the ear. It is irregularly circular and about two inches in diameter. Quite recently it has, in the centre, become the seat of ulceration.

The disease began nearly five years ago and gradually extended up to two years ago. Since this date it has not undergone much alteration. The patient has suffered much from shooting pain and itching in the affected parts. The sensibility of the diseased skin is normal.

The patient is married and has been pregnant twenty-one times, having borne thirteen children and miscarried eight times. The children have been healthy; nine are still living. The miscarriages have not occurred in such an order as to suggest any connection with syphilis. The patient is in good general health and has never suffered from any serious illness.

The case seems to me a remarkable one in many respects and, although I have ventured to call it one of Scleroderma, does not correspond, in all its features, with that disease. Allowing, however, that there are difficulties in the way of classifying the disease with Scleroderma, the difficulties appear greater still when one makes an attempt to place it in any other connection.

It has been suggested to me that it is possibly syphilitic, but I think its own physical characters and their persistency render this unlikely; and the fact that iodide of potassium in large doses and mercury having been given for many weeks without the smallest apparent benefit may be mentioned in confirmation of this opinion. *February 1st*, 1881.

Report of the Committee appointed to examine Mr. Morrant Baker's case of scleroderma of the face and scalp.

History.—The only point of importance in the antecedents of the patient is her statement that twenty years ago she had "the (venereal) disease from her husband." Her account of a sore throat, of an eruption "which made her eyes swell up," and of the subsequent birth of a child which had inflamed eyes and died at six months old, does not identify the disease as syphilis. She has

Digitized by Google

Digitized by Google

Digitized by Google

West Newman & Co. chr. lith

UNIV OF

DESCRIPTION OF PLATE XXXI.

This plate represents Mr. Morrant Baker's Case of Localised Scleroderma of the face.

Digitized by Google

Digitized by Google

since had miscarriages and borne living children, in no relation to the supposed period of infection. There is now no sign of previous syphilis to be found in tongue, throat, iris, bones, or skin.

The patient's account of the present disease is that it began simultaneously in separate spots on her nose and cheeks, about five years ago, soon after a confinement. There was much discharge from the nostrils at the time. She saw a house surgeon at St. Bartholomew's Hospital, who called the disease lupus. The same diagnosis appears to have been made at another hospital where caustics were freely applied. She thinks that this caused spreading at the edges of the spots and produced the scars now seen.

The upper lip and septum nasi were involved about a year ago, *after* the present lesions appeared on the chin and behind the ear, and she is sure that several small patches on the scalp have only lately been developed.

Present condition.—Under the chin is a round, flat, smooth induration, infiltrating the skin, slightly raised, and movable on the subcutaneous tissues, of a rose tint, and firm to the touch.

The right cheek is almost entirely occupied by a patch which is apparently older, though this appearance may possibly be the result of treatment. The edges are rose coloured, raised, and nodular; the centre is depressed, soft, movable, and, excepting some superficial cicatrices, is in a nearly normal condition.

Two of the circumferential nodules (which are about the size of peas) extend towards the patch on the chin, but do not join it. Where the affected surface reaches the neighbourhood of the right eye, the skin is œdematous. A deep fold runs up to the inner canthus, from which a scanty gummy secretion exudes. Elsewhere the affected surface is perfectly dry.

The whole of the nose, the glabella, and a small portion of the left cheek and upper lip, are occupied by a similar smooth, firm, pale-rose induration, slightly elevated at the margins. Here it is nodular, the nodules being larger than those of ordinary lupus. On the nose the tint is decidedly paler, the skin is more adherent to the underlying tissues, and there are numerous small depressed scars. Some of these are minute pits corresponding to obsolete sebaceous glands, the rest are the result of superficial destruction of skin, and were probably produced by caustics. The margin of the septum nasi and the adjacent part of the upper lip are occupied

Digitized by Google

by the same induration, but it is here less hard than in the patch under the chin. There is no ulceration.

Behind the left ear is a smooth, shining, slightly congested patch of skin, marked with very superficial scars, without marginal nodules, and not raised above the surrounding surface.

The hair is absent on four or five spots upon the scalp, from a quarter to half or three quarters of an inch in diameter, and in the larger ones the hair sacs are destroyed. The skin is not adherent, there are no scars or nodules, but at the edges it is felt to be slightly raised. Another patch, on the vertex, is nearly two inches in diameter, and is firmly adherent to the pericranium. It presents a decidedly scarred surface, in the middle of which is a dry, yellow, moderately thick crust. On removing this scab, we found an oval, sharp-edged, ulcerated cavity, large enough to contain a pea, and reaching through the entire skin to the pericranium. The bone was not exposed. The hair elsewhere is healthy in growth, and the skin of the scalp is normal. The eyebrows and eyelashes are unaffected. The cervical lymph glands are not enlarged.

There is no pain except in this single ulcer, but the patient complains of itching, especially of the right eye, the lids of which are œdematous.

Remarks.—The disease is a very chronic inflammation involving the entire thickness of the skin, infiltrating and hardening it, spreading slowly at the edges, and apparently not ulcerating; for the scars present are probably chiefly due to the use of caustics, and the patch under the chin has lasted, certainly for above a year, without any sign of ulceration. There are no secondary deposits in lymph glands or elsewhere, and the general health of the patient is unaffected.

We find great difficulty in bringing this affection under any described cutaneous disease. It has resemblances to syphilis, to lupus, and to the disease named by Hebra rhinoscleroma. The likeness of some parts to cheloid (of Alibert) is only apparent.

There is no conclusive evidence that the patient has ever had syphilis, and (apart from this disease of the skin) none that she has it at present. Moreover, the colour, the uniformity, and the absence of destructive action would be unusual in even the most chronic and most localised forms of tertiary syphilis. With a view if possible to determine this point, we requested Mr. Baker to try

Digitized by Google

the effect of antisyphilitic remedies. This he has done with completely negative results.[1]

The patch behind the ear resembles erythematous lupus, and some parts of the face are like ordinary lupus during partial involution. But behind the ear there is no evidence of the sebaceous glands being involved, and the scars which have been produced by caustics make the chief part of the resemblance to ordinary lupus. The patch under the chin is quite unlike any form of lupus with which we are acquainted. The local distribution and the mode of spreading by numerous isolated patches are also unlike lupus exedens or lupus erythematosus.

The late Professor Hebra and Dr. Kaposi described thirteen cases of an affection of the nose and upper lip, which they called rhinoscleroma. One of us has seen what he believes to be this disease. The firm induration of the septum nasi and adjoining part of the lip in Mr. Baker's case have a certain resemblance to the description and figures given in Hebra's 'Hautkrankheiten,' and in his 'Atlas.' The following is the description:—Rhinoscleroma presents itself in the form of flat or slightly raised limited nodules of unusual hardness. They are smooth and shining, either red or of natural colour, and show fissures which secrete a small quantity of viscid fluid. The skin is not movable over the nodules, which appear to be let into the substance of the skin. There is no pain except when the part is pressed.

All the thirteen cases observed by Hebra and Kaposi affected the septum nasi, the adjacent alæ and upper lip, and occasionally the mucous membrane of the nares or the hard palate. The disease was exceedingly chronic and (notwithstanding the woodcut and the coloured figure in the 'Atlas') did not ulcerate. Microscopical examination of a nodule showed it to consist of a cellular infiltration, bringing it under the category of a granulation growth.

Hebra enters upon the diagnosis of this new form of disease from tertiary syphilis, from cheloid (of Alibert), and from the early

[1] The following was the treatment employed:—From Sept. 17th to Dec. 10th, 1880, Pot. Iodid., gr. x; Liq. Hydrarg. Perchlor., fl. ʒj ex Aqua, t. d. s. From Dec. 10th 1880, to Jan. 7th, 1881, the same mixture was continued, with an additional ten-grain dose of Potassic Iodide. No benefit ensuing, arsenic, quinine, and iron were next exhibited. Mr. Baker having kindly at our request resumed the specific treatment, Hydr. Iodid. Virid., gr. ½; Pulv. Opii, gr. ½, every night, was taken from Feb. 25th to April 22nd, and again from June 10th to June 28th, 1881.

Digitized by Google

stage of epithelial cancer. He says nothing of its resemblance to lupus or to scleroderma, but the histological diagnosis given, and its position in the treatise immediately before the chapter on lupus, show that he regarded it as closely allied to that disease.

We have little doubt that Mr. Baker's case would have been recognised as rhinoscleroma by Hebra. We cannot agree to regard the present case as syphilitic, and we do not find that it coincides with the description of scleroderma or morphœa by Thirial, Addison, Fagge, and Hebra. The most localised forms of scleroderma are not raised, the skin is not injected, the edges are not nodular, and the patches do not occur on widely separated regions.

On the whole, we are disposed to regard Mr. Morrant Baker's remarkable case as showing only an external resemblance to (or mimicry of) morphœa, but as pathologically belonging to the lupus group, some of the patches being more like common ulcerative lupus, and others like lupus erythematosus. It resembles Hebra's rhinoscleroma, which we regard as a form of lupus, more closely than any other described form of disease. It might perhaps be provisionally termed lupus sclerosus, which would include Hebra's rhinoscleroma, as descriptive of a local variety. Its most striking characters would be the hardness and smoothness of the patches and the absence of ulceration. Its alliance with ordinary lupus would depend on its chronic course, its inflammatory characters, its nodular edge, its local distribution, and lastly (assuming its identity with Hebra's cases), its histological features.

JONATHAN HUTCHINSON.
P. H. PYE-SMITH.
JOHN CAVAFY.

July, 1881.

---

6. *Case of Scleroderma.*

By JOHN ABERCROMBIE, M.D.

THE patient whom I have brought here this evening is aged 8 years 10 months.

Her mother gives the following history:

Digitized by Google

About ten months ago she complained that her right great toe felt funny, then it got stiff. Since then the skin of this toe has gradually become shiny and hard, and the toe has got smaller; the affection has gradually spread to the second and third toes, and the skin of the foot and leg has gradually got harder. The limb has wasted. These changes have been more obvious during the past three months, but especially for the last fortnight.

When the leg is warm there is much irritation of the sole of the foot and between the toes; as a rule the foot is cold. No pain in limb. General health good.

She is the seventh child, and has always had good health. There are six other children healthy. The mother has had five miscarriages, all before the third child.

Mother healthy, her father and one brother died of phthisis, and a sister died insane.

Father suffers from dyspepsia; his mother died of apoplexy.

Present state.—She is a fairly nourished intelligent child. On the front of the right thigh, from about the middle to just above the patella, there is a band of altered skin about an inch broad, the skin being white and shiny, but not adherent to the subjacent tissues.

All down the front of the leg the skin is smooth, tense, and firmly adherent to the subjacent tissues; this condition passes down on to the foot, gains its inner side, and spreads to involve the inner half of the sole, the whole of the great toe, except the flexor aspect of the terminal phalanx, the whole of the second toe and the inner half of the next toe. This foot and leg are much smaller than the other one, and the skin cannot be pinched up over the affected area. There is slight desquamation on the sole of the foot. On the right side of the abdomen there is a diffused broad patch extending towards abdomen, the skin being white and glistening, and slightly rough; it is not adherent to the subjacent tissues; on the left side, extending from the umbilicus to the hypochondrium, there is a crescentic band of similarly affected skin.

In other respects the child seems perfectly healthy.

February 1st, 1881.

Digitized by Google

7. *A case of leucoderma.*

By JAMES STARTIN.

THIS was a case in which a labourer, C. W—, aged 31, was affected with well-marked patches of the disease showing itself on the skin and hair of the arms, at the junction of forearm and arm, both sides of the chin, and the hair of the beard, on both hips, on the outer surfaces of both legs, and on both popliteal spaces, giving the patches quite a symmetrical character. There was no loss of sensation in the patches, which had the appearance of bleached skin, and the surrounding skin and hair were quite of their natural colour. The patient stated that about eight weeks ago, then about February, that he was sent home from Canada by the medical men, as not being able to stand the climate, and he stated that he could not bear the intense cold. The disease had gradually increased directly after his arrival in England. He has no irritation or numbness of the skin in connection with the disease.

The patches are well defined, as is shown in the accompanying drawing.

The cause of the disease seems to me to be solely due to deficiency of pigment matter in the skin, due to depressed innervation, induced by intense cold or heat. The disease is frequently seen in Northern India. *March 3rd*, 1881.

---

8. *Case of congenital Ichthyosis.*

By JAMES STARTIN.

THIS rare case of local congenital ichthyosis, or more properly called Xeroderma, occurred in a child 10 years old, E. S—, coming from Norfolk, the father being a labourer. No specific history could be obtained. The disease shows itself as dense yellowish-brown plates of epidermis on the plantar surface of the feet and on the palmar surface of the hands only, with well-defined margins; the skin looks harsh, dry, of a dirty yellow, wrinkled and

Digitized by Google

very stiff, with little or no fat in its substance. The child had had it since she was four or five months old.

The principal features in the case are free formation of dense

WOODCUTS 5 AND 6.

yellowish epithelial scales, mingled with a little fatty and sebaceous matter, forming hard bony plates, no doubt proceeding from hypertrophy of the papillary layer of the skin and the corium and deficiency of the functions of the perspiratory glands, shown by the dryness, and of the sebaceous, shown by the yellow horny masses of epidermis and a collection of altered sebaceous matter.

March 3rd, 1881.

Digitized by Google

9. *A case of extensive lupus (living specimen).*

By Malcolm Morris.

C. N—, a spare female of medium height, aged 64 last October. Father died at the age of twenty-seven, probably of consumption; mother about the same age immediately after the patient's birth. No brothers or sisters.

Always enjoyed good health until 1858, and never had any eruption on the skin before the present disease. In that year she became extremely weak, so much so, that the medical man who saw her thought she would die of consumption. This condition continued till 1860, when she had an attack of general dropsy, which gradually disappeared from all parts except the legs. Towards the end of that year a brown mark was noticed on the front of the right leg (about midway between knee and ankle), which ultimately became an ulcer. Several other ulcers appeared, one on the back of the calf being large and taking more than two years to heal. The skin, in the immediate neighbourhood of the ulcers, became red and raised, and patches of a similar colour showed themselves in various parts below the knee. During the succeeding five or six years more patches appeared on other parts of the body, the left leg and arms. About ten years ago—in 1871—a small spot appeared (in character like the patches on the leg) on the vertex of the scalp. By slow degrees this patch spread downwards towards the face. Passing to the nose it gradually attacked both cheeks, and in four years the right eye became affected and the sight quickly destroyed. For the last few years the disease has spread but little.

Present condition.—The right leg: on the side of the ankle, but in front of the internal malleolus, is an ulcer about two inches in its longest diameter and one and a quarter wide. Above this, and more in the front of the leg, is a smaller ulcer. The ulcers have every appearance of healing. The edges are sharply defined. The discharge is thin and not in the least offensive. The present site of the ulcers is not the same as the original one mentioned in the history. The whole of the front of the ankle, side, and back of the leg is occupied by cicatricial tissue. The foot, including the

Digitized by Google

sole, is dry and hard and covered with scales, which are closely adherent. The skin of the leg and thigh is hypertrophied and scaly, the disease terminating on the thigh about three inches from the hip-joint in an abrupt line, which in parts is slightly raised above the surface, and is redder than the rest of the limb.

The left leg: within the last few months, three patches have developed on the left leg. One large and red, made up of small tubercular masses, raised and scaly, on the outer side and below the popliteal space; one over the outer surface of the ankle; and the third about the size of the palm on the external and upper part of the thigh.

Arms: on the front of the right arm below the bend of the elbow is a patch resembling the others on the thigh, and this is joined to one on the back of the elbow. A few isolated spots are also observable on the inner side of the elbow. Besides these there are two large patches on the left arm, extending from the shoulder as far as the insertion of the deltoid, and a patch on the left thumb.

Head and face: in front of a line, curved slightly backwards and extending from one ear to the other, the whole skin is replaced by scar tissue. All the hair follicles are destroyed with the exception of those upon one small patch to the right of the middle line. The surface is smooth to the touch, shiny and slightly scaly. There has been some contraction, but the skin is not adherent to the bone. An interesting effect is produced by the movement of the occipito-frontalis. Behind the line the hair is not destroyed, but there is much scale.

The disease extends over both sides of the face and neck, attacking the forehead, nose, and cheeks, and terminating in an abrupt raised margin on either side of the chin, though on the right side it approaches nearer to the middle line than it does on the left. The left lower eyelid is drawn down and everted. The ears are thin, flabby, and compressed to the head.

Remarks.—1st. I would suggest that the disease affecting the head and face is lupus erythematosus. It is unusual for this variety of lupus to commence at so late an age as fifty-four. Mr. Waren Tay reports a case in which the disease began at fifty-one. 2nd. That the general condition of the leg is similar in many respects to the face, but that the spreading ulceration makes a marked distinction between them as a question of diagnosis. My object in showing the case is to elicit from the members an

Digitized by Google

opinion as to the pathological condition of the leg. Lupus erythematosus always, as far as I know, begins on the face, and in this case the course is fairly typical so far as the face is concerned. But the leg was affected many years before anything appeared upon the face, and in the form of ulceration which has continued more or less ever since. Was this primary ulceration lupus? There may arise a question as to whether the condition is syphilitic. I think the slow course of the attack and its superficial character are two points against this hypothesis.

April 5th, 1881.

---

10. "*Cheiro-pompholyx.*" (*Card specimen.*)

Exhibited by JONATHAN HUTCHINSON for H. MACNAUGHTON JONES, M.D. (of Cork.)

THE patient, a woman aged 40, when seen by Dr. Jones, had suffered for six months from an eruption on the palms of both hands. Mental worry and general depression were supposed by Dr. Jones to have had something to do with its production, but she had also done a good deal of washing before it appeared, using washing powder. "On consulting me there were several large bullæ on both hands, on the palms, and on the sides of the fingers, the backs of the hands had also a few pustules; there were raw portions where other bullæ had burst. I had the drawing taken to show the burnt appearance of the hands and the characteristic sago-grain eruption mixed with pustules in varying sizes which followed the bursting of the larger bullæ, also the resemblance to the state known as psoriasis palmaris, save that there were no fissures, and the skin was soft and not dry, as in the latter affection."

The specimen shown consisted of a life-size portrait of one hand by Dr. Macnaughton Jones.

Under the external applications of oil packing, vaseline, calamine, &c., and the internal use of tonics (iron, arsenic, quinine, &c.), she recovered completely in less than a month. *May 17th*, 1881.

Digitized by Google

IX. MISCELLANEOUS SPECIMENS.

1. *A case of acute myositis of thigh.*

By J. F. Payne, M.D., Hon. Sec., for C. J. Devis, Hereford.

Sarah D—, aged 33, married, family several, was admitted into the Hereford Infirmary on December 18th, 1880. She gives the following account of herself:

On Friday, December 17th, she was confined of a seven-month's child, which lived for several hours; her labour was natural, but she had some flooding afterwards, which made her weak. On the following Tuesday, the 21st, the patient, who has a very wretched home, left her bed and went downstairs into a cold fireless room, where she stayed for some hours. Whilst there she felt the cold and shivered slightly. On going upstairs again she found that she had considerable pain in the right, thigh, obliging her to crawl back on her hands and knees.

During the following two days the pain in the thigh, which was chiefly on its outer aspect, much increased, and the whole thigh became very tender, the patient not being able to bear the pressure of the bedclothes.

On the Thursday evening swelling was first noticed, which rapidly increased, whilst on the day of admission redness of the skin appeared. For the truth of these latter statements I can vouch, as they are fully borne out by the surgeon, Mr. H. B. Moore, of this town, who attended her, and by whose means she came to the infirmary.

During the five days of her illness she had had several chills, but no downright shivering, had not been sweating, complained of much weakness. There is a distinct history of acquired syphilis of old date, and her health during the last pregnancy was anything but good.

Digitized by Google

On admission.—The patient is a cachectic spare woman, very much under nourished, evidently in great pain, and is so weak as almost to be unable to speak loudly.

Her temp. 100·4° F.; pulse 132, small, compressible; extremities cool; face dusky: tongue dry and brown. Sordes on teeth, fissures round the mouth. Cardiac action feeble; no bruit.

Much pain complained of in the right thigh, which, on examination, is found to be in the following condition:

Much swollen, hard, brawny, surface dusky red, exceedingly tender, both to superficial and deep pressure, the tenderness being almost equally intense all round. Temperature raised; slight impressions left by pressure of finger.

From the history of the case and from local symptoms a diagnosis of acute ostitis of the femur was diagnosed. A consultation was held, and it was deemed unadvisable to make incisions in the present condition of the patient. The whole of the thigh was painted with a strong solution of iodine, and quinine with digitalis and brandy were given hourly. There is some tenderness down front of tibia.

19th.—Has passed a fair night, slightly delirious; much tremor; tongue still dry and brown; is very drowsy; pulse failing. Temp. 100°. Says pain is less. Much tenderness still present.

From the date of the last note the patient gets gradually more feeble, and died on the 20th at 3 a.m.

Post mortem.—December 20th, 2 o'clock, p.m., eleven hours after death. The body of a young female, much emaciated, with well-marked cachexia. Abdominal walls, thin and flabby. Rigor mortis moderate. Hypostasis moderate.

A section was made through the greatly swollen right thigh, which was very hard, pitting slightly on pressure, and giving a sense of deep elasticity to manipulation. The section was carried through the limb at the junction of its upper and middle third, and a corresponding one was made half through the sound limb.

Girth of limb at point of section 58 cm., as opposed to 43 cm., the girth of the opposite limb. Thickness of skin and adipose layer 1·3 cm., showing no increase in thickness over the normal limb. Thickness of quadriceps extensive. Muscle in middle line in front 6·5 cm. as opposed to 4 cm., in the healthy limb. Periosteum and bone not thickened.

Digitized by Google

The surface of the section is seen to be strangely altered in appearance, the only approach to normal colour in the muscles being seen in the rectus femoris, sartorius, adductor longus, and hamstrings.

The crureus, both vasti, and adductor magnus are of a pale reddish-grey colour, tinged with yellow, reminding one forcibly of the lung in an early condition of grey hepatisation. The surface is resistant, and the fasciculi are separated from each other, giving rise to a coarsely granular appearance. A small amount of serous fluid exudes from the section; the intermuscular septa are seen to contain serous fluid (look œdematous).

The above appearances are most marked in the external vastus, thence shading off towards normal through the crureus, vastus internus, and adductor magnus, the latter only being tinged with grey. All the other muscles look pale, and are more resisting than those of the healthy limb.

Viscera.—Heart, small; flabby.

Lungs pale and emphysematous at edge; bases congested.

Kidneys.—Increase of cortex, congested, slightly grey on section; capsule inclined to be adhesive in places.

Liver normal, except depressed by a narrowed thorax.

Spleen normal.

Uterus rising to a level with a half distended bladder. Os uteri and cervix admit a forefinger with ease. Mucous membrane dark purple, thinly covered with glairy fluid. Fundus showing remains of decidua. Colon dark purple, tissue firm.

Head not examined.

A microscopic examination of a fresh specimen showed:—in the vastus externus the striæ of the fibre lost, a large amount of granular *débris* covering the whole specimen and apparently within the sarcolemma and very few cellular elements.

In the adductor magnus the striæ are plainly marked; there are a considerable quantity of cellular elements, both red blood-cells and leucocytes; the blood-vessels running between the fibres are gorged with red cells, and in some cases have a beaded outline.

In the rectus femoris the muscular tissue appears normal, except that many of the blood-vessels are gorged with red cells.

January 18*th*, 1881.

Digitized by Google

2. *On a case of arrested development and growth of the right upper limb in man.*

By Samuel G. Shattock.

The ill-developed member was removed by Mr. Erichsen from a gentleman, somewhat below the middle stature, and 22 years of age, the limb being successfully amputated through the lower third of the upper arm.

The left upper limb was naturally proportioned to the rest of the body; the right, from the olecranon to its extreme point, measures only about nine inches.

The three inner digits are webbed as far as the roots of the nails; the index and medius, to the base of the terminal phalanx.

The hand is flexed and adducted; there is complete ankylosis of the wrist. The thumb is flexed and displaced behind the other digits, the terminal phalanges of which are flexed to a right angle, and retain a slight degree of mobility. The forearm is semiprone; the elbow is ankylosed nearly at a right angle.

Osteology.—The humerus is laterally narrowed—both its shaft and lower end—scarcely any indication of either condyle existing. The upper end of the radius lies above the ulna, though more to the outer than to the inner side of the narrowed end of the humerus, to which both bones are ankylosed. The bones of the carpus are ankylosed to those of the forearm and to one another, so as to form a single osseous mass, on which the metacarpal bones have slight mobility. The metacarpal of the index is dislocated backwards; that of the medius is not more than half an inch long, and is loosely connected with the carpus by firous tissue. None of the four inner digits possesses more than two recognisable phalanges, an ungual, well formed and normally connected with a phalanx of considerable length, which articulates with the head of the metacarpal bone. In the index and medius this phalanx measures an inch and five eighths, in the annularis and medius slightly less. This measurement corresponds very closely with that of either the first or second phalanx of the same digits in two skeletons of five feet which I have examined. In a child's skeleton, in which the diaphysis of the ulna measured 5¼ inches (which is

Digitized by Google

the length of the ulna in the specimen), the first phalanx of the index measured $\frac{7}{8}$ths inch, of the medius 1 inch, the second phalanges measured, in the same digits $1\frac{1}{16}$ths inch. The length of the phalanges in the specimen, therefore, is so nearly equal to that of the first and second together in a skeleton of approximately the same size that they probably represent two phalanges conjoined or undifferentiated.

Myology. — Pronator teres: no indication of this muscle is present. Fl. carpi. rad.: the tendon is not traceable beyond the end of the radius, on the outer margin of which it terminates in a slightly expanded insertion. The muscle generally is diminutive. Palmaris longus: has a broad origin from the humerus, and no distinct tendon of insertion, being fixed directly to the anterior fascia of the forearm. Fl. dig. sublimis: furnishes tendons to the four inner digits, that to the annularis being considerably larger than any other; that to the index terminates in a thin expansion over a fully-sized tendon derived from the fl. longus pollicis. Fl. carpi ulnaris terminates on the ulna in front of the styloid process. Fl. longus poll. is distributed below on two tendons, of which one, nearly as large as that to the pollex, supplies the index finger. It also furnishes a fine tendinous slip to the deep and outer part of the annular ligament. Fl. profundus digitorum: terminates in a broad tendinous expansion inserted into the outer portion of the ankylosed carpus. The indicial portion of the fl. prof. is differentiated as usual, and furnishes a small tendinous fasciculus to the annular ligament, though its chief part is expanded on the carpus in common with the rest of the tendon. The deep muscles, fl. l. poll. and fl. prof. dig., are separable for their entirety, though contiguous superiorly. All the short muscles of the thumb and little finger are represented. An additional muscle arises from the annular ligament to the inner side of the superficial head of the fl. brevis poll., and is inserted into the integument between the thumb and index. It possibly represents the first lumbrical. A fleshy fasciculus arises from the fascia of the forearm to blend below with the hypothenar muscles; a second passes from the fl. carpi. ul. to the same muscles. Pronator quadratus present. Interossei and lumbricales, absent. Most of the muscles are streaked with pale yellow lines of fat. Sup. long. is represented by a fibrous band extending from the usual seat of origin to the upper end of the radius, but with difficulty definable

Digitized by Google

from the periosteum beyond the upper end of the bone. The muscular tissue of the extensors is represented by a thin degenerate sheet on the back of the upper half of the forearm, whilst the tendons are with difficulty traceable, being incorporated, after atrophy, with the periosteum of the conjoined radius, ulna, and carpus. The inserted tendon of the ext. carpi rad. longior is traceable to the dislocated metacarpal bone of the index. Each of the digits except the thumb has a recognisable extensor tendon. These tendons are attached proximally to the bases of the metacarpal bones; that of the annularis to the base of the medius. Between the bases of the medius and index is a well-marked fibrous band, of doubtful significance, perhaps ligamentous; beneath this, passing to the base of the medius is recognisable the tendon of the ext. carp. rad. br. The extensor tendon on the annularis is attached proximally to the base of the median metacarpal. Lastly, a fibrous fasciculus, ex. carp. ul., passes between the base of the minimus and the lower end of the ulna.

Remarks—Whether the singleness of the carpus is the result of coalescence or ankylosis of parts at one period distinct, or whether the carpus has been single from the first, as indicating an arrest of development, may be now impossible to determine. But the fusion of the elbow at a right angle would point to an ankylosis subsequent to a proper articular formation, such as happens purely from long immobility; and the ankylosis of the wrist and forearm may perhaps be due to the same disuse.

Fort in his essay ('Les difformités des doigts') notices that phalangeal suppression, except in supernumerary digits, is of very rare occurrence. He quotes a case from Ménière of a woman, aged fifty, in whom the medius of the right hand presented only two phalanges, and was shorter than the minimus. In another case, quoted by Fort (p. 90), a man, aged twenty-two, there appeared only two phalanges to all the fingers, but the first phalanges were nearly twice the length of ordinary phalanges.

It would appear that in this case, therefore, the first and second phalanges of the four inner digits were connate, or had coalesced, as in the present specimen.

The most noteworthy fact in regard to the muscular arrangement is the complete supply of the index by the fl. long. poll. in place of the fl. prof. dig. I am unable to find that a condition quite like this has been recorded in the human subject. Cases are

Digitized by Google

given by Wood[1] in which muscular slips have connected the fl. long. poll. with the indicial portion of the fl. prof. dig.; and one case in which the indicial tendon of the fl. dig. prof. was reinforced by a slip from the fl. long. poll., as well as another in which the fl. l. poll. supplied an independent tendon (additional to that of the profundus digitorum) to the last phalanx of the index; and Prof. Thane has observed three cases similar to that of the second class.

A case is recorded also by Wagstaffe,[2] in which the chief part of the tendon of the fl. long. poll. joined the index tendon of the fl. prof. dig.; a second portion spread out on the carpus and attached itself to the ligaments covering the carpal bones; whilst a third part left the tendon rather higher up, and was inserted by a well-defined triangular expansion into the outer surface of the outer head of the fl. br. pollicis.

"In this case, moreover, there existed a tendon resembling that of the fl. long. poll., but only stretching between the head of the metacarpal bone and the ungual phalanx."

The complete supply of the index by the fl. long. poll. is recorded in the dissection of a chimpanzee by Mr. Champneys,[3] but both in the chimpanzee and the gorilla "the rule appears to be that the flexor pollicis unites at its origin with part of the flexor profundus, and that the fleshy fibres converge to a common tendon, which divides into two, one for the pollex and the other for the index."[4]

The termination of the fl. prof. dig. at the carpus is quite unusual. The three inner tendons of the sublimis and the indicial tendon of the fl. long. poll. are inserted into the ungual phalanges. This condition is to be associated perhaps with the suppression of the proper second phalanx, into which the perforated tendon would have been inserted, though it is still obscure why the perforans should be furnished in the three inner digits from the sublimis rather than from the deeper muscle. The disappearance of the extensor tendons on the back of the carpus is probably due to complete atrophy, whilst the portions lying over the phalanges may have persisted from the slight movements permissible between the phalanges.

Whether the muscular anomaly is to be associated with the

[1] 'Proc. Roy. Soc.,' 1864-5-6-8.
[2] 'Journal of Anat.,' vol. vi, p. 212.
[3] 'Journal of Anat.,' vol. vi, p. 186.
[4] Huxley, 'Vertebrates,' p. 483.

Digitized by Google

arrest of development indicated by webbing of the digits is open to question. Both evidence an ill-accomplished segmentation. But as a nearly similar anomaly has been many times observed, without this persistence of the primitive web, in which the digits are differentiated, the logical requirements of the evidence might need that in these cases of webbed fingers such muscular anomalies should be at least indicated, if not constant. *March 15th*, 1881.

---

3. *Two cases of truncated arms bearing at the ends fœtal hands voluntarily mobile.*

By Richard Barwell.

Children are not very infrequently born with one or more limbs truncated. Haller considered this condition to be due to imperfect development. Subsequent writers, more especially obstetricians, looked upon the cases as the result of gangrene. But since Montgomery's papers, which were quickly followed by Simpson's, all these cases have been referred to intra-uterine amputation—the result of inflammation of the ovum membranes—producing cords of fibrin which, twisting and tightening round the limbs, slowly severed the extremities.

That this sort of amputation does take place is undoubted, nevertheless I cannot think that it is the usual method of truncation; if it were so more records of separated parts born with, after, or before the fœtus, would be extant.[1]

Now, Simpson in his paper describes the appearance, at the end of the stump, of five little fingers with nails, and he expressly states that these are produced by "Rudimentary reproduction," indeed, his paper is called by that name. He took a little pin-hole leading to the radius (not bare) as a still unhealed part of the flap.

[1] I find but three, Watkinson, 1824 (which quoted by Montgomery is collated by Simpson from Frorieps' 'Notizen,' and then requoted as a new instance by Montgomery), Zagorsky, 1834, with foot hanging to amputating thread, Fitch, New Boston. In Watkinson's case the foot was born half an hour after the child; in Fitch's foot born 21st March, child on 5th April.

Digitized by Google

I have brought two young women here to-night with truncated arms. In the one, four very rudimentary fingers, without nails, are to be seen at the end of the stump; and at the side of them, about an inch away, a little deep punctured fossa, which is probably the remains of Simpson's pin-hole. In the other, the older woman, the fingers are more developed, and there is a thumb, also the indication of a palm, but no pin-hole pucker. Neither of the patients have any nails on the fingers.

We might, perhaps, fall in with Sir James Simpson's views, and consider these fingers to be "rudimentary reproductions," if it were not for the very considerable movement they enjoy, not separately, but the whole little bunch of them; the hand, if we may call it so, turns in the direction of supination and flexion, at the will of its possessor, and back again. We cannot, I suppose, for a moment imagine that the muscles, with their innervation, would be formed in "rudimentary reproduction," and if not the muscles, then also not the fingers.

But if we give up the idea of rudimentary reproduction, then also we must abandon in these cases the notion of intra-uterine amputation, and in my experience a vast majority of truncated arms have these curious little fingers attached to them—little undeveloped hands that have been there in much the same state, only appended to smaller limbs, since about the third month of fœtal life.

Therefore we must go back to Haller's view, that most of these cases are arrested development. I believe I know how this arrest is achieved, but must give the matter a little more study.

I tried to find two more such cases that I know of; but they seem to have moved into another part of the town.

February 15*th*, 1881.

Digitized by Google

4. *Case of unilateral hypertrophy of the head and face, involving bones and soft parts.*

By Richard Barwell.

About six years ago I came across the boy who was the subject of the singular and grotesque deformity now shown. He was then seven years old, and was, on account of the condition, leading a very miserable life. He was not allowed to go to school, because he distracted the attention of the boys and frightened the girls. He was forbidden to appear outside his mother's cottage during the day, lest the teeming mothers of that part might see him, get a "maternal impression," and he thus might stamp his type and image on the whole district.

Woodcut 7.

I admitted him into Charing Cross Hospital, and, after much examination, tied the common carotid artery just above the sterno-

Digitized by Google

clavicular joint with catgut; not that I had much hopes of improvement from this alone, but believed, as a first step, it would, at all events, facilitate further measures. Secondary hæmorrhage occurred on the sixth day, and he died, after no great loss of blood, indeed after much less hæmorrhage than one would expect to prove fatal.

The condition, about to be described, was observed so soon after birth that it was almost certainly congenital; but was then, of course, much less marked than afterwards, and the disproportion between the two sides was still increasing; indeed, I think there was a marked difference at the time of my first seeing him, and the time of his reception into hospital.

It would be, I think, impossible to describe the appearance of this child by mere words. The enormous development of the right side of the head and face—in length one and a half times, in breadth twice, the size of the other. The way, in which the hypertrophied push over and displace the non-hypertrophied parts, gives to the aspect, particularly when contrasted with the other side, a most singular and grotesque appearance. The texture of this mass was soft, little less so than the yielding, yet elastic, structure of a fat infant's cheek. Near the ear was a patch of dark, horny ichthyosis (true hypertrophy of cuticle), which was increasing in size. The thickness of lips and cheek of the right side, felt with one finger inside the other outside the mouth, was very considerable; but it is important to observe, lest this be mistaken for a mere cyst, that the bones are as much involved as the soft parts. I show casts of the jaws. The massive and thick bones push the sutures quite over to the left, where the baby teeth form a strange contrast with the great incisors and molars of the right. The raphé of the tongue, too, lies, as seen on the cast of the lower maxilla, quite on the left of the middle line, and the tongue itself was thus also unilaterally hypertrophied; hence it is possible that imperfect or perverted action of the sympathetic system of the neck was the real producing cause of this condition.

I have brought the actual head with me; it has been long in spirit, since much work has prevented me showing it here before, which I wished to do previous to dissecting it, and having the skull prepared.

I should like to observe that unilateral overgrowth of the head and face, of which I show a photograph here, is not very uncommon. This was sent me by my friend Mr. Wilcox, of Aylesbury. Uni-

Digitized by Google

lateral overgrowth of the trunks and limbs is still more common. I show a photograph of such condition. It is, when less strongly marked, one of the frequently overlooked causes of lumbar curvature of the spine. I have within the last month seen two cases in which all the right side—head, face, trunk, and limbs, as shown by measurements accurately taken—were markedly larger than the other half of the body. This overgrowth is nearly always on the right side. Of course, none of these are to be compared with the giant growth of this boy, George S—.

March 3rd, 1881.

---

5. *Dissection of cleft palate, from the adult.*

Exhibited by SAMUEL G. SHATTOCK.

NORMAL union has failed in the velum and between the maxillæ, the cleft ceasing anteriorly in the situation of the anterior palatine canal.

Both the nasal fossæ communicate through the cleft with the mouth. The levator and tensor palati and the palatal portion of the palato-pharyngeus have been dissected on the left side. The several muscles are of healthy texture and in every way natural, except for their partial deficiency.

November 3rd, 1880.

Digitized by Google

6. *Lymph scrotum, showing filaria in sitû.*

By P. Manson, M.D., of Amoy.

(Communicated by G. Thin, M.D.)

The preparation exhibited to the Society on May 17th by Dr. Thin, as an example of the disease I have called lymph-scrotum, is unique. For, although lymph-scrotum[1] is common enough in certain countries, and as a morbid preparation has occasionally been exhibited in Europe, and the parent of the hæmatozoon, named by Lewis *Filaria sanguinis hominis*, has been found by at least four observers, yet I believe this is the first instance in which the parasite has been found to occupy its proper habitat, a lymphatic vessel, and has been seen *in sitû*.[2]

The man from whom this lymph-scrotum was removed last October had suffered from symptoms of lymphatic obstruction for about five years. At intervals lymph was discharged from vesicles on the surface of the scrotum, and for the last three years the discharge had been almost constant. The usual and characteristic vesicles covered the lower part of the scrotum, the tissues of which were thickened, but not indurated or greatly enlarged; to the touch they felt soft and spongy. The groin glands on both sides were enlarged and felt indurated, or rather as if an indurated nucleus was surrounded by a spongy varicose cortex. The clear straw-coloured coagulable lymph contained embryo Filariæ, but though frequently searched, blood from the finger yielded no parasites. The man's spleen was considerably enlarged and he was intensely anæmic. As there seemed no prospect of the lymphorhagia ceasing, to save his life I was compelled to remove the scrotum. Before operating I ventured to prognosticate that the parent filaria would be found in the part removed. That I was justified in making this prognostication was proved by the parasite appearing on the cut surfaces of the scrotum in active movement.

[1] This disease has received various names, as varix lymphaticus, nævoid elephantiasis, &c. I prefer lymph-scrotum to these; it is shorter, as expressive, and more English.

[2] For a clinical report of this case see 'Lancet' of January 1st, 1881, and 'China Customs Medical Reports,' 20th issue.

Digitized by Google

It turned out to be a female. Half of the animal lay in a dilated lymphatic, and is still there, for on my attempting to withdraw it the body snapped across. Probably the male is there also.

In order to make clear the reasons for the prognostication I made, it is necessary to examine the entire subject of *Filaria sanguinis hominis* and its connection with certain diseases, a subject as yet little understood, but one destined, both from its scientific interest and vast practical importance, to occupy no insignificant place in pathology.

Its enormous practical importance will be comprehended when I state that wherever elephantiasis[1] is endemic this parasite is to be found; that elephantiasis is endemic over half of the globe, at least over that part of the globe where the major part of mankind resides; that this parasite produces a group of diseases very common in these countries which, though not frequently fatal, do sometimes kill, and always give rise to much pain, deformity, and inconvenience; that it is in our power completely to prevent the access of the animal to the tissues of man, and thereby prevent these disease; and that this most desirable result can be attained by the simplest of means. These seem sweeping statements, but the sequel, I am convinced, will fully bear me out in making them.

For a complete account of the gradual progress of our knowledge of this parasite I would refer the reader to Cobbold's recently published work on 'Parasites.'[2] There the history of the subject is given, along with an exhaustive bibliography, down to the date of the publication of his work. I will confine myself to stating only so much of the history as is necessary to understanding the subject, and will avoid as much as possible everything that appears to me unimportant or doubtful.

The animal I saw wriggling on the cut surface of the lymph scrotum shown to the Society, and half of whose body is still lying in the lymphatic vessel it occupied during life, is the parent of an embryo nematode first found in chylous urine by Wucherer in 1866, and in the blood by Lewis in 1872, and named by the latter observer *Filaria sanguinis hominis*. The embryo was discovered several years before the mature animal, for it was not till 1876

[1] Elephantiasis arabum. Throughout these remarks when the word elephantiasis is used, elephantiasis arabum alone is meant, not leprosy.

[2] 'Parasites': a Treatise on the Entozoa of Man and Animals. By T. Spencer Cobbold, M.D., F.R.S. London, 1879.

Digitized by Google

that Bancroft in Australia, and a few months later, in 1877, Lewis in India, found the parent worm. Since then the mature animal has been found by Aranjo and dos Santos in Brazil, and by myself in China, and has been named by Cobbold *Filaria Bancrofti*. Only a small part of the male worm has hitherto been found, and as in this case it was intimately associated with the female, it is extremely probable that the sexes live together. Like the males of most Filariæ, it was considerably smaller than the female. The latter is a long, slender, hair-like animal, quite three inches in length but only $\frac{1}{100}''$ in breadth, of an opaline appearance, looking as it lies in the tissues like a delicate thread of catgut animated and wriggling. A narrow alimentary canal runs from the simple club-like head to within a short distance of the tail, the remainder of the body being entirely occupied by reproductive organs. The vagina opens about $\frac{1}{25}''$ from the head; it is very short and bifurcates into two uterine horns, which, stuffed with embryos at all stages of development, run backwards nearly to the tail. Under the microscope, fully-formed embryos, just as we see them in the blood, can be seen escaping from the vagina. The animal is therefore viviparous.[1]

For further details on the structure of the parent worm Lewis's[2] and Cobbold's writings should be consulted. Here, I may not occupy space with helminthological detail unnecessary for the full understanding of my argument, but there is one point it would be well to settle before proceeding with the history of the parasite, and that is, the exact position occupied by the animal in the human body, what tissue or vessel.

The preparation shown to the Society is almost sufficient to settle this. In it, when fresh, and immediately after its removal from the body, the animal was seen protruding from the cut end of a lym-

[1] Having seen the ova of the parasite in lymph abstracted from lymphatic glands, and as Cobbold described similar ova in urine, I concluded some time ago, relying on the regularity of the operations of nature, that the filaria was oviparous. Cobbold is not very explicit on this point, and Lewis's description admits of such an interpretation. Since that time I have twice examined the uterus of the parent, and having paid particular attention to this point, I have no hesitation in saying that under ordinary circumstances she is viviparous.

[2] "The Microscopic Organisms found in the Blood of Man and Animals and their Relation to Disease," by Timothy Richard Lewis, M.B., reprinted from the 'Fourteenth Annual Report of the Sanitary Commissioner with the Government of India, 1877.

Digitized by Google

phatic vessel, from which it had partly crept out; the other end of the dilated vessel was seen in the face of the wound, and from it, the groin glands being pressed with the hand, lymph was seen to regurgitate. Even prior to this the lymphatics were credited with being the proper habitat of the animal, for in many cases of lymph scrotum, chyluria, and varicose groin glands, its young have been found in the lymph. It might have been objected to this, as a conclusive argument, that possibly those embryos found their way into the lymphatics by escaping from the capillaries. This is extremely unlikely; yet, admitting its possibility in the case of the free embryo, such a feat would be impossible to the ovum, both on account of its diameter and its being a perfectly passive body. Ova, however, have been found in the lymph, and the ovum being too large to pass from the outside to the inside of a lymphatic, and having no power to work its way, the parent that laid it must have communicated directly with the lymphatics. Again, in not a few instances filaria embryos have been found in the lymph discharges of individuals from whose blood not a single specimen could be obtained; they could not, therefore, have come from the blood-vessels. It may be taken as settled that the parent worm lives in the lymphatics.

Thus, then, the parent filaria lying in a lymphatic vessel emits her young into the lymph stream. Along this they are carried to the lymphatic glands. As they are only about $\frac{1}{350}''$ in diameter, no larger than many of the lymph corpuscles that accompany them, they have no difficulty in entering and traversing the minute vessels into which the afferent lymphatic divides. For the same reason, and by virtue of its vigorous movements, it passes the parenchyma of the gland, and, emerging into the efferent vessels, is borne along the current till, having traversed gland after gland and their connecting vessels, it finds itself in the thoracic duct, and finally in the blood itself.

As found there, and also in the lymph, this nematode embryo, when examined by a high microscopic power, is seen to be a long, slender, snake-like, gracefully-shaped animal, possessed of an activity so great that, until paralysed by approaching death or inspissation of the medium it lies in, measurements and observations of structure can hardly be made. It measures about $\frac{1}{90}'' \times \frac{1}{350}''$, is perfectly transparent, and apparently structureless. The anterior part of the body tapers slightly, and at its very extremity a pouting

Digitized by Google

movement, as if of breathing, is to be detected. Posteriorly, the body gradually tapers down to a fine point, the extreme end of which, in some specimens, has the look of being articulated, for this part does not always harmonise with the general curve of the body, but seems bent at an angle. In other individuals a brown aggregation of granular matter can be detected about the centre of the body, half way between head and tail. An extremely delicate sac encloses the animal, fitting it accurately; but as this sac is about one third longer than the body, it is unoccupied, and collapsed into the semblance of a lash at the head or tail, or both, according to the position and direction of movement of its contents. If the animal is rushing forward, the anterior part of the sac is occupied, and a long lash of collapsed sac dangles from the tail; if the animal is retreating tail first, then this part of the sac is occupied, and the superfluous integument trails after the head.

If a man in whose blood this parasite has been found is kept constantly under observation for a number of days, and freshly-drawn specimens of his blood examined at short intervals, it will soon be evident that the parasite is not equally abundant at all times; in fact, that often it is entirely absent. Sometimes slide after slide will be examined without a single specimen being discovered, notwithstanding that a few hours before the parasite could be found by the hundred in every drop of blood. If a register of these observations is kept it will presently be apparent that there is a diurnal periodicity in this presence and absence of embryos in the general circulation. It will be found that during the day, unless under peculiar circumstances, they are entirely absent, that about six or seven o'clock in the evening, with "military-like punctuality"—as Cobbold expresses it—they march to their night quarters; gradually, as night advances, their numbers increase; by twelve o'clock as many as 100, or even more, may be counted in every drop of blood. About this time their numbers reach the maximum, and then, as morning approaches, they become fewer and fewer; by eight or nine a.m. they entirely disappear. From nine a.m. till six p.m. very rarely is it possible to procure a single specimen. The only thing that interrupts the regularity of this periodicity is an attack of fever. If this does not occur it is maintained day after day. I have watched it preserve its rhythm for a month on end, and there is no reason for supposing that, but for the exception mentioned, it is ever interrupted. This is a most

Digitized by Google

remarkable phenomenon, and one as yet unaccounted for. But, though we may not be able to explain it, we understand its object, for night is the time when, at the surface of the body, the embryo has an opportunity of advancing in its development.[1]

There appears to be no reason for supposing that after the embryo leaves the uterus of its parent, and as long as it remains in the body of the original host, there is any advance in development. As seen in the blood, all look much alike, and, indeed, it is evident that any degree of growth would be incompatible with the life of the human host. Such a swarm of animalcules, did they but each attain a hundredth part of the size of their parents, would soon make life impossible. For this reason, as well as for the reason that the species to be continued must pass into other men, the embryo must leave the original host. But how? Only on rare occasions have they been found in the excretions, and then only in those of a morbid character.

Nature is not likely to trust to the accident of a disease for the continuation of a species. Her operations are always orderly and reveal a plan. She may be careless of the single life, but she is very careful of the species. Seeing, then, that there is no provision made in the structure of the embryo for its spontaneously escaping from the body, and that this escape must be effected, it follows that some outside influence must bring this about.

In the somewhat analogous parasite, *Trichina spiralis*, such an opportunity is afforded by the animal that devours the flesh of the original host. But in few countries is human flesh devoured in so wholesale a fashion as would warrant us supposing the *Filaria sanguinis hominis* was similarly treated.

As the embryo parasite lives in the blood, it is likely that the first step in its development and towards freedom will be given it by something that abstracts the blood. Thus, then, the privilege will be confined to a very limited number of animals—the blood suckers. This includes the fleas, lice, bugs, leeches, mosquitoes, and sand-flies. But, as the parasite is confined to a limited area of the earth's surface, it is more than likely that this friend of the filaria has a corresponding and limited distribution. Fleas, lice, bugs, leeches, as they are found pretty well all the world over, must therefore be excluded.

[1] 'China Customs Medical Reports,' No. 18; also 'Transactions of the Quekett Microscopical Club.'

Digitized by Google

Reasoning in this way, I concluded, in the summer of 1877[1] that either the mosquito or the sand-fly liberated the parasite. Had I been aware then of the nocturnal habits of the worm, I would have excluded the sand-fly likewise. In this way, then, reasoning from its faculty of piercing the blood-vessels, its nocturnal habits, and its geographical distribution, the mosquito appears the most suited of all animals to assist the parasite. And as there are many species of mosquitoes everywhere in the tropics, and in many other parts of the world, but filaria disease is limited, it follows that every species of mosquito will not answer, it must be a species similarly limited. I know of several tropical species that are impotent to assist the parasite, but there is at least one species possessing all the necessary qualifications, and which others, as well as myself, have, over and over again, proved to be an efficient intermediary host for *Filaria sanguinis hominis*.[2] The female of this particular species of Culex (it is with her alone we have to deal, the male, owing to the construction of his oral appendages being incapable of piercing the skin) is a small, dark-brown insect, of about $\frac{3}{16}$ths of an inch in length. She may be recognised by her size, her colour, and the entire absence of markings on her abdomen, thorax, or legs. Her head is small and dark, and carries a proboscis about two thirds the length of her body, dark, too, like the head, strong, and slightly bulbous at the free extremity. About sunset the sexes leave their retreat, and for an hour or two wheel about in the air, generally, when in a house, near the ceiling. About 8 o'clock they descend in search of food, and the female greedily avails herself of the blood of the first animal in which she can fix her proboscis, be it man or beast. About two minutes suffice, if she is not disturbed, to fill the stomach. She then retires to some shady place, if possible in the vicinity of water, and during four or five days is occupied in digesting the single meal and maturing her ova. When this is completed she betakes herself to the water, and on the surface of this deposits two little boat-shaped masses of eggs. After effecting this she dies.

If, then, a female of this particular species of mosquito pierces the skin of a filaria-infected subject, the proboscis, buried in the

[1] 'China Customs Medical Reports,' No. 14, 1878; 'Linnæan Society's Journal of Zoology,' vol. xiv, p. 304.

[2] Lewis, op. cit., Arango (see Cobbold's 'Parasites,' p. 198); Bancroft ('Diseases of Plants and Animals,' &c., a pamphlet published in Brisbane, Australia).

Digitized by Google

blood stream, is speedily beset by the embryos. These, as they are carried along by the current, become entangled by their lashes, and are then transferred in great abundance, along with the blood, to the stomach of the insect. Here for a time they continue their movements, but gradually, as the blood coagulates and becomes digested, motion is restricted, and finally, but for an intermitting jerk of the tail, entirely ceases. Some are digested or are expelled in the fæces. A favoured few, however, survive, and enter on a very interesting metamorphosis. First, the hitherto smooth and perfectly structureless body becomes marked by delicate and closely set, transverse striæ, as if from general longitudinal shrinking, and the bag in which it has hitherto been tightly enveloped appears separated from it by an appreciable interval, and possibly finally disappears. Then the striæ lose their distinctness, and the body of the animal seems as if it became broader, shorter, and filled with a fluid containing granular matter, and exhibiting slight to-and-fro movements. The extreme tip of the tail, probably that portion of it described as if articulated to the rest of the body, does not partake in the general broadening, but looks like an appendage stuck on to the sausage-shaped mass; at short intervals it exhibits sudden and vigorous movements of flexion and extension. By-and-by minute cell-like bodies appear and arrange themselves along a line now beginning to be visible in the centre of the cylinder, and opening near, but a little in advance of, the tail at one end, and at the semblance of a mouth at the other. At this stage the animal is perfectly passive and its caudal appendage shortens and disappears. Growth now commences, and with growth a swaying movement of the anterior part of the body. As growth progresses movement increases, and finally, when the little animal has attained a length of about the thirtieth of an inch, it exhibits prodigious activity, rushing forwards or backwards indifferently and thrusting every obstacle aside. If by pressure we restrain its movements, or fracture its delicate body, its head is seen to be crowned with three or four nipple-like papillæ, an alimentary canal is visible running from mouth to anus, and rudiments of generative organs can likewise be traced.

By the time this metamorphosis, occupying from four to six days, is completed, the life of the friendly mosquito is concluded, her stomach is empty but for these formidable-looking guests, her ova have been deposited on the surface of the water, her life cycle is finished, and she dies, probably falling into the water on which her

Digitized by Google

eggs were laid. What now becomes of her guests? As yet we cannot tell for certain. Up to this point the history of the embryo from the time it left its parent in the lymphatic vessel has been followed step by step, and there cannot be the slightest doubt about any part of it. But now an hiatus in our knowledge of its life cycle occurs, and until some animal other than man, capable of becoming the host of this parasite, is discovered on which we may experiment, or some enthusiast is willing to lend himself for the purpose appears, this hiatus is not likely to be filled in, except by conjecture, conjecture founded, however, on, and borne out by, analogy.

By the time the mosquito dies the parasite has so far advanced in development that there seems nothing wanting to fit it for independent life and a journey through the tissues of a human host. It possesses an alimentary canal, its head is armed with a boring apparatus, and it is possessed of sufficient strength and activity to wield this efficiently. It is also in the medium most likely to afford it an opportunity of gaining access to its final host. What more probable than that, boring its way through the dead and sodden body of the insect, if it has not already escaped with the ova, it finds itself in the water, where it remains for a longer or shorter time, perhaps to be captured by some animal in search of food, or, haply, to be swallowed by man himself. Once in the human stomach, it soon bores its way into the thoracic duct or some lymphatic vessel, and, working up stream in obedience to strange instinct, pierces the glands, and finally arrives at its permanent abode in some distant lymphatic vessel.[1] Here it is followed by one of the opposite sex, obedient to sexual instinct. The couple grow, and for years live together and breed, the progeny passing along the vessels through the glands and into the blood, there to await their chance of a friendly mosquito to help them, as it had done their parents, towards maturity.

[1] Helminthology supplies us with many illustrations of this faculty of travelling towards and selection of a suitable habitat possessed by those lowly organised animals. The same instinct guides the trichina to the muscles, the liver fluke to the gall-ducts, the giant strongyle to the pelvis of the kidney, the *Bilharzia hæmatobia* to the veins of the bladder, the *Filaria immitis* to the right ventricle of the dog, the *Filaria sanguinolenta* to his œsophagus, the *Filaria corvi torquati* to the pulmonary artery of the crow, the *Filaria picæ mediæ* to the semilunar valves of the magpie, and a similar instinct brings the sexes together in these dark corners.

Digitized by Google

This, then, there can be little doubt, is an exact account of the life cycle of *Filaria sanguinis hominis*. And there is nothing in it, or in its relations to the human host incompatible with the perfect health of the latter. The slight amount of injury done to the lymphatics by the minute immature parasite in its travels towards its permanent abode is so trifling, that no serious disease can possibly result from it. The mature animal itself lies extended in a vessel, and is perfectly adapted, by its size and shape, for the situation it occupies; it creates no irritation, and the small amount of obstruction it may give rise to is readily compensated for by a rich anastomosis. The embryos move along with the lymph, and, being no broader than the corpuscles, readily pass the glands and enter the general circulation. Here they give rise to no trouble, but circulate as easily as the blood-corpuscles.[1] In fact, the parasite seems, in every respect, well calculated to live in perfect harmony with its host, and not at all likely to be the cause of serious injury or disease. Nevertheless, that it does become at times a cause of disease and danger is certain. What these diseases are, and how the parasite brings them about, will appear in the sequel.

If, in a country in which the filaria is endemic, as for example, South China, the blood, say of 1000 natives selected indiscriminately, is examined some time between sunset and sunrise, in about 100 the *Filaria sanguinis hominis* will be discovered. If the history of these filaria-infested individuals is inquired into it will be found that a considerable proportion of them enjoy good health; others suffer from frequent attacks of fever characterised by well-marked stages of rigor, pyrexia, and diaphoresis, resembling in this respect ordinary intermittent fever, but differing from it in the irregularity and length of the interval—often weeks or months between the attacks—and also in the greater length of the paroxysms; some, in addition to this history of fever, give a story of lymphangitis, and may exhibit varicose groin glands, which, they say, inflame during the attacks; others have lymph-scrotum; some have elephantiasis of the scrotum or leg, or both; others lymph-scrotum combined with

[1] Half of the dogs in China, all the magpies, one third of the crows, and many other birds harbour similar hæmatozoa, sometimes in prodigious numbers, often hundreds in every drop of blood, and yet their hosts seem in no way inconvenienced. The more I learn of these parasites the more I am convinced that when in health and undisturbed they are perfectly innocuous. Were it otherwise there would soon be an end to the host, and consequently to the parasite itself.

Digitized by Google

elephantiasis of scrotum or leg; one or two may have chyluria; and possibly there may be a case in which two or more of these affections are combined. If the 900 in whose blood no filariæ were found are examined there very probably will not be one, or, at all events, very many, examples of lymph scrotum, varicose groin glands, or chyluria. There is strong presumption, therefore, that these diseases and the filariæ are somehow connected.

If now we examine the lymph that has escaped from a lymph scrotum, or that has been aspirated from a varicose groin gland, or that escapes in the urine in chyluria, in the great majority of cases we will find in its embryo filariæ. There is strong presumption, therefore, that the connection between the parasite and the disease is an intimate one. If we examine the lymph from one of the cases of lymph scrotum, in which the disease is not associated with filaria in the blood, most probably we will find the embryo there, and if we amputate such a scrotum we have a good chance of finding the parent parasite. We may infer from this that the relation of parasite and disease is one of cause and effect; and as it would be absurd to suppose the disease the cause of the parasite, we are driven to the conclusion that, in some way, the parasite has brought about the disease, and, inferentially, the cases of varicose groin glands and chyluria.

If we follow up for several years the histories of the cases of lymph-scrotum, we will find that after a time the periodic discharges will cease and the scrotum gradually assume the characteristic appearance of ordinary elephantiasis. Sometimes we may meet a scrotum in the transition stage, elephantiasis and lymphous discharges coexisting. Occasionally we find lymph-scrotum and elephantiasis of the leg in the same subject, and in cases of elephantiasis of the scrotum we may often elicit a history of previous lymph-scrotum. Further, removal of a lymph-scrotum is sometimes followed by dovelopment of elephantiasis in a leg. Once I have seen amputation of an elephantiasis of the scrotum followed after many years by the development of the vesicles characteristic of lymph-scrotum in the operation flaps.[1] These things

[1] For abundant illustration of these diseases, both alone and variously combined, see 'China Customs Medical Reports,' Nos. 2, 3, 8, 13, 14, 18; 'Medico-Chirurgical Transactions,' vol. xlv, 1862, an excellent paper by Dr. V. Carter; 'Clinical Surgery in India,' by Sir Joseph Fayrer; on 'Varix Lymphaticus, its Coexistence with Elephantiasis,' by Dr. V. Carter, 'Transactions of the Medical

Digitized by Google

occur too frequently to be mere coincidences, and if we reflect that both lymph scrotum and elephantiasis are diseases of the lymphatics, that they are endemic in the same countries, and affect the same part of the body, we must conclude that they acknowledge the same cause; and this being proved to be the *Filaria sanguinis hominis* in lymph scrotum, it must be the same in elephantiasis.

It has been objected by some that because cases of elephantiasis occur sporadically in countries where the filaria is not endemic, therefore the filaria cannot be the cause of these particular cases, and inferentially of those in countries in which the disease is endemic. But, in answer to this, it is advanced that the mere presence of the parasite in a man's lymphatics does not necessarily produce the disease; it only does so when it gives rise to obstruction of the vessels, and anything that gives rise to similar obstruction may give rise to elephantiasis. In Europe, where the disease, is exceedingly rare, it may be something else; in the tropics, where it is exceedingly common, it is the filaria.

Another objection to the parasite theory is found in the fact that the animal does not always give rise to elephantiasis, and that the subjects of elephantiasis do not always or generally carry the embryos in their blood. How it comes to pass that the animal does not usually give rise to disease has been shown already; how it does give rise to disease in certain cases, and why it is that, giving rise to disease, the embryos of the parasite do not always appear in the blood, I will now proceed to show.

Lewis, describing the progress of the development of the embryo filaria in the uterus of the parent, says, that the immature animal does not burst its chorional envelope but that it stretches this so that after a time and before it escapes from the vagina of the parent its shell becomes its sheath. I have not had an opportunity of watching this in the case of the human parasite, but I have frequently watched an identical process in the case of the *Filaria corvi torquati*, a hæmatozoon inhabiting the pulmonary artery of the common crow of South China.[1] As the embryo nears the vaginal end of the uterine horns, by dint of vigorous movements it

and Physical Society of Bombay,' 1861 and 1862; 'Elephantiasis Orientalis,' Allan Webb, M.D., 'Indian Annals of Medical Science,' No. 4, April, 1855; 'Remarks on Varix Lymphaticus or Nævoid Elephantiasis,' by Surgeon K. McLeod, A.M., M.D., 'Indian Medical Gazette, Aug. 1st, 1874.

[1] 'Journal of the Quekett Microscopical Club,' vol. vi, 1880.

Digitized by Google

gradually separates the poles of the ovum, and before it emerges from the parent it has extended them so far that the originally round or oval sac has become converted into a sheath closely applied to the body, the superfluous covering dangling from the head or tail. Lewis's observation is doubtless correct, and is thus fully borne out by analogy. Now, if from some cause or another the embryo *Filaria sanguinis hominis* should be hurried into the lymph before the stretching of the chorion commences, what will be the consequence to the human host? In its unextended condition the ovum measures $\frac{1}{300}''$ × $\frac{1}{750}''$ or thereabouts. Its smallest diameter is thus five times greater than that of the fully formed outstretched embryo we usually encounter in the lymph and blood. It is not too large, however, to pass along the vessels, but when the lymph stream has carried it to the glands it is immediately arrested, for there the afferent vessel breaks up into many very minute branches, which end in the solid parenchyma of the gland. The imprisoned embryo has no power to aid its onward progress, but the egg lies like an embolus, passive, plugging the vessels, and damming up the lymph. There will then be complete stasis of lymph in this particular vessel as far back as the first anastomosing lymphatic. Along this the current will now pass, carrying with it other ova, these in their turn to be arrested at the first gland they reach. And this process of embolism, stasis of lymph, diversion of current into anastomosis, will go on until the whole of the lymphatic glands, directly or indirectly connected with the vessel into which the parent parasite ejects her ova are rendered impervious, provided the supply of embolic ova is sufficient, kept up long enough, or renewed from time to time.

This reads like a piece of sensational pathology, but I do not describe what I have not seen. On two different occasions (and from different individuals) I have obtained the ova of *Filaria sanguinis hominis* from the lymphatics; once from the groin glands of a case of lymphatic œdema of the legs,[1] once in the lymph exuding from a lymph-scrotum.[2] Cobbold, too, and possibly Salisbury, have

[1] 'China Customs Medical Reports,' No. 18.

[2] This case I saw quite recently; the following are my notes:

Tin, male, aged 50, a farmer from Tchiangtchin, Kio-a-tan. In his small village of 200—300 inhabitants there are several cases of elephantiasis. From one of them I removed a scrotum weighing 12 lbs. some years ago. When young, the patient constantly drank uncooked well or river water.

Digitized by Google

found ova presumably of the same parasite in the urine. The ova obtained from the case of lymph-scrotum must have come from a parent on the distal side of the groin lymphatics; she must have been miscarrying for some time, as from the fact of embryos being found in the blood they must have had, not very long before, free access to it; but as the number of these was very small, and even these soon disappeared just before the operation, embolism of the circle of glands must have been completed. The ova found in the lymph were part of the crowd that were effecting this. This worm had lived in the patient's lymphatics for at least thirty-two years. When seen he was fifty years of age, his scrotal disease commenced when he was only eighteen. In such a lifetime and in an animal whose reproductive powers are so active, the chances of some irregularities in parturition occurring once or oftener must be considerable. These cases proves at all events that the parent filaria does at times miscarry. What has happened twice, or thrice, happens oftener. And if we reflect on the long life of the parasite,

About his tenth year was very subject to quotidian or tertian ague. His scrotal trouble began when he was eighteen, with attacks of inflammation and intermitting lymphous discharge. Hydrocele also developed. These have continued till date, the scrotum enlarging to the size of a child's head. When it inflames, the glands also become very painful and more swollen.

Lymphous discharge occur three to ten times a month, the fluid discharged being always clear like water. He says, I tapped him for hydrocele two years ago; the fluid was clear like urine, and its withdrawal was not followed by injection of any medicine.

May 18th, 1881.—The scrotum is large as a child's head; the penis is buried in it. The upper and anterior part is firm, like a forming elephantiasis; the lower and back part is covered with enormously dilated lymphatics, some of the ampullæ being as large as the tip of a finger.

7 p.m.—Pricked a scrotal vesicle; profuse discharge of clear watery lymph containing filariæ. Blood from the finger at 7 p.m. and at 9 p.m. carefully examined; yielded *no* filariæ.

19th, 6 a.m.—Blood again examined, but no filariæ found in it. A feeble clot had formed in last night's lymph. This by a little stirring was easily broken up, and then completely disappeared, leaving a scanty red sediment and some small white flocculi. Many fully-formed embryos could be found in every slide of sediment, and also ova containing active struggling embryos. The chorion or wall of the ovum could be easily made out when the activity of the embryo somewhat abated.

20th.—An assistant found a solitary embryo in this man's blood last night at 10 p.m. This morning, 6 a.m., none can be found. Examined several slides of sediment from lymph drawn on the 18th, and found the embryos still

Digitized by Google

the activity of its generative functions, the exposed position it often occupies in the legs or scrotum, its liability to injury, therefore, from mechanical violence, of the sicknesses of the host, his fever, and blood poisoning; the miscellaneous foods he consumes, some of which may act on the uterus of the worm as they act on that of the human subject, we can readily understand how this is brought about. We know the mature parasite[1] sometimes dies, what kills her may, applied in a less degree, readily cause her to abort.

Of course, it is impossible to prove in every case of lymphatic obstruction that this has been brought about by embolic ova. It *must* be a rare thing to see the patient at the proper time, yet if only once or twice we get the hint of the *modus operandi* it is readily appreciated and the effects comprehended.

alive, both those that were completely outstretched and those rolled up in ova, globular and oval. Found two ova in which the stretching process had been half completed; the embryos were still working vigorously, but about a third part of head or tail end had to be doubled up on the body, as the chorion was still too short to accommodate the fully-stretched embryo.

21st.—Scrotum removed; skin of penis preserved. Though the mass was carefully cut up and searched no parent worm was found. The tissues were much denser than usually obtains in lymph scrotum, and the bulk was greater than in pure examples of this disease. In fact, but for the vesicles and discharge, it was more like a case of ordinary elephantiasis. No lymph could be made to regurgitate by pressure on the inguinal glands.

June 17th.—Nearly healed; the blood has been examined almost every night but no more filariæ have been found in it.

[1] Bancroft removed one from a lymphatic abscess of the arms: the following are the notes of a case in my own practice:—A middle-aged Chinaman came to hospital in Amoy on the 7th January, 1881, suffering from a large, hard, brawny red swelling of the upper and inner aspect of the right thigh. The corresponding femoral glands were somewhat enlarged, but to the touch felt soft, and were not at all painful or inflamed; and he said his glands had enlarged years before the present swelling in the thigh. With a hypodermic syringe I extracted from them a few drops of milky lymph, though from want of leisure I did not examine this with the microscope. I concluded, there being no other reason apparent for the formation of an abscess in this particular situation, that it was caused by the death of the parent filaria. Accordingly I was prepared when, three days later matter had formed, to make a careful search of the contents of the abscess for remains of the parasite. By drawing a needle rapidly through some dark grumous clots which escaped with the pus, I succeeded in finding three or four fragments of the animal, one of which contained fully outstretched embryos, and others ova at an earlier stage of development. The abscess healed rapidly, but five weeks later embryos could be found in the man's blood and in lymph aspirated from the enlarged glands.

Digitized by Google

The particular form of lymphatic disease and the place affected will depend on the position occupied by the parent worm, on the number of immature ova she ejects, on the frequency with which these miscarriages are repeated, and on the nature of the tissues involved, and individual peculiarities and accidents.

Let any one, with a diagram of the lymphatics before him, in imagination locate an aborting female filaria in different situations, and follow out the course her embolic ova would take and the effect of stasis of lymph, complete or partial, on the different lymphatic areas—if he bears in mind the influence of gravitation and of inflammation readily induced in tissues whose vessels are congested, he will find that he has got a key to all the elephantoid diseases and the apparent anomalies of their connection with the filaria.

Suppose we locate her in the lymphatics of the right leg, her ova will be carried first to the right inguino-femoral glands. After these have been plugged more or less completely, anastomosis will carry the ova by the scrotal and neighbouring lymphatics to the inguinal glands of the left side, and when these in their turn have been effectually plugged, there must be complete stasis of lymph in both legs and in the scrotum. Perhaps the lymphatics of the latter, overstretched and varicose from having had to carry the lymph of the right leg, as well as that normally passing through them, give way, there is then a lymph scrotum produced, and in the fluid periodically escaping the young of the parasite or its ova may be found. Not having passed through any glands the lymph will be clear and straw coloured, as it is at the radicles. Perhaps the scrotal lymphatic, being strong and well supported by a powerful dartos and thick skin, may not give way; the lymph will then accumulate there, or gravitation may determine it to a leg or both legs; or all of these parts, as is not infrequently the case, may enlarge, and there being little or no circulation of lymph probably the parent will die.

If the worm is located in the scrotum much the same effects will ensue. But if she is in a lymphatic trunk of the pelvis or lumbar region, then, should the stasis caused by the ova involve the lymphatics of the kidneys, ureters, or bladder, chyluria may ensue. As the parasite in this case is probably betwixt two glands, and as the anastomosis of the vessel in which it lies is guarded in all directions by glands, it may be impossible, if all of these are

Digitized by Google

plugged, for embryos to get into the circulation. Generally, owing to the richness of the anastomosis, the plugging is not complete, and the parent survives; on the degree of obstruction will depend the presence or absence of embryos in the blood. In addition to producing more or less complete stasis in the particular region, such an accident among the lumbar or pelvic lymphatics must diminish the number of vessels available for the transmission of the lymph from legs and scrotum. Suppose the obstruction is on the left side, and is extensive, then there must ensue regurgitation through still unplugged glands, passage of lymph by anastomosis, either outside or inside the pelvis, to the right side, where perhaps alone lymph paths are open. These are not sufficient for all the fluid that is formed in those parts lying below the seat of obstruction, consequently there is increased pressure in the lymphatics of the legs and scrotum, and liability to elephantiasis or lymph scrotum. Should lymph scrotum result, then, as the lymph that escapes has passed through several glands, some of them possibly connected with the alimentary canal, it will be chylous, or even sanguineous.

When once there is permanent stasis of lymph in a part, or a lymphorrhagia is established, there is relief afforded to the remaining lymphatics implicated in the original area of obstruction; for the amount of lymph to be transmitted is less by the amount of that formerly sent from the seat of the developed elephantiasis or lymph scrotum. This explains why excision of a lymph scrotum is so frequently followed by elephantiasis of a leg or by chyluria. The lymph scrotum hitherto acted as a sort of safety valve.

The accumulation of a chylous fluid in the tunica vaginalis, called by Vidal "galactocele," is frequently associated with filariæ in the fluid and in the blood, and is explained by the parent parasite being located in the lymphatics of the cord, or by these participating in lymph stasis produced by obstruction in glands situated higher up the lymph circulation. The double enlargement of the inguinal glands in one-sided elephantiasis is also explained, so is the so-called metastasis of this disease.

And now my reasons for supposing I would find the parent filaria in the scrotum shown the Society can be understood. The lymph was clear, thin, and straw coloured, therefore there had been no regurgitation through the inguinal glands; and as no embryos could be found in the blood, therefore, those that appeared in the scrotal

Digitized by Google

lymph must have come from a parent on the distal side of the inguinal glands, possibly in the scrotum.

It is unnecessary to follow out the argument at greater length. Enough has been advanced to show in what way all the phenomena of elephantoid disease may be explained by the theory that the parent parasite is the prime cause, premature birth of the ovum the second, and infarction of the lymphatic glands by the ova the immediate cause.

The impossibility of permanent and thorough cure of elephantiasis is apparent. Much may be done by the knife to remove deformity, and elastic bandaging and other devices for aiding the lymphatics still patent, and the blood-vessels to carry off stagnant fluid, but permanent cure of the established disease is impossible.

The prospect on the side of prevention is much more hopeful; for if people in countries where the filaria is endemic would but cover their wells or water jars with a netting sufficiently fine to keep out the mosquitoes, or if they filtered or boiled their drinking water, they would never get filaria or the disease it produces—elephantiasis.

---

7. *Ainhum.*

By JONATHAN HUTCHINSON for A. CROMBIE, M.D., of Dacca, India.

WHAT has already been written by Dr. James Wise, formerly Civil Surgeon of Dacca, and myself, regarding the occurrence of "Ainhum," in Eastern Bengal, will be found in Appendix vii of Fox and Farquhar's 'Skin Diseases of India and Hot Climates,' published in 1876. No cases have been reported from other parts of India, but during the past three years I have met with five or six individuals affected with the disease at Dacca itself. In April, 1877, I found two of the prisoners confined in the Dacca Jail, 600 in number, to be suffering from it; and in April, 1879, one prisoner was affected. At the Dacca Mitford Hospital, where there is a daily average attendance of 125 out-patients, one or two cases occur annually. I mention these facts as an indication of the extent of prevalence of the disease amongst the population.

Digitized by Google

The disease, as it is seen in Eastern Bengal, differs from that which is described as affecting the African population in South America, inasmuch as it is not confined to the little toe. In a case which has been already published, and which was reported from Noakhally by Babu Udhoy Chand Datta, the fourth toe of the right foot and the fourth and fifth toes of the left foot were the toes affected. These specimens are now in the Pathological Museum at Calcutta.

The specimens which I now present to the Pathological Society of London are the fourth toes of a man from whose feet I removed them a few months ago at Dacca. In this case the fifth toes were not affected. In every other case which I have seen the little toe only was affected on one or both sides.

In my original description of the disease, I stated that the spontaneous amputation of the toe took place at the middle of the proximal phalanx. I was led to this conclusion by coming down on bone when attempting to remove the member with a knife at the point of constriction in less advanced cases. A committee of your Society, however, examined two specimens (from South America I presume), and found that the amputation had taken place at the proximal interphalangeal joint in both examples. It was some time before I had an opportunity of satisfying myself on this point, but one of the prisoners in the Dacca Jail, who was affected with the disease, dying suddenly from another cause, I was able to dissect the whole toe, and I found that the annular constriction had undoubtedly taken place opposite what had been the first interphalangeal joint, in accordance with the statement of the committee of your Society. The constriction of the skin was not very far advanced in this case, and did not altogether encircle the toe; but the distal half of the first phalanx, and the proximal half of the second, were already converted into fibrous tissue; and there was a break in the continuity of that fibrous tissue, evidently indicating what had been the first interphalangeal joint, and this was situated immediately below the deepest part of the cutaneous constriction. The toe affected was the left little toe.

In the two specimens which I now submit to the Society the disease is not far advanced. The process of conversion of the phalangeal bones into fibrous tissue has not yet commenced, but the constriction in the skin was well marked. In these cases the peripheral. It is clear from an examination of the fragments that

Digitized by Google

constriction is as undoubtedly opposite the middle of the first phalangeal bone as it was opposite the first phalangeal joint in the other case. The specimens have been in spirit for some months, and are somewhat shrunken, but this fact remains plainly visible, though at the time they were amputated the constriction was nearer the middle of the bones than now.

The conclusion which I draw from these cases and from my previous experience of the disease is that the constriction of the skin in ainhum, as it is seen in Eastern Bengal, occurs opposite either the middle of the first phalanx or the first interphalangeal joint. *December 21st*, 1880.

---

8. *Spontaneous disintegration of vesical calculi.*

By William Ord, M.D.

Within the last four years I have had the honour of bringing five cases of spontaneous disintegration of calculi within the bladder before this Society. By the kindness of Mr. Thomas Smith, of St. Bartholomew's Hospital, I have now the opportunity of describing a sixth case.

Mr. Smith has already published the history of the case in the 'Lancet,' vol. i, 1880, p. 34. Briefly, the fragments now exhibited, weighing altogether more than three ounces, were removed at two sittings by Bigelow's apparatus from a man aged 69. At the second sitting some stones were crushed. The urine before and after the operation was copious, of low specific gravity, 1·010, acid, and free from albumen. The stones consist, on chemical examination, chiefly of uric acid, with small quantities of calcium and magnesium, and a trace of ammonia and phosphoric acid. They number some thousands, and consist partly of little spheres varying in size from that of a mustard seed to that of a pea, but far more abundantly of fragments of laminæ, the largest of which would not correspond to anything larger than a bean. There are hardly any segments which contain centres of spheres; nearly all are

Digitized by Google

the bladder has contained a multitude of pisiform calculi which have become in some way broken. That they were mostly broken some time before their removal is evident from a closer inspection. A very considerable number of the fragments are water-worn, and rounded at their broken edges by mutual friction. And if a few be taken out at random it will be readily seen that while some, a small proportion, show fresh fractures with roughish surface and well-marked laminæ, the majority show a smooth surface, and the laminæ are more or less concealed by fresh unconformable deposit.

There can be then no doubt whatever of a large proportion of the stones having been broken up spontaneously some time before their removal.

The next point is to find out how the fracture came about. Mr. Smith in his description of the calculi adverts to an explanation offered by me in the case of certain calculi previously exhibited. These appeared to have been burst from within by swelling of the central portion. The explanation, however, does not appear to apply to the present specimens. They appear to have fallen to pieces from without, as calculi often do if rapidly dried. Many of the round calculi have fragments of laminæ adhering to them, sometimes with indication of successive peeling away. The substance of all the calculi (which are of a dirty white colour) is remarkably soft and feeble, but the perfect spheres are much harder under the saw than the laminar fragments, which can be easily reduced to powder by slight pressure, and are then seen under the microscope to consist of minute crystalline fragments. When these are acted on by liquor potassæ they dissolve, leaving scarcely any organic matter of their own. But an abundance of spores and mycelium of a fungus become apparent. The spores are partly oval-shaped, resembling the spores of yeast, partly minute and clustered like those of penicillium glaucum. The mycelium is mostly very delicate, and reticulated, with here and there a development of thalli. But there are some much larger filaments resembling those of Hassall's sugar fungus. The mycelium forms flat expansions which lie parallel to the laminæ. When I first saw the great abundance of large spores I though that the urine must have contained sugar. But the description of its state at the time of the removal of the calculi does not countenance this idea. Moreover, by the kindness of Mr. Smith, I had the opportunity of examining urine passed

Digitized by Google

subsequently and could find no sugar; nor, indeed, did fungi appear after it had been kept for some time. In all probability the fungus existing in the calculi is one formed in acid urine, such as that drawn by Dr. Beale in his work on 'Urinary Deposits,' 3rd edition, plate vii, fig. 49, opposite page 326. The crystalline and friable state of the calculi is, in my opinion, due to the fact that they contain so small a quantity of organic matter. It would be quite possible, according to the results of observation of crystalline matter deposited within colloids that they would be disintegrated after a certain time, by reason of changes proceeding within them. But the unusual presence of the large quantity of fungus and the stratified arrangement of the mycelium suggest that the breaking up of the calculi has been actually in part the work of this intruder.

May 3rd, 1881.

---

9. *Case of hemiatrophia facialis.* (*Living specimen.*)

By J. F. PAYNE, M.D.

[With Plate XXXII.]

THE patient who is the subject of this remarkable deformity is already well known to many physicians on the continent, and to some in this country. I shall not, therefore, attempt to give an exhaustive description of his case, but only refer to some of the more striking points.

Otto S—, aged 42, carpenter, German by birth, states that he enjoyed good health, and his face presented nothing abnormal till he was eight years old. At this time he suffered from measles, and after the attack a swelling appeared under the left lower jaw, which lasted fourteen weeks, but at length disappeared under the use of some inunction. A yellow stain or pigmentation is said to have remained. He states that this swelling grew downwards, and was as large as "an ostrich's egg."

From his account, though it is not perfectly clear, the swelling would appear to have been a glandular enlargement, but he states positively that there was no opening or discharge of matter.

Digitized by Google

Digitized by Google

Digitized by Google

UNIV. OF

DESCRIPTION OF PLATE XXXII.

Illustrating Dr. Payne's Case of Hemiatrophia Facialis.

Two photographs (reproduced in autotype) representing the right and left sides respectively of the patient's head and face.

The two portraits show the aged appearance of the left side and the comparatively youthful look of the right.

Digitized by Google

Digitized by Google

The teeth on the left side fell out after the swelling went away. Nothing else was noticed inside the mouth.

After this the left side of the face is said to have ceased to grow, and the disproportion between the two sides continued to increase for three or four years, since which time it has been stationary.

At present there is a marked inequality of size between the two sides of the face and head. I found the greatest circumference of the head over the hair to be 20¾ inches (·525 mètre), of which nearly 13 inches (·305 m.) represented the right half, and a little over 8¾ inches (·220 m.) the left half, as nearly as could be made out. All the bones of the left side are evidently smaller than the corresponding bones of the opposite side. This is very apparent in the frontal bones, the forehead being marked in the middle by a sort of ridge, to the left of which the left frontal bone slopes rapidly away. The left supraorbital ridge and the bones of the orbit generally are also in a marked degree smaller on the left side. The left ear is smaller than the right.

Still more remarkable than the actual difference in size is the contrast between the two sides of the face in general appearance. The right side, seen in profile (Pl. XXXII, fig. 1), is like the face of a man of forty, the left side (fig. 2) would be taken to be ten or twenty years older. This side has all the characters of an old face. The skin thin and wrinkled; the subcutaneous tissue wasted; the deep lines of age well marked. The left eyelid is thin; the eye deeply sunk in the socket; the arteries look very prominent, as in old and thin people, but are not hard or rigid. There is no perceptible difference in temperature or redness. He states that he perspires less on this side.

The hair on the left side is generally thinner than on right. Above the ear is a bald patch, but behind the ear it is thicker. The eyelashes are deficient in inner corner of eye.

The left half of the tongue is considerably smaller than the right. The tongue is protruded somewhat towards the left, but the entire absence of teeth on that side may partly account for that.

With regard to the special senses, the sight of the left eye is defective. Mr. Nettleship, who was kind enough to make an ophthalmoscopic examination for me, writes:—"The only eye changes I found were that the pupil of the diseased side was always the larger of the two, and that on one of the chief retinal veins

Digitized by Google

there was a very peculiar enlargement like an aneurism, on the dorsal side of which the vein was much larger than on the proximal (optic disc) side; but I did not have time to examine minutely into any other differences as to refraction and sight, &c." There is no apparent difference in the sensibility of the skin. The hearing is deficient in the left ear. A watch which was audible at a distance of eighteen inches from the right ear was only heard by the left at a distance of nine. Taste on the left side is deficient, so is smell in the left nostril, but patient asserts (what I had not an opportunity of precisely verifying) that any irritation causing sneezing is felt as well in the left as the right. The voice has never been altered, but complains of difficulty in articulation.

Remarks.—This case is especially interesting from its history. The man was seen by Romberg in 1847, and by Virchow in 1859; in later years by Professors Eulenburg, Charcot, and others. It is an example of the condition known as *Hemiatrophia facialis*, which some have thought should more properly be called *hemiaplasia*, since there is not so much wasting of the affected side as cessation of growth. But if we use the term atrophy in the sense it has generally acquired, for the result of a process, not for the process itself, it seems unobjectionable. It would seem that after the occurrences already related the left side of the face ceased to grow, or grew imperfectly from the time the patient was eight years of age. But to speak of the condition merely as arrest of growth or non-development would be most misleading; the affected side has no infantile characters, but shows premature senile decay.

Since the blood-vessels are uninjured, we must seek the explanation of the change in the nervous system, and might conclude that (if the patient's history is trustworthy) he suffered from a swelling which destroyed part of the nervous supply of the face. It might be suggested that perhaps the cervical sympathetic was severed, and that after the stage of hyperæmia a permanent condition of anæmia, and consequent atrophy, was induced. But the appearances in cases where the cervical sympathetic has been divided or destroyed are very different from those in this case. I will only refer to two cases, one reported by Dr. William Ogle in the 'Med.-Chir. Transactions' for 1869 (vol. lii, p. 151), and another by myself ('St. Thomas's Hospital Reports,' New Series, vol. iii, 1872, p. 171), a comparison of which with the present case would at once show marked differences. It is enough to say that in neither of those

Digitized by Google

cases was there any atrophy of the affected side, and that there was in both a derangement of the vascular supply, evident in conditions of excitement if not always. In this case atrophy is the marked feature, and there is no difference in the vascular supply. In short, an affection of the sympathetic alone would not explain the phenomena. But it is right to say that I do not know of any case of lesion of the sympathetic which forms a parallel to this in the fact of the lesion occur ing during growth and the individual surviving to adult life.

It only remains to refer the changes to some lesion of the fifth nerve. This lesion could not have been severance, or sensation would not have remained unimpaired, but it is not easy to say what it was. The man's account of the swelling in the jaw does not explain how the fifth nerve could be affected, but his description may be, and probably is, very inaccurate; and it is also possible that the swelling may have been a pure coincidence, and the nerve lesion quite independent of it. The distribution of the morbid changes is precisely that of the fifth nerve, and in all the similar cases of one-sided atrophy which have been observed the implication of this nerve has appeared clear. It seems impossible to doubt that this nerve is, in regard to the tissues it supplies, a "trophic nerve," and that there are certain conditions of it (not severance or destruction) which cause impairment of the nutrition of the parts. Whether this is due to sympathetic fibres contained in the fifth nerve, or fibres derived from a motor nerve, are physiological questions on which I do not venture to express an opinion.

The non-implication of the facial nerve is pretty clearly proved by the absence of any muscular paralysis.

It is worth while to compare this condition with the other morbid processes which occur in the distribution of the fifth nerve and appear to be due to some disturbance of innervation, these are herpes and morphœa. With herpes this condition evidently has nothing in common but its distribution; with morphœa there may be some distant analogy, but nothing more. Morphœa is an affection of the skin only, not simply atrophic, if atrophic at all, and often undergoes spontaneous healing. The condition seen here is purely atrophic, the skin has no resemblance whatever to the skin of morphœa, and it is a condition which is not conceivably alterable or susceptible of restoration.

It must remain for future physiological research to determine on

Digitized by Google

what normal or pathological mode of activity in the fifth nerve these changes depend.[1] *November 2nd*, 1880.

---

9. *Vesical calculi.* (*Card specimen.*)

Exhibited for SURGEON-MAJOR CURRAN by F. TAYLOR M.D.

A. Calculus presented to Dr. Curran by a native assistant surgeon in India, who stated it was passed by a female, aged 44, spontaneously and without much effort. It weighed 601 grains when passed, but now, after cutting, weighs only 478 grains. It measures 2¼ inches in length and 1¾ inches in breadth. The antecedents of the woman are not known.

B. Calculus taken from an old woman, in whose bladder it had been for many years; it had to be pushed back into that viscus before it could be extracted. It weighs in the dry state 768 grains. It is curved in shape, elongated, about 5 inches long, and 1 broad.

May 17th, 1881.

[1] This patient was seen when a boy of nine years old, in 1847, by Romberg, who described him in his 'Klinische Ergebnisse' (Berlin, 1851), p. 84. At that time there was a "yellowish-grey" pigmentation over great part of the affected side. The temperature and special senses, as well as common sensibility, were unaffected. The account then given of the origin of the atrophy differs somewhat from that given here. It would seem that the impairment of the special senses now seen in the patient must be a *result* of the atrophy.

Digitized by Google

X. SPECIMENS FROM THE LOWER ANIMALS.

1. *Vesical calculus from a dog.*

By Frederick Treves.

The bladder and stone exhibited were removed, *post-mortem*, from the body of a medium-sized Newfoundland dog, six years of age.

The animal had presented symptoms of stone for six months preceding his death. He was disinclined for any but slow and deliberate movements; was troubled with frequent micturition, and often with severe pain at the completion of the act. He appeared to experience some irritation at the end of the penis, and was very loth to have his hind quarters patted or even touched. He died with symptoms of uræmia; suppression of urine, convulsions, coma, &c.

Post-mortem.—The bladder was in a state of general acute cystitis, the mucous membrane being swollen, much injected, and covered with a good deal of recent lymph. It contained no trace of urine, and was indeed occupied *entirely* by the calculus around which it was very firmly contracted. In places the bladder-wall appeared adherent to the stone by flakes of lymph. The calculus was round and of regular outline. Its surface was minutely nodulated, and its diameter on section was two inches. It was of a fawn colour, and presented a radiating arrangement of the parts on the exposed surface of the section. Portions could be crumbled off by rough handling. It appeared to be composed of urates, and weighed a little over two ounces. The kidneys and other viscera were normal. *February 4th*, 1881.

Digitized by Google

2. *The kidneys of a boar pig, showing dilatation and atrophy consequent on disease of the vesiculæ seminales.*

Exhibited by JONATHAN HUTCHINSON.

THE kidneys exhibited were taken from a boar pig about fifteen months old. The animal had appeared to be in good health until three or four days before death, when the appetite failed and he became dull. He appeared to have some difficulty in making water but up to the day of death he voided considerable quantities. He sank rapidly and unexpectedly, and the precise mode of death was not observed. He had become stupid and heavy, and was probably comatose at last.

The bladder was distended by clear yellow urine (a couple of pints). The ureters were as large as small intestines, and both kidneys were in a state of advanced atrophy. The right organ was little more than a bag of fibrous tissue with scarcely a trace of renal structure remaining. The left was less advanced towards the same state. Neither of them was inflamed.

The vesiculæ seminales (large and much branched in the boar) were greatly swollen, constituting a soft mass the size of a small orange which pressed upon the neck of the bladder. I did not find any disease of the prostate or urethra, and my suspicion is that the swelling of the vesiculæ had induced pain in micturition and thus led to retention of urine and secondary distension of the ureters and kidneys. The *post mortem* was made hurriedly and under disadvantages. *January 4th*, 1881.

Digitized by Google

XI. DISCUSSION ON THE PATHOLOGY OF RICKETS.

On November 16th, December 7th and 16th, 1880.

Dr. C. HILTON FAGGE opened the discussion, as follows:—

IT is unpleasant on such an occasion to have to begin with anything like an apology; but unless I explain how I came to be here to-night, you, when you have heard me, will assuredly think that I have done very little justice to my task. On being asked by your Council to open a discussion on rickets I wrote, as I thought, to decline. I said that I had no new observations to offer; for although I have always felt a general interest in the subject, I have kept no notes of the cases which I have seen. But your secretary told me that what was needed was not so much a series of new facts, as a general statement of questions in regard to the disease which seemed most to require elucidation and discussion, and this I thought I could furnish to you. Other members of the Society, he assured me, had valuable observations on particular points to bring forward; and in offering to you the following remarks, I would disclaim for them any higher position than that of being simply introductory.

There are, I think, good reasons why the subject of rickets should now be taken up by this Society. One is, that in spite of the labours of Sir W. Jenner, and of many others, there is still too great a tendency to attribute to local causes the deformities caused by it, and to overlook the fact that these deformities belong to a general disease. Only a few weeks ago I heard a very eminent physician, in examining the body of a child who had died of broncho-pneumonia, speak of the pigeon-breast as if it were merely a result of the pulmonary affection. In that case there were at the wrists and ankles no obvious signs of a rachitic change. But a section

Digitized by Google

through the lower end of the tibia at once showed an abnormal state of the epiphysial line. Is it certain that a pigeon-breast is ever seen in a child whose bones are absolutely healthy? I should like to put this question to the Society, and to follow it with another—Does a rachitic thorax ever acquire the characteristic grooves on each side near the ends of the rib-cartilages without the intervention of some degree of bronchial catarrh? A very slight cough, lasting only a few days, may undoubtedly flatten the sides of the chest in a rachitic infant. But can this result be effected by the mere elasticity of healthy lungs?

The settlement of these questions, and of many others, is greatly retarded by the circumstance that during life it is impossible to determine absolutely the fact that rickets is not present in a slight degree. Even in a child not very fat I have more than once failed to detect any "beading" of the rib cartilages through the skin, notwithstanding that at the autopsy they were found to be diseased. And I may notice that the enlargement is often much more marked on the pleural side than towards the surface. On the other hand, there is naturally a slight elevation where the cartilages and the bones meet; and in thin children I have seen this mistaken for "beading," when in reality not the slightest rachitic change was present.

This difficulty as to the clinical recognition of rickets in certain cases is, I think, of great importance in regard to what will probably be the chief subject discussed here this evening—the relation, namely, between the disease and the recently discovered osseous lesions of inherited syphilis. M. Parrot, indeed, ignores rickets altogether. For him a rachitic change in a bone is merely a modification of the syphilitic affection, occurring only in children over six months of age, and attended with an enlargement of the extremities of the bone, and with the formation of a pearly-white osteophyte in its interior and on its surface. He would seem to be almost unacquainted with those histological characters which enable rachitic lesions of the bones to be traced from their very commencement. My friends, Dr. Barlow and Dr. Lees, of course, take up a very different position from this. But it has seemed to me that even they, in their observations, have been too ready to assume the absence of rickets when they found no obvious beading of ribs and no marked swelling of wrists or ankles. They do not appear to have been fully alive to the importance of slicing the

Digitized by Google

bones at an autopsy, and of examining their epiphysial lines, both with the naked eye and microscopically. Until this procedure shall have been systematically carried out in a sufficient number of cases, I think that it will still remain doubtful whether cranio-tabes is really related to syphilis rather than to rickets.

There is, however, another and somewhat different question, namely, whether syphilis may not be one of the causes of rickets. At first, when one is taught that inherited syphilis produces certain definite osseous lesions, one is naturally disposed to think that what has to be done is to draw a hard and fast line of distinction between these lesions and those due to rickets. But what we know of syphilis in adults surely points to a different conclusion. We know that besides producing an immense variety of affections peculiar to itself, it also acts as one of the two causes of the lardaceous change in the viscera. And many suppose it to be also a frequent cause of atheroma of arteries, and perhaps of phthisis.

The characteristic changes of rickets are far more obvious in fresh bones than in those which have been kept in spirit; but I have brought with me a few specimens which have been collected during the last few months, and which show the irregularity of the epiphysial line, the enormous increase in the breadth of the semi-transparent bluish zone of proliferating cartilage, &c.

I have already remarked that rickets is a general disease. The points which show that it is not confined to the osseous system are indeed such as singly might appear trivial, but taken together they possess considerable significance. I am not now referring to the visceral lesions described by Sir William Jenner, and afterwards by Dr. Dickinson, as affecting spleen and liver and lymphatic glands. I have failed to find these lesions in the great majority of rachitic children whose bodies have been examined, whereas I have found a large fleshy spleen in many children who have been free from rickets. And I am much disposed to agree with Dr. Gee, who, after stating that the appearance of the spleen in rickets generally differs in no respect from that which is seen after ague, or in inherited syphilis, adds that in his opinion the affection is really a result "not of the rickets, but of the general state of health which caused the rickets." This, however, is a matter on which valuable experience will no doubt be forthcoming in the course of the present discussion.

Nor can I attach much importance to the so-called "prodromata" of rickets—sickness, diarrhœa, tumefaction of the abdomen,

Digitized by Google

languor, drowsiness, &c. It seems to me that all of them are really either independent effects of the improper dieting and other conditions which give rise to rickets, or else themselves accessory causes of the disease. And it is certain that when one is called to a case of croup or of broncho-pneumonia one often has to deal with an advanced stage of rickets, although the child's mother may have thought it perfectly well up to the time when the acute illness began.

But there are three well-known symptoms of rickets which appear to have no connection with the osseous changes. One is a restlessness at night, which impels the child to throw off its bedclothes, even in cold weather. Another is the tendency for profuse perspiration to break out over the head, neck, and chest, especially during sleep. The third is the sensitiveness of all parts of the body to even gentle pressure. Dr. Gee has shown that this tenderness is by no means confined to the bones, and that the muscles of the loins or of the abdomen are sometimes no less painful when pressed upon, however cautiously.

There is one point in regard to the urine, on which I should be glad to elicit further information. Some months ago I was asked by Dr. Paddon of Putney, to see with him a rachitic boy, whose most obvious symptom was that he passed large quantities of uric-acid crystals. Such a circumstance is surely not common in a child. Since then I have met with another case in which I was told that the urine was extremely irritating and caused scalding pain during micturition. Can this have any bearing upon the supposed presence of lactic acid in the urine, which is certainly one of the points that needs further confirmation?

As to the state of the brain in rickets there are some discrepancies of opinion among different writers. The skull is obviously large, out of all proportion to the narrow face and stunted body. But Ritter von Rittershain showed by accurate comparative measurements that as a rule it is not bigger in rachitic children than in healthy children of the same ages. If so, a very improbable notion suggested by Trousseau falls to the ground—namely, that the softness of the cranium allows of the more easy development of the nervous centres, and that rachitic children consequently possess intellectual faculties in advance of their years. Surely it would be more reasonable to attribute the precocity of such children rather to their being thrown so much into the company of adults, and to

Digitized by Google

the contemplative habits induced by an unfitness for rough play and games. And Dr. Gee speaks of the brain as being dwarfed like all other structures, and describes an effusion of fluid within the cranial cavity to fill up a vacant space there. I should like to ask the Society whether it is certain that hydrocephalus is really a frequent complication of rickets, as all writers seem to say. It is at any rate certain that the skull is sometimes greatly increased in size, without there being any fluid in its interior. I well remember, although I have unfortunately no notes of, a case which I saw in the Evelina Hospital, and which was taken without question for one of very advanced hydrocephalus, until at the autopsy the brain was found to fill the cranial cavity completely. When a grown-up person has a rounded projecting forehead, as was the case with the novelist Thackeray, is the popular opinion correct that an hydrocephalus existed in infancy and has been recovered from? Might there not have been simply a rachitic state of the bones of the skull?

A curious complication of rickets, of which I have seen an example, is a chronic cerebritis. A child, eighteen months old, who had had frequent fits since the age of four months, was admitted into Guy's Hospital in a state of insensibility. It lay on its left side, and whenever it was moved into any other position its whole body became rigid, the mouth being affected with clonic spasms. It died in a few days, and the cerebral membranes, which themselves were thin and transparent, were found to be everywhere adherent to the surface of the brain, so that a thin superficial layer of the cortex peeled off with them. The white substance of the hemispheres was markedly indurated, and had a yellowish colour, and the limit between it and the cineritious matter was ill-defined. This was especially the case at the antero-lateral part of the brain on the right side.

But in many cases spasmodic affections occur without any change in the brain being discoverable. Of laryngismus stridulus, I believe that many observers say that it never occurs except in rachitic children. A year or two ago I had to examine the body of an infant, concerning whom all that I could learn was that it had died suddenly. The ribs showed the appearance characteristic of rickets, and this suggested to me that the cause of death was, perhaps, laryngismus, an idea which was afterwards confirmed by the mother's statement that it had suffered from that kind of disorder.

Digitized by Google

I have certainly seen one case of laryngismus in a little girl, whose general bodily configuration, although she had been brought up by hand, seemed at first to negative the idea that she could possibly be rachitic. But afterwards, when this child got an attack of bronchial catarrh, her ribs became for a time slightly flattened, and I began to think that her case might not really be an exception to the rule. Tetany is another affection that occurs chiefly in those who are the subjects of rickets.

Both the chemistry and the histology of rickets have been carefully studied, but with regard to each of them I think that there are still points open to discussion. The most recent analyses that I have met with are those which Friedleben made, and the results of which are recorded in the 'Jahrbuch für Kinderkrankheiten' for 1860. He found the percentage of earthy salts to be from 33 to 52, which is considerably higher than that obtained by earlier investigators, though it is of course much below the normal percentage of 63 to 65, yielded by the bones of healthy children. But it seems to me that we cannot too carefully guard ourselves against the supposition that any figures of this kind represent the actual composition of the osseous tissue itself, or even that they prove it to differ from the normal. No one can examine the microscopical specimens which I have brought to the meeting without seeing that in the bones from which they were taken, if dried and submitted to analysis, there would have been a large proportion of various other structures besides the osseous. Even within the bony trabeculæ themselves there are often to be seen very numerous and large islets of residual cartilage-matrix. Why the point is of importance is that, if there were in rickets a real alteration in the chemical constitution of the bones, affecting every particle of their substance, we could hardly doubt that the disease must exist at a very early period, if not from the first setting-in of the process of ossification within the fœtus. It does begin earlier than used to be supposed, being not unfrequent in children less than six months old. But whether it is ever present at birth seems to be very uncertain. Cases of fœtal rickets have been described by several observers; but all that is as yet known with regard to their histology leads to the conclusion that the lesion is altogether different from that with which we are now concerned.

The curvatures which arise in the shafts of the long bones in rickets show, of course, that these bones are throughout soft and

Digitized by Google

yielding. But it does not necessarily follow that the whole of their substance must be altered in composition. Their diminished resistance may fairly be ascribed to the preponderance of a light and spongy texture, not only in the parts formed since the commencement of the disease, but also in older parts, where it may well result from an over-activity of the absorptive processes which are always at work in their interior.

For there is in rickets one essential and characteristic histological change, which certainly is not diffused through the entire mass of the bones, but affects only their growing surfaces, when they join cartilages, or lie beneath periosteum. Indeed, it would be strictly accurate to say that rickets is not a disease of the osseous tissue at all, but of the soft tissues. Even the so-called "beading of the ribs" is really an enlargement of the costal ends of their cartilages rather than of the ribs themselves. I shall not attempt to describe to you the details of the remarkable morbid process which is observed, and of which I have a series of beautiful specimens, prepared for me by the kindness of my colleagues Mr. Symonds and Dr. Carrington. It is well known that the cartilage cells of the intermediate zone, instead of forming short vertical columns, which should be arranged with much regularity side by side, multiply, so that they become converted into rounded masses of enormous size, some of which bulge towards the cartilage, while others dip and extend far into the bone. The cells themselves have an abnormal appearance, which is aptly indicated by the epithet "dropsical" applied to them in a recent paper by Klebs. Rindfleisch defines rickets as depending upon an acceleration of the changes which usher in and prepare the way for the formation of bone, without the actual ossification keeping pace with them; but, in regard to this, I doubt whether the amount of proliferation which must normally take place has been sufficiently appreciated. It seems clear that for a long bone to increase in length, so much as it does from childhood onwards, there must be a far more abundant multiplication of the cells at each epiphysial line than would be indicated by the short columns which are are visible at any one time. It may be, after all, that what takes place in rickets is not so much an excessive as an irregular and perverted process of growth. I must also remark that the formation of the so-called "cartilage bone," the occurrence of "provisional calcification" of cartilage-cells, has appeared to me a much less prominent feature of

Digitized by Google

rickets during its active stage than I should have expected from the accounts given by writers on morbid histology.

With regard to the origin of rickets, it is perhaps worth while to allude briefly to a recent revival of the old "lactic-acid" theory. Wegner, of Berlin, showed in 1871 that if, while administering minute doses of phosphorus to young animals, he withheld lime salts from their food, there arose an affection of the bones exactly like rickets. He supposed that the phosphorus acted as a stimulant to the ossifying tissue. Heitzmann has since stated that lactic acid is capable of acting in a similar way. The hypothesis, therefore, as it has been promulgated by Senator, is that the disease is the result of an irritant action upon the growing bones of that acid (which is thought to be formed in the alimentary canal in excess from milk or other articles of food), there being at the same time a deficiency of phosphate of lime, consequent either on its being ingested in too small quantity, or on its being carried away through the bowels by diarrhœa. The weak point in this speculation is, of course, the circumstance that no excessive formation of lactic acid has been proved to occur.

As to the cause of rickets, again, there are a great variety of opinions; but I think not very many accurately determined facts. In this country the prevailing doctrine is that improper feeding of infants is the chief, if not the sole cause. But among Germans it is interesting to notice that Vogel, in the last edition of his work, says not a word about the possible influence of diet, and insists on defective ventilation—the want of fresh air—as the most important factor in the etiology of the disease. And of ourselves there are some who think that it is especially apt to be caused by farinaceous food, such as potatoes, when given too early; others attribute it mainly to a premature deprival of the natural food of a baby—its mother's milk.

Most English observers doubt whether rickets is capable of direct hereditary transmission. If it occurs in the children of a rachitic parent, they think that in each generation the hygienic influences have been adverse. But Vogel says he knows many families in which, the parents showing distinct signs of having been formerly affected, the children have all become rachitic in turn, in spite of every precaution. Sir William Jenner has expressed a doubt whether impairment of a father's health has any tendency to induce rickets in his offspring; whereas Ritter von Rittershain thought

Digitized by Google

that he traced it to the presence of tuberculous disease in the father more often than in the mother. But, among the poor, how are we to say what links there may have been between the supposed cause and the effect? The illness of a labouring man may deprive his wife of nourishment, throw heavy work upon her, and in many different ways render her likely to bear weakly infants; it may prevent the children from receiving proper food, may interfere with their being taken out into the open air, may confine them in small and cramped rooms, and may limit their supply of warm clothes.

A point on which Sir William Jenner has laid great stress is that the first child of a family, or even the first two or three children, are often found free from rickets, when later ones are affected with the disease; and, again, that when a woman has once had a rachitic infant, those that follow are almost sure to suffer. But this may be due either to the progressive enfeeblement of the mother's health by repeated child-bearing, or (among the poor) to the overcrowding and deficient food and clothing which are implied by a large family; while even children of the better classes are often kept too much indoors, when there is only one nursemaid for several of them.

The only conclusion seems to me to be, that the conditions of life are too complex, and too little capable of being isolated from one another, to allow of a separate study of their effects. Hitherto it has not been possible to trace rickets to any one special exciting cause; but, on the other hand, we are surely not justified in saying that no such cause exists.

It is clear that if rickets can be set up by feeding a child improperly, or by any other unfavorable conditions of life, it is not, in a strict sense, a diathesis. Thus one can no longer, with Sir William Jenner, set forth a contrast between it and other diathetic conditions. But its relation towards tuberculosis is a question of great interest and well deserves further elucidation. Dr. Eustace Smith, while doubting the diathetic character of rickets, remarks that it "never occurs in children in whom the tubercular disposition is well marked." At first this appears a striking statement, but it loses all its significance when we remember what are supposed to be the signs of a tubercular disposition; since for a rhachitic child to present them would be almost a contradiction in terms. And it would seem that it must be impossible to uphold Sir William Jenner's distinctions between scrofulosis and tuberculosis, now that so many pathologists find grounds for maintaining that cheesy glands and

Digitized by Google

chronic joint and bone diseases commonly form the starting point of an infective tuberculosis. For my own part, I must confess that I doubt whether any special configuration of body carries with it a *positive* tuberculous tendency. It seems to me that the only character presented in common by the majority of phthisical and scrofulous individuals is a *negative* one—namely, the absence of a perfectly robust and vigorous frame. In whatever direction the body deviates from the highest standard of health, except as the result of the actual presence of some other disease, I believe that the liability to tuberculosis is increased. If so, however, one would certainly expect that rachitic children should often be tuberculous. Sir William Jenner, indeed, himself states that rickets does not by any means exclude tubercle, and I have lately met with a case in which both diseases were present in the same infant. As regards family tendencies to tubercle in those who are the subjects of rickets, Ritter von Rittershain proved that a large proportion of the fathers of rachitic children were tuberculous, whereas Sir William Jenner alludes to a table made for him by Dr. Edwards, which appeared to show that the offspring of phthisical parents were actually less likely than those of non-phthisical parents to become affected with rickets.

In conclusion, I would urge as slight additional incentives to the study of rickets by English physicians, its great frequency amongst us, and the fact that one of the traditional names for it is *morbus Anglicus*. The suggestion was even once made that it originally spread from this country to the Continent; but the name in question probably had its origin in the title of a treatise said to have been published by Whistler at Leyden in 1684, 'De Morbo Puerili Anglorum.' The term rachitis was first proposed by Dr. Glisson, of Cambridge. One can hardly doubt that he really adopted it on account of its similarity in sound to the word rickets, which was a popular name for the disease in the west of England, where it seems to have been first recognised. But Glisson, in his work on the subject, offers to his readers the choice of a Greek root, ῥαχις, on the ground that the spine is one of the first parts to be attacked! It has probably seldom happened that the fabricator of a scientific appellation has thus himself made apparent the weakness and inaccuracy of its etymology. But I have but little doubt there are many other terms which, having been made, instead of growing spontaneously, have no better origin; and, if so, what can be more

Digitized by Google

futile than to spend time and labour in searching out for such bastards a legitimate pedigree to which they really have no claim ?

DAVID B. LEES, M.D., and THOMAS BARLOW, M.D., read a paper on the *Relationship of Craniotabes to Rickets and Congenital Syphilis*.—In the year 1843, Dr. Elsässer, of Neuenstadt, in Germany, published a pamphlet of 200 pages, entitled "Der weiche Hinterkopf," in which he drew attention to a symptom which he had discovered in many infants, and which had not been previously described. This symptom consisted in an abnormal thinness of portions of the parietal and occipital bones, causing them to yield to moderate pressure, and to impart to a finger pressed upon them a sensation like that derived from stiff parchment or from the surface of a bladder. He investigated this symptom very carefully, both from a clinical and from a pathological point of view. He found it to exist in greater or smaller amount in a large number of the infants brought to him for advice. In his treatise he published a narrative of thirty-one cases which he had personally observed, with an account of the *post mortem* appearances in eleven instances. He discussed at considerable length the nature and affinities of this condition, and concluded that it was essentially of the nature of rickets. He came to this conclusion for two reasons, arguing firstly from the softening of bone, and secondly from the fact that some of his patients who survived the craniotabes, became afterwards undoubtedly rickety.

This opinion has been fully accepted by subsequent German writers, especially by Vogel and Steiner. Gerhardt considers all well-marked cases as rickety, but quotes some observations by Friedleben to prove that craniotabes may occur in very young, apparently healthy children, and concludes that these cases are not rickety, though he does not offer any other explanation of them. Friedleben indeed considers that craniotabes is a normal condition during the latter half of the first year of life, and maintains that it also occurs in animals. He confesses, however, that it is more marked in children brought up by hand than in those which have been suckled.[1]

West in England, and Meigs and Pepper in America accept Elsässer's observations and conclusions.

The time, however, seems now to have come for a fresh investiga-

[1] Gerhardt, 'Lehrbuch der Kinderkrankheiten,' p. 184. See also the article on "Rickets," by Dr. Rehn, in Gerhardt's 'Handbuch der Kinderkrankheiten.'

Digitized by Google

tion of this symptom, and for enquiry whether the idea that it is the first sign of rickets, is or is not correct. There is now no doubt that some symptoms occurring in the first year of life which have been ascribed to rickets are really due to congenital syphilis. The labours of Wegner, Parrot, Taylor, and others on the subject of the bone-lesions in congenital syphilis have opened up a new field of clinical observation and demonstrated important facts. Especially the lectures and *post-mortem* specimens of M. Parrot have taught us much about the syphilitic affections of the skull in young children, and we are now familiar in out-patient practice with the firm rounded bossy swellings, passing by and by into a uniform thickening of the skull, which characterise this condition. Of the reality of the syphilitic nature of these there can now be no manner of doubt.

Whilst investigating these cases we found that in some of them there were soft spots on the parietal bones, which seemed to us then a rather rare phenomenon. The question arose whether the craniotabes was to any extent owing to the syphilis, and this prompted the investigation, the results of which we now lay before the Society.

We soon found that the symptom was one quite common amongst the children of the poor, of less than one year of age. We were easily able to collect a hundred cases, which we have investigated as carefully as was in our power. The enquiry into the history and symptoms of the second fifty cases was made more precise by the use of printed forms. These directed attention (1st) to the maternal history, especially as to syphilitic symptoms in the mother (which are rare), to previous miscarriages, or stillborn or premature children; (2nd) to a history of snuffles or rash in other children, and to any symptoms actually observed by us in them; (3rd), to the history of the child suffering from craniotabes, including syphilitic symptoms and those usually deemed rickety; (4th), to its weight and age, with an account of the way in which it had been fed; (5th), to its present symptoms in detail as observed by us, especially the state of the skin, mouth, nose, voice, skull, thorax, long bones, and viscera, particularly the liver and spleen.

The results of these enquiries we have tabulated and classified, dividing the cases into those in which the craniotabes was marked (either extensive in area or extremely soft in one or two places), and those in which it was slight.

We further subdivided the cases into those in which the exist-

Digitized by Google

ence of syphilis was to our judgment demonstrated, those in which there were some indications of syphilis, but not sufficient to make the diagnosis certain, and those in which no evidence of syphilis could be discovered. It is right that we should here briefly point out the principles which have guided us in estimating the evidence of congenital syphilis.

1st. While we have in no case accepted a history of rash and snuffles as sufficient evidence of the existence of syphilis without some characteristic symptoms in the child itself, we have considered that such history is an important part of the evidence if any characteristic symptoms are present.

2nd. A syphilitic rash is not often observed at the period when craniotabes can be first detected. The rash is usually a past event, occupying some part of the period from birth to four months of age, whilst craniotabes is not often found before three months of age, and may persist till ten or twelve months or possibly longer.

In estimating the history of a rash, it should be remembered that a true syphilitic eruption is at times slight in extent and brief in duration, and that a mother is often unwilling to admit that her child has suffered from any affection of the skin. Absence of history of a rash has therefore not been considered by us decisive against the existence of syphilis. Special weight has been assigned to the history of a rash which was dry in character, and which extended from the buttocks along the thighs to the popliteal spaces or perhaps even to the heels, and particularly if the palms and soles were affected. On the other hand, in endeavouring to judge of the character of a rash from the history alone, there is of course the great difficulty of eliminating eruptions solely due to fæcal irritation. This difficulty is increased by the fact that the site and character of a true specific eruption is very often determined by the presence of some form of local irritation.

3rd. Chronic snuffling has appeared to us one of the most reliable signs. Any child may, doubtless, snuffle for a time, but if it continue to do so for several months, especially if the snuffling commenced soon after birth, syphilis is probably the cause. The probability is increased if there be muco-purulent or perhaps blood stained discharge from the nostrils. Snuffling is especially apt to recur in syphilitic children under the influence of slight catarrhs.[1]

[1] A similar observation may be made with reference to the hoarseness caused by the affection of the larynx occasionally produced by congenital syphilis.

Digitized by Google

Collapse of the bridge of the nose is a symptom which often accompanies snuffling; it varies in amount from a condition approaching flatness to one so very slight that its existence is questionable.

4th. Evidence of syphilis in the parents is not often obtainable among the out-patients of a hospital for children. The father is seldom accessible, and it is well known that a mother may bear syphilitic children without showing signs of the disease herself.

5th. Enlargement of the spleen in the early months of life justifies a strong suspicion of syphilis. This symptom was pointed out by Dr. Gee some time ago, but the value of it is as yet, perhaps, hardly sufficiently appreciated.

6th. The *post-mortem* discovery of osteophytic changes in the bones of the skull is, we believe, distinct proof of syphilis. Such changes consist in the development of a very thin layer of morbid bone, overlying the external surface of the skull in variable extent, or of localised solid swellings, which are usually lenticular, unless they are situated in the neighbourhood of a suture, in which case they are apt to become broad, sinuous bands. The spots of craniotabes often occur in the midst of the thin diffuse osteophytic bone above described, which, we may add, is always softer than normal bone.

7th. Rapid improvement under the free use of mercury, especially when non-mercurial treatment has been tried without benefit, may be accepted as strong confirmation of the existence of inherited syphilis.

8th. A suspicion of syphilis may be fairly entertained with regard to children who have always been suckled, and who have not suffered from vomiting or diarrhœa, yet who do not thrive, but fall into a condition of marasmus. If at the same time the spleen is enlarged, such suspicion is greatly strengthened. If improvement rapidly follows the use of mercury the diagnosis is almost certain.

We have not in this paper given a minute description of the morbid anatomy of craniotabes. This has been admirably done by Elsässer himself. We may, however, refer to specimens already exhibited by us to this Society, and described in the thirtieth and thirty-first volumes of the 'Transactions.' We are now simply discussing the relationship (if any) which the craniotabes bears to rickets and to congenital syphilis.

Among the 100 cases tabulated seventy showed a marked degree

Digitized by Google

of craniotabes, thirty only a slight degree. After weighing the evidence of syphilis with regard to each, we have come to the conclusion that in forty-seven cases we were satisfied of its existence. We believe that this verdict cannot be challenged in more than six or seven instances. Of these forty-seven cases thirty-five showed marked craniotabes, twelve only slight. Hence, as far as our observations are concerned, we conclude that 50 per cent. of the children who exhibit obvious craniotabes, and 40 per cent. of those in whom this condition is less prominent, or 47 per cent. of the total number of cases, are almost certainly syphilitic.

It is very likely that many of the cases which we placed under the heading of "Syphilis more or less probable" were really syphilitic, although we could not obtain absolutely decisive evidence. And it is by no means certain that even those in which we could find no evidence may not have been really syphilitic, for in one or two instances, in which syphilis in the parents was certain, the child showed no signs of it, unless marasmus and craniotabes be accepted as such, nor were any other morbid symptoms to be demonstrated *post mortem*.[1]

Occasionally craniotabes seems to be the latest relic of a vanishing syphilitic dyscrasia. Thus, one family history is as follows:—The first child was stillborn. Then came a miscarriage at fourteen weeks. The second child snuffled, and had "thrush" in her mouth, and a rash about the genitals before she was a month old. The rash was very severe and obstinate, lasting three months. The third child did not snuffle, but had "thrush" in the mouth, and a rash which lasted only two months, and was less severe than her sister's. The fourth child had neither snuffling nor rash, and was brought to the hospital simply on account of constipation. He had been suckled, and was firm of flesh, weighing seventeen pounds at four months of age; nevertheless, he had extensive craniotabes in both parietal bones—in some places quite soft. No other sign of syphilis could be found, except very slight snuffling, and there were no signs of rickets, except very slight beading of the ribs, such as seems, indeed, to be really physiological, and not morbid.

[1] We have lately seen a child of two years old which had typical condylomata around the anus, but which had not suffered from any other symptom of congenital syphilis, as far as could be ascertained by careful questioning of the mother. It is not unusual to find no other syphilitic symptom contemporaneous with condylomata, but in this case the history also was entirely negative.

Digitized by Google

Another case may be mentioned. A girl of 17 months old was brought as an out-patient, on account of vomiting and marasmus. She was observed to have large cranial bosses. Hearing that the mother had a baby 4 months old we requested her to bring it for inspection, fully expecting to find that it had craniotabes. It was brought the next week, and was found to be a very well-nourished and healthy-looking infant. It had been suckled exclusively, and had never had a day's illness. Nevertheless, it had extensive craniotabes on both parietals.

Elsässer himself had noticed that craniotabes is apt to occur in two or more children of the same family, and we have verified his observation.

The cases just cited demonstrate an additional fact, namely, that craniotabes is not simply a condition of marasmus.

In further proof of this we would submit the following tables :[1]

I. *List of well-nourished children with marked craniotabes.*

No. in List.	Age.	Weight.
11	4 months	14 pounds.
13	5 „	15 „
46	3½ „	13½ „
70	4 „	17 „
79	6 „	17½ „
83	4¾ „	13 „
88	2¾ „	11½ „

It must be remarked that all but the last one of these were brought up at the breast, and had hardly any other food.

[1] The remaining tables referred to will be found at the end of the discussion on rickets.

Digitized by Google

II. *Table of marasmic children in whom no craniotabes existed, and who were probably not syphilitic.*

Name.	Age.	Weight.
Florence Jacobi	6 months	9½ pounds.
William Merrick	13 „	9½ „
Henry Broome	3½ „	8½ „
Mabel Lodge	6 „	6½ „
Edward Macmahon	5 „	8½ „
Robert Warner	2¾ „	6 „
Ada Linderson	6 „	4¾ „
Emily Hope	6 „	6½ „
Ernest Morgan	2 years 7 „	12½ „

The last on the list was the subject of congenital heart disease. The others had suffered either from diarrhœa or vomiting, or showed signs of tubercle.

The children whom we have reason to believe syphilitic, yet who had not craniotabes, have mostly been under three months of age or over ten months; that is to say they have been outside the usual craniotabetic period. Some, in whom the absence of craniotabes at an early period of life was noted, afterwards developed it.

We conclude from these facts that craniotabes is not simply a part of a general marasmus. Elsässer himself observed the occurrence of the symptom in firm-fleshed breast-fed children. He seems to have been much puzzled to reconcile this fact with his theory of a certain weakly constitution, which a slight bronchial or intestinal catarrh could precipitate into a softening of the skull, and was driven to invent the rather amusing hypothesis that in these plump infants there is really too much fat, and that the bone, too marrowy, softens and perishes from very juiciness.

Our conclusion is that syphilis is by far the largest factor in the causation of craniotabes. Whether it is its sole cause can only be determined certainly by the examination of a large number of infants, in whose case the question of syphilis can be absolutely excluded. At all events, our observations show that the existence of marked craniotabes must be regarded as affording strong ground for suspecting the existence of a syphilitic taint.

Passing now to the asserted relationship of craniotabes to rickets, we have endeavoured to obtain evidence as to the truth or falsity of this relation by tabulating the rickety symptoms (if any) observed in all the cases of craniotabes of which we had sufficiently accurate

Digitized by Google

details. These are fifty-three in number, and are arranged in order of age, from two to nineteen months old.

It will be noticed that all the cases in the latter part of this table were found to have some, though in several instances very slight, signs of rickets. It might rashly be inferred from this that Elsässer's idea was thus confirmed, and that craniotabes is really the first sign of rickets; but such a conclusion should not be accepted without careful inquiry as to how the children had been fed.

Of the thirty-five infants in this table, of not more than six months old, eleven had been brought up exclusively at the breast. Not one of these showed any evidence of rickets whatever. A twelfth was almost exclusively suckled, though; in him the signs of rickets were "almost *nil*." Fourteen had been partly suckled and partly fed by hand: nine suckled for less than one month, or not at all. Nine of the former fourteen, six of the latter nine, showed distinct signs of commencing rickets.

Of the fifteen children in this table of more than six months old five were still partially suckled at the time that their craniotabes was noted. Of these one showed very slight signs of rickets, one slight signs, and three a moderate amount.

But of the nine who had been suckled for less than six weeks two showed slight signs, three a moderate amount, and four a marked degree of rickets.

We submit that these facts tend, so far as they go, to show that the rickety manifestations bear some definite relation to the diet.

The fact, therefore, that all our older cases of craniotabes showed some signs of rickets, less or more, does not itself prove the truth of Elsässer's idea, for they were all more or less improperly fed. And a syphilitic child may be expected to be at least as liable to injury from a faulty diet as a child free from this taint. Even if it could be proved that craniotabes is the first sign of rickets that would, of course, in no way invalidate proof that craniotabes is itself the result of syphilis. The only conclusion would be that syphilitic children are specially apt to become rickety. Whether this is so or not is uncertain. For ourselves, we must confess that if craniotabes and early enlargement of spleen be removed from the category of rickety symptoms we have as yet no proof that syphilis *per se* is a cause of rickets.

Dr. CRISP.—Before I speak of this disease, rickets, in the lower

Digitized by Google

animals I will say a few words respecting the affection in the human subject. Like all men in long practice (both private and dispensary) I have seen many cases of rickets; have often assisted in bringing these unfortunate children into the world; have known the history of the parents and their method of rearing their children. The Registrar-General's reports unfortunately furnish but a slight clue as to the mortality from this disease or as to its greater prevalence in certain localities. As every body knows, where the population is dense, the parents unhealthy, the air impure, the children badly fed and cared for, there the disease most prevails, but it is not by any means confined to the poorer classes; I have seen many cases among the well-to-do population, and the *quality* of the food in many instances has, I think, more to do with the production of the disease than the *quantity*. Mothers and servants often supply infants of tender age with food scarcely suitable for a child three years old, and among the lower classes in large towns the pewter pot and the gin bottle often furnish a poison that saps the very springs of life, as instanced by the enormous mortality among children under five years of age. The lower domestic animals are better cared for, and are supplied with more natural food, and hence they are less subject to this disease than the human species. I trust that I may be excused for briefly alluding to a case that came under my care a few years since. I attended the children from their infancy, and had known the parents (both healthy) for many years.

The father, a well-to-do cheesemonger and poulterer, took a large shop in London, his children at this time being in tolerable health. The sitting room where the children were generally kept was behind the shop, and the room six feet above the level of the shop floor. About a dozen gas lights supplied the shop, and the atmosphere of the room above was fulsome and oppressive for several hours of the day. In the course of two or three years one of the children died of tubercular peritonitis, another of brain tubercle and chronic hydrocephalus (as verified in each case by post-mortem examination), and a third and younger child at an early age had rickets in its severest form, but removal to the country probably saved her life, although she is now very delicate and much deformed. In these examples there was no stint as regards food; the children, as in many instances of rickets, were *over fed*.

I especially mention these cases, and I could greatly multiply the examples to show that the same cause may produce different dis-

Digitized by Google

eases, and that there is no special or peculiar cause for the production of rickets. It is said by most writers that the etiology of this disease is obscure; I fail to see the obscurity, and think that the cause of this disease is better known than that of most other maladies.

I make no apology for introducing what some may consider a digression at a pathological society, but I fear if we confine this discussion to the *pathology* simply the debate will be of a very limited character.

I now proceed to a consideration of the disease in the lower animals. It is a remarkable fact that not one of our writers on veterinary medicine that I am acquainted with have mentioned rickets in the lower animals. Youatt, Gamgee, Williams, and Fleming have all passed it unnoticed. I believe, however, that there is not a vertebrate animal that if placed under certain conditions may not be affected with it; in some, perhaps, in a modified form. For reasons probably (before named) it is much less prevalent than in the human subject. Our 'Transactions' contain but few records; Dr. Charles Dick in vols. xiv, 1863 and vol. xviii, 1867, describes it in two Italian greyhounds, part of the skeleton of one of which he exhibited. He came to the conclusion "that the disease was only found in those animals that lived on animal food chemically rich in phosphorus," a hasty inference, as my subsequent remarks will show. In 1876, as recorded in vol. xxvii of our 'Transactions,' I exhibited the bones of several young pheasants (some of which I had alive) affected with rickets; the birds were confined in a small space, did not get their natural food, and hence the softening, enlargement, and distortion in many of their bones. London bred poultry that are generally inadequately supplied with proper food and air often have a deficiency of phosphate of lime in their bones, as shown by their sterna, which readily bend, and remain distorted. As mentioned in my former communication, a young ostrich at the Regent's Park Gardens had its bones so deficient in phosphate of lime that its ribs fell in, and it died instantly. At these gardens a great number of young lions have been born, none of them have reached adult age, and nearly all die. I had an opportunity of examining several of them after death, some had enlarged thyroids, others had soft and deformed bones. Mr. Bartlett, the intelligent superintendent of the Gardens, attributes the mortality to the unsuitable situation in which the animals are placed (clayey soil and cold locality). In private menageries, where the animals are

Digitized by Google

moved about from place to place, a great many lions have reached maturity.

Among young dogs, especially large heavy dogs fed on great quantities of animal and vegetable food, rickets is not infrequent. Lambs, especially in cold, bleak situations, are sometimes affected with this disease. Mr. Wallace, of Twiglus, Lockerbie, Scotland, a very intelligent agriculturalist, writes me: "I have seen the rickety state you describe in foals not getting sufficient milk, or if the mother was being worked. I have also seen it in lambs in bad seasons when milk is scarce. Cold aggravates it: the joints thicken and swell, and the animal dies after lingering awhile, or it becomes useless."

Another disease in lambs soon after birth is lameness, with pain and swelling of the knee and hip-joints, many die in two or three weeks, those that recover have the joints enlarged and the legs distorted. Hurtrel d'Arboval, in the article "Rachitisme," in the '*Dictionnaire de Médecine Vétérinaire*,' says it is less rare in young beasts, calves, in cold moist countries, than in the horse, especially where they have impure air and bad food. These animals eat much, have large stomachs, deformed chests, diarrhœa, slow dentition, and often die before they reach adult age. Thomas has seen the disease in the hog.

I could adduce further evidence of the existence of this disease in the lower animals, but I have said enough, I hope, to show that if, as in children, they are placed under similar circumstances as regards air and food nearly the same morbid changes follow, viz. impaired digestion, softening of bones, enlargement of the ends, deficiency or maldistribution of the lime salts, weakness, distortion, and other symptoms so well known to attend rickets in the human subject.

As regards experiments upon the lower animals to produce rickets, many have been performed. Guérin fed young puppies on flesh and produced rickets. Heitzmann, finding lactic acid in the urine of rickety animals, fed them with this acid and injected it under the skin; rickets followed in some, but is it not unlikely that any extraneous matter introduced into the system, by lowering the vital powers and interfering with the proper assimilation of the food, would favour the production of this disease?

Dr. Norman Moore.—Dr. Fagge has alluded to the first accounts of rickets, and has spoken of Whistler as its discoverer, but to this

Digitized by Google

honour he has no right. The claim rests only on the assertion of Whistler that he printed a thesis on what he called Pædosplanchnosteocace in 1645, but there is no trace of this thesis, and in face of the fact that Whistler was a dishonorable man who appropriated to his own use some of the funds of the College of Physicians while he held office as President, his own unsupported statement is of small value. Glisson is known to have been at work on rickets in 1645, and he published his work on it in 1650, a book which marks the dawn of medicine after the darkness of the middle ages. One development of rickets I think has been overlooked, a heaping up of bone at the edges of the vertebral centra which I have observed in a majority of cases. It is sometimes considerable when the beads on the ribs are small and it leaves a permanent deformity, which is liable to be confounded with the results of rheumatoid disease. To ascertain the condition of the bones in rickets I calcined in a platinum crucible equal portions of two rickety ribs, and of two healthy ribs, all four from children under two years of age, and found the quantity of earthy residue as near as possible the same, so that I am inclined to believe that the quantity of earthy salts in rickety bones is often but slightly if at all diminished. Dr. Fagge asked if a pigeon breast is ever found in the absence of rickets. I can give an example. On May 2nd, I examined minutely, a child, aged five, in whom whooping-cough was commencing; her chest was of normal shape, and she had no symptom of rickets; the cough was severe. On August 13th she had a distinct pigeon breast.

Mr. Warrington Haward.—In dissertations and discussions upon rickets it has been usual to lay great stress upon the bone changes which accompany the disease, and this is very natural and proper when it is considered how large a part they play in the disease and in the production of its most obvious symptoms. Dr. H. Fagge, however, pointed out at the commencement of his remarks that rickets was a general disease, of which the bone lesions are but a part. I would go further, and say that the bone changes are not always a prominent part of rickets, and that he who looks only for these signs of the disease will fail to recognise some of the most severe cases. It may be useful, therefore, to recall attention to the condition of some of the other organs, especially the muscles and ligaments. Rickets may be described as a special form of debility

Digitized by Google

the stress of which falls upon the organs of motion—the muscles, ligaments, and bones. A *special* form of debility because it has concomitants which distinguish it from all others, and make rickets a very definite disease. I allude, of course, to the marked tendency to certain convulsive affections, which is so great as always to bring rickets to our minds if we see a child, who has no marked fever, attacked by fits or laryngismus; to the singular sweating about the head and upper part of the body; to the extreme tenderness, and often to the great fatness of the children, which last symptoms make it less easy to detect what would otherwise be more often noticed—the enlargement of the viscera, and the slight induration and enlargement of the lymphatic glands. With these symptoms are seen certain changes in the apparatus of motion, among which is a notable weakness of the muscles and ligaments. If a child who has walked becomes rickety one of the earliest symptoms is an unsteadiness of gait, soon followed by an inability to walk. The mother says, "The child is taken off its feet." This inability to walk is not because of the changes in the bone, which are probably coincident, but because of the muscular weakness, which shows itself in other ways—*e.g.*, the bowed spine of rickets depends upon the weakness of the spinal muscles, which are not strong enough to keep the spine erect. So the prominent abdomen depends not only upon the visceral enlargements, but on the weakness of the abdominal muscles, which yield to the weight of the viscera they cover. The knock-knee and flat foot are other instances of muscular weakness; the muscles being weak, undue stress is thrown upon the ligaments, which, being soft, readily yield. But the cases in which the muscular weakness is most marked are those of acute rickets in very young children. A case was related in illustration of this. A child, ten months old, rapidly and almost completely lost the power of moving its extremities. The lower limbs were everted and motionless, the upper limbs occasionally moved in a slow and languid manner. The fontanelle was widely opened and depressed. The child was enormously fat; it sweated profusely about the head and upper part of the body; it was intensely tender, so that it screamed if only gently touched. The spleen was palpable. The upper incisor teeth only were cut. The father was very healthy, the mother fragile, and she had had children fast. Neither of the parents had been rickety. This was the fourth child, the three others being healthy. It had been brought up by hand and fed

Digitized by Google

partly on Swiss milk and partly on a patent farinaceous food. Here the muscular weakness was so great as at first sight to simulate infantile paralysis, and the bone lesions were very slightly marked; but a careful examination revealed nodulated ribs and slight enlargement of the wrists. It would be interesting to know the microscopical condition of the muscles in such cases of acute rickets. In less severe cases the only change I have found is that the muscular tissue is pale and ill developed. With regard to the bone changes: doubtless a marked symptom of rickets is the widely open fontanelle and its long delayed ossification. But if we exclude the retarded ossification, I should say the changes of the cranium are usually more of shape than of tissue. The head is flattened at the top, and bulges at the front and sides. But we do not find the remarkable prominences around the fontanelle associated with craniotabes, and which Drs. Lees and Barlow have shown to be often accompanied by marked symptoms of syphilis. Dr. Fagge objected to the observations of Drs. Lees and Barlow that these observers have been too ready to exclude rickets in their cases because of the absence of beading of the ribs, and that they did not investigate with sufficient minuteness the condition of the epiphysial line as revealed by section of the bones. But it must be remembered that Drs. Barlow and Lees did not merely exclude rickets, but they found syphilis; they observed not merely that rickets was absent, but that syphilis was present in the majority of their cases, and they interpreted the meaning of the craniotabes by its concomitants, and gave strong reasons for regarding it as a symptom of syphilis rather than of rickets. So with the long bones. The enlargement of the long bones seen in some cases of inherited syphilis is of a quite different nature to that of rickets. It leads to separation of the epiphyses (of which specimens were shown, to contrast with the changes in rickets); and the loss of power in the limbs in these cases is due to inflammation and not to muscular weakness, as in rickets. Moreover, the bone changes are associated with a quite different train of symptoms in the two diseases,—so that the cases of rickets and of syphilis are quite distinct and separable.

Dr. Dickinson, who commenced the adjourned debate, said—I will venture, sir, in obedience to the request with which you honoured me, to say a few words upon the state of the viscera in rickets. The enlargement of the abdominal organs which occurs in this dis-

Digitized by Google

ease was not very prominently referred to by Dr. Fagge when he opened this discussion, and I understood him to express an opinion that it was rather an accidental accompaniment of rickets brought on by the same causes than properly a part of the disease. I do not hold this opinion, but regard the enlargement of the viscera as just as much a part of rickets as the change in the bones, to which I believe it to be closely analogous. The enlargement has attracted the attention of many observers, both old and new. Whistler thought "the obstruction" in the liver and spleen the first departure from health. We perhaps know the condition best by the description of Sir William Jenner. I will briefly give an outline of it as it has come under my own observation. I have notes showing that it has affected in a marked degree children varying from seven months to four years in age, and I daresay the range might be increased. The spleen, liver, and lymphatic glands become enlarged—the spleen most so, the lymphatic glands least so; of these the mesenteric show the most decided swelling, the superficial glands becoming perhaps shotty to the touch, but never conspicuously enlarged. The enlargement of the spleen is often such that the organ fills nearly half the belly, reaching from the ribs to the pelvis, and from the lateral aspect to the median line. All degrees of enlargement up to this are to be found, the lesser being by far the more common. A spleen which has to be felt for, and is found perhaps with some difficulty, is more common than one which makes a considerable abdominal tumour. The liver does not undergo the extreme enlargement which the spleen does, though it is common to find it projecting two or three inches below the ribs. The increase in the viscera is a form of hypertrophy which bears resemblance to that which occurs in the bones. There is no new growth or deposit, but a large increase in the interstitial tissue, and some in the epithelial elements. The portal cellular tissue in the liver is soft, loose, and visibly and measurably increased, and displayed on the cut surface by a pattern of minute hexagons, one round each lobule. In the spleen the trabecular tissue is similarly increased, so that its delicate threads, which should be no thicker in proportion than those of a net, are swollen to the width of the spaces they enclose. The swollen organs are not materially altered in shape or in external smoothness. The Malpighian bodies in the spleen do not present the sago transformation of the lardaceous disease, nor do any of the affected structures give the iodine

Digitized by Google

reaction. The condition is in every respect different from the lardaceous state, excepting the mere existence of swelling in the one case as in the other. The earthy salts are diminished in the affected viscera, as appears from one very well-marked instance in which I had the opportunity of examining the spleen. These salts were reduced by two thirds in a given weight of the organ, as compared with the amount in health. The rickety spleen gave a percentage of ·09, a healthy spleen, taken for comparison, one of ·27. For lardaceous organs, as I have elsewhere shown, the proportion of earthy salts is increased. I think there can be no reasonable doubt that the swelling of the viscera is as much a part of the rickety condition, and as essentially belongs to it, as that of the bones. It is to be observed, however, that where the visceral change is most marked, that in the skeleton is seldom extreme—as if the disease spent its force in one direction or the other. It is amenable to treatment, though slowly. Under cod-liver oil, iron, and hygienic measures, a spleen which touches the pelvis may gather itself up so as to be with difficulty felt. The symptoms of this form of organic enlargement are less marked than those of the lardaceous; jaundice and ascites are unknown among its consequences, though, when the spleen is greatly affected, anæmia may be extreme.

Mr. Parker.—One of the most important points to decide, is the age at which rickets first begins, for on this hangs, it seems to me, the pathology of the disease. I should have been glad to have had some definite expression of opinion from Dr. Fagge. He does, however, hint at a very early date in fœtal life as the possible period of commencement, but does not tell us exactly what his own views are. Some authors do not consider rickets as congenital; nor is an hereditary tendency even allowed to have any part in its production. For my own part, I venture to differ in both these points, I believe it is constantly congenital, and that heredity is a very important etiological feature in its production. I have here the radius of a fœtus at term, it did not long survive its birth, although it appeared quite healthy. The changes are not very extensive in the epiphysis it is true, but they are very suggestive of rickets; the ulnæ moreover were considerably curved. It was indeed this curvature which drew my attention to the arms, and which had then—four years ago—the greatest interest for me. I conclude that Dr. Barlow and Dr. Lees think that artificial feeding is the responsible agent in the produc-

Digitized by Google

tion of rickets; and I quite agree that improper food will often lead to the production of typical manifestations of rickets in young infants. But I believe in the influence of the hygienic surroundings and in a constitutional predisposition, without which the artificial feeding would often be insufficient. For we constantly meet with typical rickets in babies who have been carefully suckled, and who have never had artificial food, as well as in babies who have been over-suckled.

I am not alone in regarding rickets as congenital. Bednar,[1] who was physician to the Vienna Foundling Hospital, in his work on the 'Diseases of Newborn Infants,' 1852, says, "The development and growth of the skeleton is often deficient, in that the latter, at the time of birth, is entirely cartilaginous, or very imperfectly ossified; this condition is generally called congenital rickets, which, in the newly born, manifests itself by a laterally compressed chest, swelling of the ends of the ribs, by slight curvature of the arm and thigh-bones, by widely (open) fontanelles, by wide sutures (Interstitialräume), and by a too great softening of the skull bones. The bodies are generally small and short, the extremities wasted, and the belly distended. The condition is accompanied in some cases by chronic hydrocephalus, in others by a hypertrophied spleen. Congenital rickets may be protracted into later periods, and then it manifests itself by insufficient hardness and resistance of the bones, and by long-continued non-joining of the apophyses, combined with growth of the hypertrophic brain." As regards hereditary influence. If we bear in mind the large numbers of children seen in hospitals who are rickety,—indeed, the larger proportion of all London children—and that when grown up they intermarry and have children, it is no longer easy to disregard hereditary influence as a powerful factor in the production of rickets, and one which will every year become more and more obvious.

Dr. Ritter von Rittershain[2] says (p. 66), "The direct transference of rickets, as such, from the parents to the child in many cases cannot be doubted." For although the deformities and other outward manifestations of the diathesis may have entirely disappeared in the parents, the constitutional peculiarity still remains, and will remain through life, especially under social conditions favorable to the higher development of rickets. Dr. Vogel, too,

[1] 'Die Krankheiten der Neugebornen und Säuglinge.' Wien, 1850, Part iv, p. 35.

[2] 'Die Pathologie und Therapie der Rachitis.' Berlin, 1863.

Digitized by Google

as Dr. Fagge pointed out, very strongly believes in this heredity, and quotes cases in his work on children's diseases. This hereditary transmission will, I should think, be the more likely to obtain in the cases of those mothers, whose social surroundings involve conditions of life unfavorable to general health. On this point Sir Wm. Jenner[1] says, "The health of the mother, however, has a decided influence on the development of rickets in the child. Whatever renders her delicate, whatever depresses her powers of forming good blood, *that* tends to produce rickets in an offspring." Dr. Fagge, in alluding to the chemistry of rickets, draws attention to the important bearing which it has on the exact nature of the disease. He says, "If there were a real alteration in the chemical constitution of the bones, affecting every particle of their substance, we could hardly doubt that the disease must exist at a very early period, if not from the first setting in of the process of ossification within the fœtus." I quite agree with them, and for myself, I have ventured to regard these chemical changes—the exactness of which we can hardly doubt, seeing that several competent observers have studied and reported on them—as additional evidence of the early commencement of the process.

By congenital rickets, I do not mean a disease which has been described by Virchow and Eberth[2] and others as *Fœtal* rickets. Yet I think the process differs in degree rather than in kind, and probably also in the period of its commencement; the changes, in fact, are more profound. For it has a marked predilection for the bones, attacking, however, the shafts rather than the epiphyses, and the base of the skull rather than the vault.

I do not remember to have seen rickets as generally understood in children under one month; this may be because in many cases the development of the external signs of rickets is not attended with symptoms which call for medical attendance. But among patients of one month the chest deformity and slight curves of the bone are not infrequently seen. A softened condition of the cranial bones, too—craniotabes—is not very uncommon about this time. It was Elsässer[3] who first accurately described this condition, and it was he who proposed the name "craniotabes." Softened patches in the skull bones had been frequently observed by other observers, and in Elsässer's book references to cases, and to speci-

[1] "Lectures on Rickets," 'Med. Times and Gazette,' 1860, p. 460, vol i.

[2] 'Der Weiche Hinterkopf.' Stuttgart, 1843.

Digitized by Google

mens in the different continental museums, are carefully made. This author regards rickets as the result of a "congenital constitutional tendency to a slow development of the whole body, and especially of the osseous system;" and he looks upon craniotabes "as the form of the disease which is peculiar to, and characteristic of, sucklings." He denies (p. 22) that it (craniotabes) is ever congenital, chiefly on the ground that he had never met with it in children under three months old. He found it in children who appeared otherwise quite healthy, and even strong, and then in such cases he looks upon the tabetic patches as the commencement of the process. But, in spite of exceptional cases he regards a congenital weakness as the predisposing cause, and pressure of the "healthy brain" (p. 149) on the softened skull as the immediate cause of the tabetic patches.

As to the nature of the tabes, Elsässer regarded it as essentially and typically rickets, and, in my opinion, he fully confirms his view by the citation of facts and cases, most of which are incontrovertible. Virchow,[1] in a paper on "Das normale Knochenwachsthum und die rachitische Störung desselben" (p. 495), refers to Elsässer's works in terms of praise, and expresses agreement with his views. When speaking of tabes Virchow says:—"I have never seen a case in the dead body in which there were not other bones, especially those of the thorax, showing rachitic changes." My own experience—if I may venture to refer to it so immediately after the mention of Virchow's name—tends to bear out Elsässer's view that the lesion is essentially rachitic in its nature and association. Two of the most recent cases I have seen were brought to the East London Children's Hospital, not as patients, but because the mothers were unable to leave them at home. These mothers had come about other children, who were all subjects of most extensive rickety deformities of the limbs; and so I chanced to examine the babies and found well-marked tabes. I could get no history of syphilis, whereas a family predisposition to rickets was already to hand in the rickety children who had been brought for treatment.

My friends, Dr. Lees and Dr. Barlow, in their interesting communication to the Society at the last meeting, endeavoured to show that syphilis is the largest factor in the causation of craniotabes. They say, "Whether it is its sole cause can only be determined certainly by the examination of a large number of infants in whose cases the question of syphilis can be absolutely excluded. We

[1] 'Archiv für pathologische Anatomie,' &c. Fünften Bandes, 4 Heft, 1853.

Digitized by Google

entertain a strong suspicion that when this has been done it will be found that craniotabes is always a result of syphilis." Even if Elsässer's and other published cases did not exist, and if one had no personal experience of the disease, I venture to think that these authors' own tables would show that the syphilitic suspicion is never likely to be confirmed. For they give at least twelve cases in which no history or signs of syphilis can be obtained. For me this would be conclusive evidence that there was no syphilis. There are few physicians more capable of ferreting out a history of congenital syphilis than Dr. Barlow, and when he fails I should rest satisfied that syphilis is not present as an appreciable factor. Hence, his tables show that all cases are not syphilitic. On the other hand, the tables do not, I think, show that the syphilitic cases were not at the same time rachitic.

Dr. Barlow considers that syphilis leads to softening, and that the pressure of the brain, then, more easily brings about absorption of the bone. With Elsässer, nearly all writers regard the condition as the result of intracranial pressure, being probably influenced by Elsässer's authority. This latter authority says (p. 149):—"In craniotabes it is clearly *simple pressure* which brings about the absorption of the softened bone, its thinning, and its perforation. The pressing mass is no morbid product, no unnatural tumour, no parasite, but the *healthy brain itself*. . . . This mechanical action of the brain is brought about by its regular rhythmical movements, aided by its rapid growth and its own specific weight."

The position in which these softened patches are mostly found is also urged as a proof of the doctrine of pressure. But I have more than once seen it affect considerable portions of the skull, as well as parts in front of a horizontal axis through the skull, the body being in a recumbent position, of which Elsässer says (p. 149), "in front of, and behind this limit no such places are found." Moreover, in Elsässer's book there is a plate showing patches of tabes in front of this horizontal limit. Finally, I must just mention a tabetic dog's skull, which is to be found in the Museum of the Royal College of Surgeons; for Elsässer considered that this disease was peculiar to the human subject, and that it could not occur in animals (p. 150).

One of the strongest reasons in my own mind, however, against this theory of intra-cranial pressure, is the fact that the skull at this time of life is especially constructed to favour growth, and at the

Digitized by Google

same time to avoid pressure. Hence we find the sutures unclosed and wide-open fontanelles, which remain unossified for months. I am not aware of any actual proofs, beyond mere supposition, that the brain is subject to such influences of gravity as must be accepted in order to make the pressure theory at all intelligible. Anatomists have long taught that the interior of the skull, with its processes of the dura mater, are intended to fix the brain and protect it from injury during the various movements—sometimes very violent—of the body. If gravity allows of such changes in infancy, similar changes ought to exist in adult life. If our brain gravitates to the side on which we sleep, for instance, how is it we ever wake up with clear heads? And how much more does this apply to invalids who are confined to their beds for years together? Is it, perhaps, because the bones of adults are harder than those of young children? If this be so, how is it, then, that the markings of the convolutions are most obvious in adults and almost absent in children? For this grooving of the skull bones is regarded by Elsässer and others as the counterpart of the tabes, due to the same cause but carried on to a less extent. I cannot conceive how the brain can gravitate towards the hinder part of the skull, so as to press upon it, without seriously dragging on the nerves which leave the cranium at the base. Have we any evidence that such is the case? Lastly, when we consider what are the two factors in this pressure, if there be pressure. We have the brain—a highly complex, exceedingly delicate, soft structure—on the one side, and the cranium—a bony structure, whose very object is to give support, and which is hard and intended to withstand pressure—on the other, the two being separated by a strong, fibrous, unyielding membrane—the dura mater. Then we are asked to believe that the hard bone softens and becomes absorbed, while the delicate brain substance remains intact. The condition has been compared to what is found in extensive hydrocephalus and other cases, where the skull bones have been thinned to a mere paper-like consistence; but I hardly think the cases are comparable, for in hydrocephalus the convolutions are flattened and the brain suffers both in its structure and functions. The erosion of bone by an aneurism has also been quoted as another case in point, but surely the two conditions are not at all identical. Does a healthy artery ever produce such absorption? Do the arteries within the skull ever produce craniotabes? For their grooves exist even in growing infants.

Digitized by Google

Hypertrophic growth of the brain is often spoken of in connection with the rickety diathesis, and some authors appeal to what they call the precociousness of rickety children in support of this supposed brain hypertrophy. Personally, I agree as to the precociousness, if that word be used to signify old-fashioned ways and mannerisms, but I cannot accept it to mean intellectual superiority. On this point Sir William Jenner (Lecture III, p. 416) says:—"Children the subjects of extreme rickets are almost always deficient in intellectual capacity and power." Indeed, one not infrequently sums up a case of rickets under the term "backwardness." The fact that backward children associate with adults more than healthy children could hardly account for intellectual superiority any more than that association with other children would restrain it.

As to the causes of tabes.—For my own part I incline to regard these tabetic patches as islands of undeveloped bone, and I think they have their analogies in the little islets of unossified cartilage (or, to use Dr. Fagge's expression, "even within the bony trabeculæ themselves there are often to be seen very numerous and large islets of residual cartilage matrix"), which are one of the characteristics of rachitic ossification; and which, when examined with the naked eye, in appearance exactly resemble the unossified fontanelles. Further, as has been shown, their commonest position is along the posterior border of the parietal bones, at points which are furthest removed from the single ossifying centre from which the parietal grows.

Bednar,[1] whose description of congenital rickets I have just quoted, obviously distinguishes between craniotabes, as a mere softening of bone, and the further stage, where a patch of membrane alone remains; while Elsässer includes both under the same disease and name. For under the section of "abnormalities" the former author describes "membranous holes in the skull bones of new-born infants" (häutige Lücken). These are most frequently found on the parietal, seldom on the occipital, bones; they occur in varying numbers, and when fairly extensive they can be distinctly felt through the scalp. They represent an imperfect ossification of the skull, and especially of the parietals, the membranous foundation of which turns into bone without previously becoming cartilage. The above-mentioned holes are found both in well-developed, ill-developed, and imperfectly-formed children. They are of no importance, and become closed as the skull fully ossifies.

[1] Op. cit., Part 2, p. 169.

Digitized by Google

They are very much less common on the occipital bone, which would be very inexplicable if gravity were their immediate cause. I am aware that Elsässer, who anticipated objections to his gravitation theory, considers an arrest of development little short of unphysiological. For he says (p. 144), "To regard this as an aberration of the original ossification, even if we had no positive evidence to the contrary, would be a meaningless hypothesis and contrary to the physiological conception of the process." But I cannot see this.

Dr. Fagge has just touched on the possible relations of syphilis and rickets. I shall not be far wrong in thinking that many members of the Society were last year a little startled by M. Parrot's[1] assertion that rickets was but a stage of congenital syphilis.

His was a very deliberate opinion, and the outcome of exceptional opportunities utilised in an exceptionally careful manner. Nevertheless, I am unable to accept his doctrine. I go even further, for I believe *the converse to hold good.* I would formulate—without rickets there would be little or no congenital bone syphilis. Such a mere statement must appear very hazarded, and I must endeavour to explain. It is now pretty generally admitted that a slight traumatism often suffices to bring to light a latent constitutional dyscrasia. Thus a slight blow has frequently set up a typical tubercular meningitis in subjects whose tubercular tendencies had hitherto been latent and unsuspected. The same applies to rheumatic fever, and also to acute gout. I know a gentleman who can bring on acute gout almost certainly by taking a longer walk than he is ordinarily accustomed to do. Many a cancer of the breast, and many other forms of tumour have been known to follow on a blow. In the same way I would speak of so-called syphilitic bone lesions in an infant; the already existing rickety changes are the determining causes. Thus my own view is that rickets is a lesion of nutrition of the primordial cartilage, out of which the bony skeleton is formed; and I think that the changes which M. Parrot described as due to syphilis, and sometimes leading to rickets, might be better defined as the manifestations of congenital syphilis in the already rhachitic skeleton. In this way it is no longer difficult to see the reason why syphilis exhibits such a marked predilection for those bones, and those parts of bone which are acknowledged to suffer so early and so constantly from rickets—the cranium and the

[1] 'Les Lésions Osseuses de la Syphilis Héréditaire," 'Path. Soc. Transactions,' vol. xxx, pp. 339—353.

Digitized by Google

epiphyses—the rickety affection predisposing to the syphilitic. In this way we could reconcile the various, and often conflicting, opinions on and descriptions of the microscopical appearances of rickety bones, as well as some other points in the pathological anatomy of rickets.[1] And further, there would be no difficulty in accepting the presence of rickets in animals, of which there are well-marked instances before us this evening. M. Parrot never alluded to this occurrence, although it would be hard to account for it if rickets were but the outcome of a vanishing syphilitic taint.

Although Dr. Fagge did not mention the subject in his introductory remarks, I think a debate on rickets will hardly be complete without some mention of what has been called adult rickets, or in England more commonly osteo-malacia or mollities ossium. Glisson[2] says:—"Videtur morbus hic multum saltem affinitatis habere (si non sit ejusdem familiæ) cum hoc affectû puerorum." Virchow believes that the two processes are entirely distinct. For him the only condition in adults with which ordinary rickets can be even distantly compared is "the remaining soft of certain callus-formations which are observed after fractures in cachectic subjects, or under the influence of serious losses of the nutritive juices, or as the effects of debilitating methods of treatment. Here alone have we proliferation without calcification." "In osteo-malacia real resorption takes place; that which is hard becomes soft . . In osteo-malacia it is the bone itself which is changed; in rickets the cartilage and the periosteum."

On the other hand, no less an authority than Trousseau[3] regards them as identical; for while he admits all the differences on which pathologists have insisted, he considers that they may all be explained by the varying developmental processes peculiar to the age of the patients. Thus, in osteo-malacia we have disappearance, atrophy, degeneration, regressive metamorphoses of parts, while in rickets we find growth, proliferation, hypertrophy, progressive metamorphosis, up to a certain point. In other words, rickets is an osteo-malacia of growing bone, modified in its manifestations by the energy of the bone formation; while osteo-malacia is a rickety condition of adult bone. The older a child is when the rickety process first manifests

[1] Parrot, op. cit., p. 339, "Les Altérations Osseuses causées par la Syphilis héréditaire, ont été prises, et le sont encore chaque jour, pour du Rachitis."

[2] 'De Rachitide,' Lond., 1650, p. 227.

[3] Trousseau and Lasègue, 'Union Médicale,' 1850, Nos. 77—134.

Digitized by Google

itself and the younger the adult when osteo-malacia commences, the more will the two diseases be found to resemble each other.

I confess my own experience is far too limited to allow me to express any opinion, but from what I can see I should gather that there are points of contact which it would be unwise to ignore.

SIR WILLIAM JENNER.—Sir, I published three lectures on rickets in 1860, and I have nothing to add to or take away from them this evening, and I can therefore have no objection to any reference being made to those lectures in this debate; indeed, I wish there had been fuller reference to them. Contrary to the views of Dr. Fagge and Dr. Eustace Smith, I see no reason to regard rickets as other than a diathesis. Dr. Smith quotes a passage from Dr. Aitken as a definition of diathesis, and then shows how rickets differ from this definition; but I cannot allow that the question is hereby settled. By a diathesis I mean a certain disposition to disease. The child of an ill-nourished mother is disposed to become rickety when placed under unfavorable circumstances after birth, or even under favorable circumstances in some cases. I do not see how that differs from tuberculosis or scrofulosis—for I still recognise a difference between these—or congenital syphilis. A father acquires syphilis and begets a child with congenital syphilis, a mother gets weak and bears a rickety child; or the parents are tubercular, and their children if in unfavorable circumstances develop tubercle. I know that a word is nothing, but still I think we want a word to group these conditions all together.

In reference to pigeon-breast, I would say that it very often arises from other diseases than rickets, but the two varieties are very easily distinguished. In rickets the deformity is due to the softening of the bones which yield at their growing ends and push forward the sternum as a rounded prominence, and the outline of the chest is a double curve. In pigeon-breast from non-rickety causes the yielding of the ribs takes place where there is a natural maximum bend, at their angles, the sternum is pushed straight forward, and the outline of the chest is angular. The tenderness of muscle has been referred to to-night; that is an old observation, and in my lectures I spoke of the tenderness being as great in the abdomen as in the thigh; I could not say more. At that time I examined the muscles in many non-acute cases, but did not find any special and distinct changes. The weakness of the muscles was one

Digitized by Google

argument used years ago against Rokitansky's view of the mode of production of pigeon-breast. Dr. Fagge has referred to the excretion of excess of uric acid as a possible cause of rickets; in my experience this is a very common condition in children whose health is disturbed, and I imagine it has little bearing on the disease.

With reference to the question of syphilis, which is very important, I may observe that twenty years ago I pointed out one strong argument which I believe still holds good. If a person is syphilitic the first child often escapes, from the continuance of the influence of the antisyphilitic remedies in the parent, but still it is the early children who suffer from syphilis. In rickets, on the contrary, it is the later ones that suffer, and among the poor, if one child has rickets, all the later ones are rickety. In the upper classes this is not such an absolute rule, as the mother often ceases to bear children for a time, leaves home, and re-establishes her health before another pregnancy. Another strong argument is, that all of us know persons, whose word we can trust implicitly, who are incapable of deceiving us, who assure us that they never had syphilis, and yet they have rickety children. I could quote several such cases, and, for my part, I hold that syphilis and rickets are quite distinct. Dr. Gee's argument in this matter is very strong, but it is open to M. Parrot to assert that rickets in animals differs from the disease in man.

With reference to the cranium, I think it has been stated that the bones of the skull are not much affected. On the contrary, I have found that they are often very seriously affected in rickets, and the change is found in front, often there is quite a depression over the suture between the two frontal eminences, the condition being identical with that in the ends of the long bones. Many rickety children are exceedingly fat, and I do not regard emaciation as due merely to rickets, but to the changes of the internal organs, especially in the lymphatic glands. Similar changes in these glands lead to emaciation in older children. I cannot think that what Dr. Dickinson has stated to-night about the changes in the internal organs explains what one sees. I have seen the liver like glue, and the spleen, when cut into thin slices, transparent, and these appearances cannot be explained by hypertrophy of the cells and fibrous structures of these organs. We see great development of fibrous tissue in cirrhosis of the liver, but the appearances to the naked eye and common lens are totally different from those of the

Digitized by Google

rickety liver. True, the latter does not absorb iodine, nor does it show the characteristics of the amyloid and lardaceous degeneration of these viscera. I have seen a large number of spleens after ague and various Indian fevers, and the cut surface has not appeared to me identical with the structure of the rickety spleen. With regard to the shape of the head, it has been stated by one speaker that if you flatten down the head from the top you get the head of rickets; my observation tells me that while the hydrocephalic head is increased in both its antero-posterior and transverse diameters, the rickety skull is long and narrow, and the forehead is unduly prominent in proportion to the breadth of the head; this is due to the development of much albuminoid substance in the white matter of the anterior lobes of the brain.

As to the chemical characters of rickety bones I am no authority, and we have not heard much to-night from others on this part of the question; one speaker has examined two bones—that is not much. But there are two or three points which ought to be referred to; one is the statement of Lehmann, that on boiling rickety bones they do not yield ordinary gelatine, but an animal matter resembling that of malignant bony growths; he observed also an enormous quantity of lime excreted in the urine, even as much as six times the normal amount; such statements are well worthy confirmation or refutation. Is the yielding in craniotabes the result of the pressure of the brain or of the pillow? I always thought it was the pillow. I have seen rickets begin in children seven and eight years old.

Dr. GEE, who was invited by the President to speak, said that the fact that the rickets of mankind seldom showed itself for the first time after the first year of age is a reason for believing it to be the same disease as the rickets of dogs, which also affects puppies only; and that if, indeed, the rickets of babies and of puppies be the same thing, the doctrine of Parrot would seem to meet with a fatal stumbling-block. Syphilis may be a cause of rickets, but is not the only cause.

The PRESIDENT.—First, I have to express a shade of regret that the debate, interesting and instructive as it has been, has not produced more in the form of pathological evidence. It may be that this evening will somewhat confute this criticism, otherwise I think we have all of us noted that in the main it has consisted in the interchange of opinion rather than the citation of new facts. I may

Digitized by Google

be asked, perhaps, what kind of facts I should have liked. In reply, let me say that I should have liked definite information as to the state of the urine in rickets, and possibly the state of the blood also. Further and more extended chemical analyses of the bones at different stages of the complaint also seem desirable. Additional facts as to rickets in the lower animals, with specimens, are wanted. So also as to rickets in the fœtus and congenital rickets. Lastly, I should much have liked to know from careful observation whether the state of the teeth, distinguishing between the first and second sets, is or is not modified by rickets. Amongst the parts of the subject most fully entertained in this discussion has been the relationship which exists between inherited taint of syphilis and rickets. Dr. Fagge, in his opening address, asked "whether syphilis may not be one of the causes of rickets," and Drs. Barlow and Lees have presented to us an excellent report, which supports to some extent the contention of M. Parrot that the craniotabes formerly supposed to be due to rickets—and with it some other lesions—is really due to syphilis. It is now long since we have known well that many of the malformed foreheads, most of the malformed teeth, and many cases of bent and enlarged bones, formerly considered to be of a rickety nature, are really syphilitic. The explanation of the precise cause of the deformity in the syphilitic skull has, however, been reserved for M. Parrot and Dr. Taylor, and to them we owe our present knowledge that in infancy the osseous system is often very extensively affected by a transitory form of inflammation. The skull bones and the long bones alike suffer, and the epiphysial ends are especially prone to be severely attacked. There remains, therefore, I think, no doubt whatever that in congenital syphilis a state of general periostitis is very common, which may easily be thought to resemble rickets. The child is in pain all over, and the joint ends of the bones are swollen and tender. In this condition the flat bones became vascular and soft, and it is difficult to withstand the evidence in favour of the belief that not only may they thicken, but that, under special local influences, they may atrophy and suffer local absorption. The influences which localise the thinning may be either external or internal, pressure of the brain or pressure of the pillow. If we regard the symptom named "craniotabes" as simply local absorption of soft bones from pressure, may we not easily admit that it is probably common both to syphilis and rickets? Each of these diseases in its own fashion makes the skull

Digitized by Google

bones vascular and soft, both make it painful for the child to move, and thus favour the occurrence of injurious pressure. We need not, I think, go so far as to believe that syphilis is "a cause of rickets," but may rather prefer to say that syphilis may on its own account produce conditions which simulate those of rickets? Is it not probable that to the skilled and careful observer there will in most cases be found grounds for a differential diagnosis between rickets and syphilis, and that too both in the ward and the post-mortem room? That the two often co-exist and run their course together is highly probable; but that they are essentially and totally distinct, being induced by wholly different causes, will, I think, be the verdict of all who have listened to this discussion. Surely those who confuse them, or who think that rickets apart from syphilis has no existence, commit a grave clinical error. I was glad to hear Sir William Jenner's defence of the term "diathesis" as applicable to the state of health which induces rickets, and his refusal to allow that word to be restricted by any arbitrary definition. If we are to understand by diathesis a condition of defective health, giving "during a long period" proclivity to special forms of disease, then undoubtedly the rickety state is a diathesis. If, on the other hand, the term is to be restricted to the results of a specific poison, then it is not. But the latter is not a very successful employment of the word. Just in the same sense as we have a scorbutic diathesis, a tubercular diathesis, a gouty diathesis, and a leprous diathesis, so we have a rachitic one. It is merely a question as to the use of the word, and those who object to it in this sense will perhaps kindly supply us with a better. Not only, however, do I contend that the rachitic state is correctly included with the diatheses, but I wish to ask Dr. Fagge very definitely whether there are any good reasons why it should not be placed with confidence in one class of diatheses. I allude to that class which may perhaps be conveniently known as "diet diatheses," or "assimilation diatheses." In this class are to be grouped, with others, scurvy, gout, pellagra, and, in my opinion, leprosy, all due to some error in diet or assimilation. It is very important to bear in mind respecting all of them, that although usually the cause is defect or excess of some food element, yet that precisely similar results may ensue from defect in assimilation or in the excretory functions. The effects of food, both negative and positive, are always relative to digestive capacity, and this may be influenced by the idiosyncracy of the individual, and thus the somewhat vulgar saw as to meat to one

Digitized by Google

and poison to another becomes a very literal truth. I would not insist upon this most obvious fact were it not that I think that a forgetfulness of it has done much to put us into a mist as regards the real causes of rickets and the maladies associated with it. Because defective food supply cannot in all cases be proved, it is hastily assumed that rickets is not a diet disease; and those who think it hereditary, consider that its hereditariness points to the same conclusion. Dr. Fagge quoted a German authority (Vogel) as insisting on its hereditariness, and saying not a word about food as a possible cause. But is not gout hereditary? and is not gout distinctly a diet disease? I would quote leprosy as an equally strong instance, but that the facts respecting it are not so well admitted or so widely known. There is nothing inconsistent in the fact that a tendency to disease produced by diet should be hereditary. It is the organs of assimilation which are inherited. Through their peculiarity the effects of unsuitable food may be greatly exaggerated, or even the most wholesome may prove non-nutritious or injurious. The arguments which have been thought to invalidate the hypothesis of a diet cause for rickets have been held to have yet heavier weight in the case of osteo-malacia, or mollities ossium. This occurs to those who have full choice of their food, and under conditions in which it is impossible to suspect any ordinary deviation from sound rules of diet. Yet may it not be, after all, that it is an instance of defect in assimilation? I wish especially to elicit Dr. Fagge's opinion on this subject. Mollities ossium is on the Continent known as "rickets of the adult," and Trousseau in particular devotes an able lecture to the attempt to prove their identity. Yet I think we may note amongst ourselves a decided willingness to avoid this subject, and to admit that nothing whatever is known as to the real nature and relationships of mollities ossium. In the present discussion it has, I think, scarcely been mentioned. Dr. Gee told us that if a child is not rickety at a year old it may be assumed that it will not become so. Other speakers, and amongst them definitely and emphatically Sir William Jenner, have extended the period of liability; but none, so far as I have heard, have hinted that it is a liability which extends through life, and is probably almost the same in kind, though modified in its results by age and other circumstances.

Amongst the arguments which Trousseau mentions in support of the identity of rickets and osteo-malacia is the fact that they are curable by the same remedy. He is a firm believer in cod-liver oil

Digitized by Google

as the best means of curing rickets, and he records a most remarkable case of advanced mollities ossium in which the patient was most definitely cured by its use. Surely we have, in such facts, not only support for the belief in their identity, but also in the theory of their being both due to defective assimilative power. Let me, in parenthesis, say that Trousseau insists that the oil must be the brown, unpurified kind. It is just possible that in the general substitution of the purified kind in English practice is one explanation of our diminished faith in the oil as a specific for rickets. If we assert that rickets is essentially a food diathesis we by no means exclude from the list of its causes such influences as cold, deficient clothing, bad ventilation, and the like. Nothing is more certain than that one and all of these may help to disorder the organs of assimilation, and prevent the perfection of digestion. Alone, however, none of them would, excepting in the hereditarily predisposed, be efficient in the production of rickets; whilst alone and quite unaided by them, defective food has been over and over again proved to be competent to that result. Defective food is then probably the main cause; defective assimilation in many cases helps the influence of defective food, and in a few cases accomplishes the whole task; the others are to be reckoned only as contribution and as helping chiefly to induce defective assimilation. If Dr. Fagge is not inclined to attempt the refutation of the diet hypothesis as the cause both of rickets in the infant and osteo-malacia in the adult, I have next to ask him whether it might not be convenient to somewhat modify our nomenclature, and place this series of related maladies in suitable juxtaposition of alliance. It is probable that peculiarities in the mode of life at different periods of life are the chief influences which modify the malady. We have perhaps the following: intra-uterine osteo-malacia, or congenital rickets; infantile osteo-malachia, or rickets of young children; osteo-malacia of adults; osteo-malacia of pregnancy; osteo-malacia of insanity; osteo-malacia of senility. It would be of much interest to say a few words in explanation of the different modes of manifestation assumed by the same malady at different periods of life, but time does not permit. I may just hint, however, that it is easy to explain both why osteo-malacia should be peculiar when it occurs to infants, and why it should be found in practice so overwhelmingly common in them in proportion to other ages. It is during the first year of life that absolutely no choice as to food is permitted, and

Digitized by Google

that a sameness of dietary is attained which finds no parallel at any other. If the milk given to the infant be defective there is no chance of escape, for it is probably its one sole article of food. The peculiarities of osteo-malacia of the infant are due to the fact that the bones are then still growing, and the cartilages unossified. At later periods no disease of epiphysial cartilages is possible, since, for the most part, these have ceased to exist. Dr. Fagge has drawn attention to the frequency with which symptoms of nervous disturbances occur in rickets, and has referred not only to the well-known deviations from the average in point of intelligence, but to hydrocephalus, chronic cerebritis, convulsive affections, tetany, &c. It is of not a little interest to those who believe in some bond of connection between the two conditions to note that in adult life with certain forms of insanity osteo-malacia is constantly associated. In this instance, it has been conjectured that in some way the nervous system interferes with the nutrition of the bones. Is not the hypothesis far more likely that both the nerve centres and the bones share in a defect of assimilation, in existence probably for a long time, before any symptoms in either class of organs revealed it? It may help, probably, not a little to the full acceptance and confirmation of the diet theory of rickets if we emphasise an opinion expressed by both the opener of the debate and by Mr. Warrington Haward and others who have taken part in it. I allude to the belief that a large majority of cases pass unrecognised. So long as we think only of well characterised cases, so long are we likely to cherish a belief that the disease is, in some sort, a pathological entity, and due to some specific cause. If we break away from this notion and recognise what is probably really the fact—that we only diagnose exaggerated cases, and that a tendency to the same, or a slight degree of it, is present in thousands of patients to whom the term rachitis is never applied,—we become better able to realise that the malady, so far from being a specific disease, is not even a well specialised one. The same argument is applicable to the mollities ossium of adults. To put this idea in other words, it may be said that when a condition of defective assimilation in an infant rises to a certain point, and produces failure in the process of ossification, we name it rickets, and when a similar ailment in an adult rises to a certain height of severity and produces brittle bones we call it mollities ossium. For one infant who manifests the outward signs of rickets, and for one adult who shows those of mollities ossium,

Digitized by Google

probably there are in each case a hundred in whom the tendency, in greater or less degree, and for longer or shorter time, is present. We recognise, name, and study only the severe and exaggerated examples. We must make a clear distinction between congenital rickets and hereditary rickets. The evidence which has been given that signs of rickety changes may be present in the mature fœtus at birth by no means proves that there was in these cases an inherited disposition to rickets. As has been well observed indeed by Dr. Joseph Adams, congenital conditions of disease not seldom are not hereditary. The mother is to fœtus not only its progenitor, but its nurse during intrauterine life. If rickets be a disease due to defective food and the mother's blood be in a defective condition, it may easily come about that, although the fœtus originally inherited nothing, yet it may become rickety during its pre-natal period of life. A disease which is in a true sense hereditary, ought to be derivable indifferently from either parent—sperm or germ; but it is clearly possible that rickets may not be so. We must admit, I think, the evidence that rickets is occasionally congenital, the rarity with which it is so fits well I would submit with the hypothesis of its food causation, since we know that even from very feeble mothers the fœtus often manages to obtain a supply quite sufficient for its full growth. It is very different when it comes to depend solely upon a single secretion, the milk of the same mother. As to the evidence of the transmission of hereditary tendency to rickets, I do not think that I have in this discussion heard any facts excepting the little fragment of evidence which I myself produced. In the case I refer to, Dr. Ormerod's, a father who had rickets in childhood and mollities ossium in adult life, had also two daughters who suffered severely from rickets. It is obvious that these children may have been themselves subjected to the ordinary food-causes of rickets, and that inheritance had nothing to do with it. I am unable to state anything as to their mother's health, or the management of their infancy. Still we may safely believe that there is nothing improbable in the idea of the hereditary transmission of a constitutional tendency to rickets—that is, to speak definitely, of a tendency to defective nutrition on the part of the organs of assimilation, which may either with or without the help of contributory causes, at some time bring about such a defect in the composition of the blood as would interfere with the nutrition of the bones.

Digitized by Google

Mr. CLEMENT LUCAS.—Among the points put forward for discussion by Dr. Hilton Fagge, in his very able and evenly balanced introductory remarks, is the question whether or not rickets is to be regarded as a diathesis. Now, I would not call it a *diathetic*, but rather a *diætetic* disease, for I think it can be shown that though bad air, bad clothing, and general squalor and filth, together, too, with certain constitutional states in the parents, may contribute to the production of rickets, there will be found, in every case, either an insufficient or an altogether injudicious diet. This leads me to remark that one symptom to which Dr. Fagge alluded I am inclined to think he passed over a little too lightly. I refer to the distended abdomen; and I would ask the gentlemen present whether they have ever seen rickets without a distended abdomen; for in my experience it is a constant, and an indication of the bad digestion and mal-assimilation in which the disease takes origin. I think, perhaps, too much stress has been laid on the enlargement of the solid organs as a cause of this distension. A little while ago I examined thirty rachitic children in succession, with a view of determining how far the liver was enlarged, and I came to the conclusion that it was not generally much increased in size. Indeed, my observations accorded closely with what Dr. Dickinson said on the last occasion, that the liver was seldom to be felt more than two inches below the ribs. The spleen, however, I have found subject to great variations; and there is now a child attending under my care at the Evelina Hospital where the spleen touches the crest of the ileum. This child is markedly rachitic but not syphilitic. There is also attending under my care at Guy's Hospital a child, the subject of hereditary syphilis, on whom the rash has but recently faded. This child has a spleen three inches below the ribs, but it shows no sign of rickets. Thus, I can show that the spleen may be enlarged from rickets without syphilis, and from syphilis without rickets. M. Parrot might regard this as evidence favouring his view of the common origin of the two diseases, but the two spleens are pathologically distinct. By far the chief cause, however, of the enlarged abdomen is the distension of the stomach and intestine with flatus, consequent upon injudicious feeding. Children under nine months suffering from rickets will almost invariably be found to be bottle-fed, whereas children suffering from rickets at sixteen or eighteen months will often be found still hanging to the mother's nipple. In either case the diet is injudicious. It is in the second year that the dis-

Digitized by Google

ease is most frequent, because this corresponds, in a great number of instances, to the abrupt cessation of milk diet and its replacement by improper and indigestible solid food (especially rice and starch foods), or the mother's breast is still considered to be sufficient support.

I regard rickets as a purely artificial disease, which can be produced at pleasure, and cured with certainty. As regards which child is most frequently attacked, my experience is in accord with what Sir William Jenner said on the last occasion—that it is the eldest child of the rich and the younger children of the poor who suffer most. The eldest child of the rich suffers because it is an experimental child, and the parents learn, by practising on it, how best to feed those which follow. Dr. Fagge remarked—and I agree with him—that the younger children of the poor suffer because, with large families, the parents are unable to supply sufficient food for them. If, then, rickets be, as I maintain, an artificial and dietetic disease, can such an artificially produced disease become hereditary? To this question I would answer Yes, and in two ways; in the first place, the rachitic conformation—the enlarged head and widened frame—will have a tendency to be reproduced in the next generation, without the actual occurrence of rickets in the infant; and secondly, there will be a greater tendency to the production of the disease if the children be placed under the special conditions which favour it. This leads me to propound a general law of heredity — that the hereditary tendency of a disease is directly as its chronicity, and inversely as the rapidity with which it passes through the system. Hence such diseases as syphilis, rheumatism, gout, tubercle, cancer—diseases which persist a long time in the system—are those which are reproduced with the greatest certainty in the offspring; whereas acute diseases leave no mark on the next generation. But rickets is a disease of infancy. Hence it shows itself, in the following generation, rather as a rachitic conformation than as rickets itself.

I now wish to speak of certain special symptoms of rickets, and first of that which is among the most common, viz. enlargement of the epiphyses of the wrists. It is often asked why it is that the epiphyses of the wrist frequently show enlargement when those of the ankle show none. To me this question presents no difficulty, and I think the answer is as old as that of Œdipus, the king, which he gave in answer to the Theban Sphinx: "Man first as a babe from the womb, four-footed, creeps on his way." It is because

Digitized by Google

rachitic children are four-legged animals, crawling about on their hands and knees, that the wrists suffer when the ankles escape; but in children who walk upright the ankles will invariably be found enlarged as well as the wrists. But here, again, the wrists are often enlarged ont of proportion to the other epiphyses, and this admits also of easy explanation, for rachitic children are continually falling, and then, as is shown by the frequent occurrence of Colles's fracture in adults, the force of concussion is transmitted through the lower end of the radius. The epiphysis which is most worked or injured shows the greatest enlargement.

Beading of the ribs, which is so common a symptom as to be frequently taken as a test-sign, admits of a similar explantion. It is a constant symptom, because the ribs are ever on the move. Dr. Barlow mentioned, on the last occasion, that the fifth, sixth, and seventh ribs are those on which the beads first appear. The reason is evident. These are the longest ribs, which undergo the greatest amount of movement, the upper and lower being comparatively quiescent.

Rickets is the chief cause of knock-knee, and when this deformity is fully developed there appears on the inner side of the shaft of the tibia, just below the tuberosity, a tubercle, to which I believe public attention has never been directed. I exhibited a well-marked specimen before the Hunterian Society in October, 1878, in a patient on whom I had performed Ogston's operation. The tubercle occurs in about half the number of cases which suggest osteotomy, and I have seen it developed as late as the age of seventeen. I call it the *knock-knee tubercle*. It appears to be developed to support the line of gravity, and, the anterior border of the tibia becoming flattened, a new line appears which runs up to this tubercle. These tubercles gradually become absorbed after the knees are put straight.

Another symptom to which I would allude is laryngismus stridulus. This is a local spasmodic affection found always associated with rickets; must it not be due, then, to some local irritatation of the recurrent laryngeal nerve? I think it not unlikely that the growing extremities of the tracheal rings will be found enlarged and pressing upon the nerve, or possibly it may be irritated where it passes under the inferior corner of the thyroid cartilage. If not here, the spot where it passes through the jugular foramen should be examined. It is so localised a spasm that it must be due to a local cause.

Digitized by Google

No description that I have met with quite accords with my experience of the rachitic head. In the first place, it is a large head, and those who say that the head is not enlarged, but simply rendered disproportionate by the lack of development of the face, have fallen into error by including in the non-rachitic class heads that have been enlarged by antecedent rickets, the patients at the time of examination showing no enlarged epiphyses are other signs of rickets. There is a child now in the Evelina Hospital who has a remarkable head, but no enlarged epiphyses. I had some difficulty in persuading the house-surgeon and registrar that this head was due to rickets, till he stripped the child and exposed a characteristic pigeon-chest. There is also a boy in the hospital with most extensive rachitic deformities, on both of whose knees I have operated by Ogston's method. He is eight years of age, and has a head twenty-one and a half inches in circumference—more than an inch above the average. But, lest one might fall into error by judging too much from individual cases, I asked Dr. White, the house-surgeon, to measure the heads of the children at present in the hospital. Of these seventeen showed signs of rickets, and their average age being 4·72; Dr. White finds the average circumference of the heads to be 21·22. Comparing these with a similar number of non-rachitic heads, Dr. White found with an average age of 6·05, the average circumference was 19·95. Thus, with more than a year in favour of the non-rachitic children, the average circumference of the head was less by an inch or more. The rachitic head is peculiar. It is a long head, broad across the parietal bones, but always flat at the top. It invariably gives increased width between the eyes, showing that the base is increased as well as the vertex. In its most extreme form, it is composed of four convexities, like four scallop shells loosely articulated together, corresponding to the frontal, parietal, and occipital bones; and I have been in the habit of calling this the *scallop-shell head*. The fontanelles are depressed and remain depressed when ossification is complete. The antero-posterior ridge, which is common between the parietal bones of normal skulls, is absent in the rachitic skull. A protuberant occipital bone with a deep depression above in the adult is almost characteristic of old rachitis.

Dr. Fagge has alluded to Thackeray's skull. It was undoubtedly rachitic; and I could point to the skulls of many other persons—persons distinguished in literary and scientific pursuits—who show

Digitized by Google

well-marked signs of antecedent rickets. Indeed, I regard the rachitic skull as not a thing to be ashamed of, but rather as a good fortune, inasmuch as by its greater capacity, it may allow of greater mental development.

Dr. BAXTER.—It was with a view to obtain some more exact notions as to the causation of the disease that I investigated upwards of a hundred consecutive cases of rickets, with especial reference to the following points:—The age of the parents, their health (particularly as regards the presence, in either of them, of any exhausting disease, *e.g.* phthisis), and such evidence of their having themselves suffered from rickets in infancy as might be furnished by the existence of thoracic deformity. The number and health of previous children, if any, were recorded. The circumstances of the mother during her pregnancy were inquired into. Next, the hygienic surroundings of the patient, especially as regards exposure to damp and seclusion from sunshine; also the existence of other disease, antecedent or concomitant, more particularly inherited syphilis. Lastly, the nature and quantity of food administered since birth. The investigation in every case was conducted with some care. A good many of the records have unfortunately been lost, though the results of the inquiry remain. But I have succeeded in recovering notes of the first eighty cases, which I have analysed afresh, in order to give numerical precision to my statements. Without going into needless detail, I may briefly say that no constant relation was made out between any of the above reputed factors and the development of rickets, with one exception, diet. Take, for instance, the place of the patient in the family series, on which considerable stress was laid, many years ago, by Sir William Jenner. Among my cases of rickets 19 per cent. were first-born children, 13·5 per cent. were second-born children, 19 per cent. were third-born children, 13·5 per cent. were fifth-born children, 8 per cent. were sixth-born children, 16 per cent. were seventh-born children, 2 per cent. were ninth-born children and upwards. The larger proportion of the above cases can hardly be ascribed to the influence of repeated pregnancies in exhausting the mother's health or reducing the standard of material comfort enjoyed by the parents. Again, as to inherited syphilis: only 13·5 per cent. of my cases are noted as unquestionably syphilitic, while 12 per cent. more are marked doubtful. It is, perhaps, worthy of mention that of the

Digitized by Google

28 per cent. of the whole number in whom craniotabes was observed no less than 75 per cent. were syphilitic. This, of course, adds nothing to the weighty evidence adduced by Drs. Barlow and Lees; I allude to it in passing, because, at the time my observations were made, I had no suspicion of there being any relation between the two things. These instances are enough to illustrate the kind of negative results brought out by the inquiry. The only positive result, as I have remarked, concerned the diet of the infant. It was found that no less than 92 per cent. of the whole number had been given farinaceous food of one kind or another before the age of twelve months. Here are the figures: 42 per cent. had had farinaceous food daily from their birth, 30 per cent. had had farinaceous food daily from the age of three months, 4 per cent. from the age of six months, 16 per cent. from the age of nine months. It may be added that in many, though not by any means in all, the first onset of the disease and its degree of severity appeared to be distinctly related to the period at which the administration of starchy matter was begun, and to the proportion between this element of the dietary and the others with which it was invariably associated. Of the 8 per cent. of cases in which no starchy food had been given before the age of one year,[1] several might have been ascribed to maternal feebleness, the mothers suffering, at the time, from general arthritis deformans. One child was undoubtedly syphilitic, another was bred in a cellar to which no daylight ever penetrated, and in which gas was continually burning. In one case only could no cause be made out. The first child of young and healthy parents, living amid excellent surroundings, free from syphilitic taint, nourished exclusively at the breast, began to show signs of rickets at the age of five months. The disease was mild, but unmistakable.

So far, then, the result of the inquiry seemed to point decidedly in one direction. But clinical evidence of this sort, even when drawn from a very large number of cases, affords at best only a certain probability, sufficient, perhaps, as a provisional guide to action, but never amounting to proof. To obtain this, a series of experiments was undertaken with puppies, kittens, rabbits, guinea-pigs, and white mice. As soon as possible after their birth they were put

[1] It must be remembered that the fact rests on the unsupported testimony of the mothers. My strong dislike to starch-feeding was well known among the out-patients of the Evelina Hospital, and their tendency would have been to conceal or to minimise it.

Digitized by Google

upon a diet of pure arrowroot jelly, with a variable quantity of added milk. Their digestive juices were speedily found to be deficient in, or destitute of, amylolytic power: the starch-jelly passing through their intestines unchanged. Let me say at once that in the issue of these experiments I was disappointed. They were fairly numerous, but in no single instance were such changes produced in the osseous system as could be considered identical with those observed in the human subject. The administration of starchy food to these young animals was always followed by the usual phenomena of inanition; when the proportion of starch was great, they died quickly; when it was smaller, death was delayed for a longer period. But, quick or slow, the course of events was the same in all. The bones took part in the general atrophy; they were thinner and more frail than in healthy animals of the same age; but they never showed any specific changes at their junction with cartilage. I attributed my failure at the time, and I think justly, to the extreme difficulty I encountered in keeping the animals alive for any length of time. In no case did they live long enough to furnish me with evidence *against* the starch hypothesis, as they yielded none to confirm it. I believe a French observer, M. Tripier, failed, like myself, to induce rickets artificially in the lower animals; with the details of his work I am unacquainted, as I have never succeeded in laying hands on a copy of his memoir. It was not without some feeling of surprise that I found myself baffled by an obstacle much more serious than I had been led to anticipate from the records of success achieved by earlier experimenters. Published statements had prepared me to find spontaneous rickets not uncommon among domestic mammals, and artificial rickets easy of production. Now I am bound to own that I have never been fortunate enough to see a case of true rickets in one of the lower animals, either during life or after death. I would not be understood to question the occurrence, or even the frequency, of the disease among them; but of this I am quite sure, that many instances of so-called rickets in the lower animals are instances of a disease of the skeleton by no means identical with human rickets; while with regard to many other cases that have been placed on record, the published evidence is insufficient to enable us either to affirm or deny their identity with the infantile disease. Experiment, then, did nothing to strengthen or to weaken the result of clinical observation.

We may naturally ask, if the starch-hypothesis be admitted as

Digitized by Google

probable, whether any connection can be suggested between two sets of phenomena, superficially so disparate, as starch-feeding and rickets? In the first place, starch may be supposed to exert some directly noxious action by undergoing decomposition in the bowel and yielding products capable of being absorbed into the blood and exerting an influence on the development of the bones analogous to that exerted by phosphorus in Wegner's experiments. The objection to this is that, so far as we know, starch undergoes no such decomposition; we find it in the excreta, stained with bile, but otherwise unaltered. Secondly, it has been thought indirectly harmful, owing to its lack of nutrient properties. That the digestive organs of infants and young animals are incapable of converting starch into sugar has been proved both by physiological experiment and clinical observation. Were an infant fed on starch alone it would die of starvation. It would present the same symptoms and *post-mortem* appearances as the animals of which I have already spoken. But such symptoms are not present in most cases of rickets. On referring to my list I find that 54 per cent. of my cases are stated to have been well-nourished, 14 per cent. not wasted, and only 30 per cent. ill-nourished. It must be borne in mind that the proportion of starch to the really nutrient elements of the dietary is seldom very great. Thus, in 60 per cent. of my cases the children were suckled up to the age of nine months; in 27 per cent. for periods varying from one to six months; while only 13 per cent. of the whole number never had the breast at all. These were usually supplied with an abundance of cow's milk. In those very rare instances in which milk is altogether withheld, the child developes well-marked scurvy in conjunction with rickets. Of this I have seen more than one example. Moreover, there is clinical evidence that an infant may suffer from prolonged ill-health, may grow pale and waste away, may be severely scourged by syphilis, and yet escape rickets. I have notes of such cases, and I find that, in every instance, the mother's milk was the only food given. Lastly, it is conceivable that starch may operate indirectly by interfering in some way with the assimilation of fatty matter. This possibility appears to meet all the facts of the case more completely than any other, and is strengthened by what we know of the remarkable curative effects of cod-liver oil.

In conclusion, I shall briefly notice three objections often urged against the hypothesis that rickets is a consequence of the premature

Digitized by Google

administration of starchy food. First, the occurrence of congenital rickets. Is an infant ever born with the disease? I agree with Dr. Fagge in thinking that no sufficient proof exists of the identity of so-called "fœtal rickets" with the disease we are now considering. Secondly, the occasional development of rickets at puberty. This has been more than once asserted to occur, but I know of no decisive evidence on the point. Thirdly, the geographical distribution of the disease. We find an American surgeon[1] stating that "rickets is a disease so rarely met with in our country, that I have no experience which would entitle me to speak of it authoritatively from my own observation." We can hardly suppose that infant feeding in the United States is very different from infant feeding here. Is it possible that the author alludes not so much to rickets as to those rachitic deformities of the limbs which call for surgical interference, and which must be ascribed less to the disease than to its improper management at an early period of its course? Should the three objections I have specified be found to rest on an assured foundation, any theory which connects rickets with the administration of starchy food—or indeed with any error of diet—must be given up. Those, however, who, like myself, are inclined to hold such a theory, at any rate provisionally, as according better with the facts hitherto observed than any other, may be excused if they hesitate to abandon it until driven to do so by the unanswerable logic of well-authenticated specimens brought before the Society.

Dr. Thomas Barlow read a paper on:—*a Case of so-called Fœtal Rickets* (*Cretinism*). (See Plate XXXIII).—For the fœtus from which these specimens were taken I am indebted to my friend Dr. Herman. The fœtus was believed to be of full term and was born dead. There was nothing in the family history which would throw light upon the case excepting the fact that one previous child out of a large number was born with "turned feet." The proportions of the fœtus were very remarkable. There was nothing special about the head and trunk, the neck was short and thick, the limbs stunted. The upper limbs placed close to the body did not extend further down than the umbilicus and the lower limbs; from the ilium to the heel only measured five inches. There was a remarkable accumulation of subcutaneous fat, and the arms, forearms, fingers, and to a less degree the lower limbs, presented numerous transverse folds (*vide* fig. 1). The

[1] Markoe, 'Diseases of the Bones.' New York, 1872.

Digitized by Google

Digitized by Google

Fig. I.

Fig. II.

Fig. III.

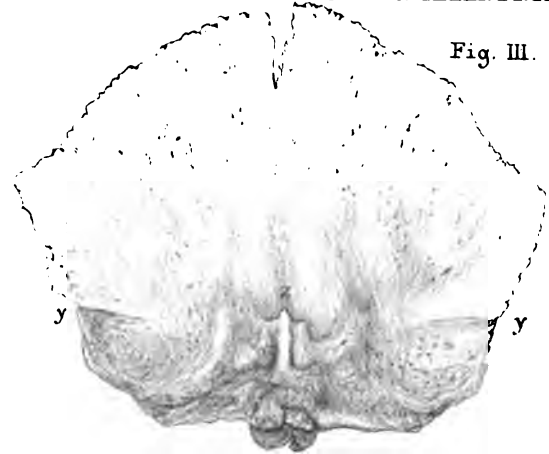

Fig. IV.

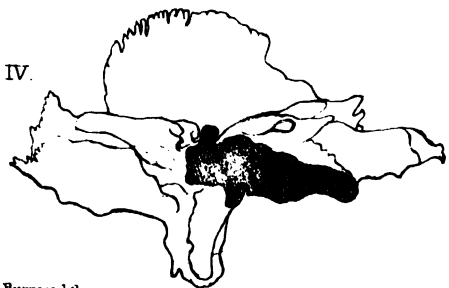

Fig. V.

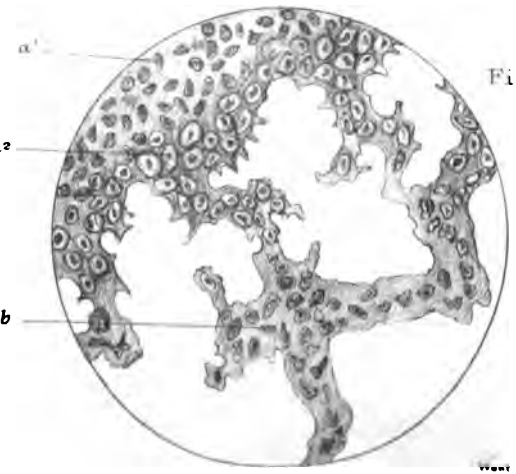

S G. Shattock del F. Burgess lith.

Digitized by Google

UNIV. OF MICH.

DESCRIPTION OF PLATE XXXIII.

Illustrating Dr. Barlow's Case of so called Fœtal Rickets (? Cretinism).

FIG. 1.—Forearm and hand showing radius with sigmoid curve and short stunted fingers.

FIG. 2.—Section of humerus with relatively large epiphyses and short compact shaft; line of junction quite sharp and defined, and rudimentary bony sheath forming a slight cup round the epiphysis.

FIG. 3.—Supra-occipital. *z*. Internal occipital protuberance. *y*, *y*, are at the extremities of the lines, which correspond with the junction of the lower part (which is developed in cartilage) with the upper part (which is developed in membrane). Thus the cartilage-formed portion is stunted as compared with the membrane-formed portion.

FIG. 4.—Vertical antero-posterior section through basis cranii, showing premature synostosis between basi-occipital and basi-sphenoid.

FIG. 5.—Section of junction of epiphysis with shaft of femur. a_1. Cartilage cells above line of ossification. a_2. Cartilage cells at line of ossification; the cells much enlarged and spherical in shape, but showing very imperfect row formation. *b*. Bone trabeculæ. (Oc. 2, ob. 8. Tube in Hartnack.)

S. G. Shattock, del.

Digitized by Google

Digitized by Google

lungs were not expanded. There was no gross disease in the viscera. The specimens to which I wish to call attention are the bones of the fœtus, upper extremity; the clavicle is natural; it is longer than either humerus or ulna (it will be remembered that the clavicle is a membrane-formed bone). The scapula shows much thickening of bone where the cartilage joins it, and there appear to be two thick lips, including the edge of the cartilage. The humerus shows relatively large upper and lower epiphyses and a short stout shaft (*vide* fig. 2). On section it is seen that the epiphyses are cartilaginous throughout. There is no irregularity in the line of ossification and no massing up of pale bluish material such as is seen in a typical rickety long bone at the junction of shaft and epiphysis. The bone of the shaft is hard and compact on the surface and cancellous in the middle, and there is more indication of a medullary canal than is seen in normal full term fœtal long bones. At the outer side of the upper extremity there is a very slight extension of bone at the base of the great tuberosity. This is a manifestation of the tendency to cupping round the epiphysis, which is very marked in Mr. Shattock's specimens, to be presently exhibited. The radius is exceedingly oblique in its direction and presents a striking sigmoid curve with the pronator tubercle in the centre.

In the bones of the lower extremity the only points to which I will refer are: (1) the remarkable bend of the femur concave on the flexor aspect, (2) the absence of an ossific centre in the lower epiphysis, and (3) an invasion of fibrous tissue from the periosteum, spreading at the junction of the shaft and epiphysis. The sternum and costal cartilages show no ossification. The ribs present distinct nodosities, but instead of being at the junction of rib and cartilage these nodosities definitely belong to the bone, and each consists of a bony cup which surrounds the end of the cartilage like a sheath. This cup in fact is quite similar to the rudimentary sheath pointed out in the humerus and scapula. There is a similar cup at the vertebral end of the rib.

There is nothing special about the vertebræ. Taking the bones forming the vault of the cranium we find in the tabular (supra-occipital) part of the occiput different proportions from those found in the normal fœtal skull.

The internal occipital spine rises at the junction of the lower with the middle third of the median ridge instead of rising at or near its middle point.

Digitized by Google

The small sulci which mark the line of union of the lower part of the supra-occipital with the upper part are, in this specimen, lower down than normal (*vide* fig. 3).

The lower part of the supra-occipital is formed in cartilage, the upper part in membrane, and the deviations from the normal characters of the bone just described point to the fact that the cartilage-formed portion is stunted in proportion to the other. This is quite in harmony with the condition of the long bones. The other bones of the vault of the cranium which are formed in membrane are all well developed.

Looking at the basis cranii, we find the foramen magnum is cordate in outline, and has a steep wall on each side owing to the development of a ridge of bone on the ex-occipital above and behind the hypoglossal foramen. The most remarkable feature, however, is the complete and premature bony ankylosis of the basi-occipital and basi-sphenoid (fig. 4).

This is one of the cases which would have been classed some time ago as an example of fœtal rickets. But let it be noted that there are essential differences alongside of some superficial similarities.

First, it will be seen that with regard to the long bones the epiphyses generally are large compared with the shafts. In true rickets it is not the whole epiphysis, but the line of ossification which is swollen; but here it is the whole epiphysis which is large, at all events relatively to the shaft.

Second, there are signs of intrusion of fibrous tissue from the periosteum in between the shaft and the epiphysis, and also of the formation of a sheath-like prolongation around and external to the base of the epiphysis. This is well shown in the nodosities of the ribs.

Third, the shaft is singularly hard and compact, there is no trace of any fracture, and the bendings which occur are exaggerations of the normal bends. There is no thickening of periosteum or rarefaction of medullary parts of bone such as are described in rickets.

Fourth, the stunted growth in length of the shafts, whilst the thickness is normal, or perhaps excessive, is quite different from anything seen in rickets. Now, it might have been argued that in this child there had been at one period of intrauterine life a rickety condition, which having run its course had left merely hardened bent bones. But a microscopic examination of the ends of the bones I think gives no support to this view. Some sections made for me

Digitized by Google

by Mr. Boyd show that the cartilage in the greater part of the epiphysis is not materially altered, but along the line of ossification the cartilage cells are greatly enlarged and spherical in shape, and the vertical row formation, which is so striking a feature in normal ossification, is here conspicuously imperfect (*vide* fig. 5). Thus, unlike true rickets, there is no proliferation of cartilage, indeed, the ossifying cartilage is very scanty in amount, and the primary bone areolæ do not present the characteristic organ-pipe arrangement. The subsequent development appears to depend mainly on the periosteum. Thus it happens that the growth of the shaft in length is arrested whilst it grows normally, if not even to an exaggerated degree in thickness. The ingrowth of fibrous tissue between epiphysis and shaft, and the cup-like sheath at the base of the epiphysis are developed from the periosteum.

Several years ago specimens like this were investigated by Heinrich Müller and Urtel, and they pointed out how essentially different this lesion was from true rickets, and Urtel proposed for it the name of fœtal chondritis. Two years ago Professor Eberth [1] published a monograph on the subject, including some observations of his own on a deformed calf which showed similar lesions. Professor Eberth shows that with some variations this condition of long bones is one of the characteristics of cretinism. Too much importance has been attributed to the premature union of the basi-occipital and basi-sphenoid found by Virchow in one cretin's skull which he examined. Eberth shows that it is not constant in cretins. It occurs in this specimen, and has been found in others, but not always. Probably the peculiar arrest of growth in the length of the bones from defective proliferation and row formation of the embryonal cartilage is a constant feature; though it seems likely enough that the amount of this defective proliferation varies considerably in different cases.[2]

Case of craniotabes in a non-rickety child.—This specimen is the hinder part of the cranium of a female child, aged seven months. On the outer surface of the left parietal bone there is a broad

[1] Die Foetale Rachitis und ihre Beziehungen zu dem Cretinismus.

[2] M. Parrot has suggested the title "Achondroplasy" for the condition illustrated by these specimens, by which he means a defective plastic power in the embryonal cartilage. ('Bulletins de la Société d'Anthropologie de Paris,' 1878, p. 296.)

Digitized by Google

sinuous band of thin osteophytic deposit. It is situated above the lower and posterior margins, and also runs parallel to the sagittal suture for two thirds of its extent. The width of this thin layer of deposit varies from one inch to one inch and a half. Just above the posterior inferior angle within the area of this deposit is a spot of commencing craniotabes—*i.e.* from the inner plate there has been slight absorption of bone, so that pressure in this region gives the characteristic crackle feel. Beyond this spot, in each direction also, the bone yields more than it ought to do normally, that is to say, where the osteophytic deposit exists the bone is softer than in other portions. The inner surface of the parietal, in addition, shows in some parts a slightly rough granular suface.

I wish to point out first that the child from whom this cranium was taken was not rickety. There was no reason why she should be rickety, her mother being a healthy young woman with abundance of milk, which had been the child's sole food. And in fact she was not rickety. The fifth and sixth ribs at their junctions with the cartilages are shown along with the cranium. Neither to naked eye nor to microscopic examination does there appear any proliferation of cartilage the starting point of "beading." The fifth and sixth ribs on the inner surface are test ribs for rickets, and if a child seven months old has any rickets at all it will manifest itself in this position.

Secondly, I wish to point out that there was much reason to suspect that the child was syphilitic. The thin layer of osteophytic deposit on the parietals is, I believe, in the light of other cases, sufficient evidence. But there was a history of obstinate snuffles during the first three months of the child's life, which had left some permanent collapse of the root of her nose, obvious enough when she was brought to the hospital at the age of seven months; and although the mother could give no history of rash, there were some dubious spots on the nates when she was brought.

The father denied having had a chancre, but admitted having had some venereal troubles four years before. The mother had suffered for a month when five months pregnant with sore throat, loss of voice, and rheumatic pains in the limbs.

The child was brought with symptoms of subacute basic meningitis, the cause of which I am unable to state. She died of it, and no other lesions beyond those of the skull and the meninges were found.

Digitized by Google

Mr. SAMUEL G. SHATTOCK read a paper on *Some cases of Osseous Lesion in the Fœtus.* [See Plate XXXIV.]—With a view of bringing under notice a condition variously considered as distinct from and identical with that ordinarily known as rickets, I may be allowed to notice the following specimens, although they are nearly devoid of clinical history, and only one has permitted of histological examination.

The first specimen which I may notice is the skeleton of a fœtus which was born dead, at what was reputed the full time. And firstly of the ribs of this skeleton. From their angles to their anterior extremities they are enlarged in increasing degree by a formation of minutely porous osseous substance, their anterior extremities forming a series of irregularly conical or club-shaped masses, so large as to lie together by the sides of the sternum. Bone has been freely formed around and in the lower costal cartilages, the cartilage being in some places embedded in the bone which has grown upon it, whilst in others, bone has spread irregularly into the cartilage from the enlarged ends of the ribs.

All the segments of the innominate bones are unnaturally thick, and their surfaces closely porous; their ossifying margins too granulated, and irregularly projected into the cartilage beyond. A similar description would apply to the scapulæ, except that the changes are most marked in the growing margins, and but little in the middle of the blade. Moreover, the coracoid process is not only for the most part osseous, but is ankylosed with the rest of the scapula. The longer bones of the extremities, all of them, present the following characters: the ends of their shafts are greatly enlarged, and widely overhanging, the margin of the outspread part being sinuous, dentate or jagged, and raised beyond the terminal surface on which the epiphyses have been received.

All the long bones, except the clavicles, are stunted in length; but the clavicles are remarkable exceptions, and are longer even than the shafts of the forearm.

In the humeri, portions of the surface are minutely porous, and lowly raised, apparently from a localised periostitis. The apparent deposit of inflammatory bone is especially evident on the back and lower part of the shafts (fig. 1), and similar thin depositions have occurred on various portions of the radius and ulna.

In both femora the shaft is laterally compressed, and measures twice as much from before as from side to side.

The longitudinal section of the humerus and of the femur shows

Digitized by Google

little that can be designated abnormal. The wall of the shaft is throughout thick, firm and compact, thinning over its ends, which are composed of small cancellated tissue, firm to the margin of the advancing bone. Both the humerus and femur have a well-marked medullary canal.

No ossification has occurred in the carpus. The metacarpal bones and phalanges are shortened, broad and flat. The os calcis is completely ossified, and the cuboid, for its chief part; and so are the bones of the metatarsus and the phalanges.

In the skull, generally, the surfaces of all the bones, even to the petrous parts of the temporal bones, are closely porous; all of them are thicker than is natural for bones of the same size, and their inner surfaces are unduly impressed with the cerebral convolutions. This is especially marked in the interparietal portion of the occipital bone, the more central parts of which, on each side of the middle line, are atrophied to perforation, and there is a similar absorption of the left parietal bone at its posterior inferior angle.

The foramen magnum is disproportionately small and cordate, encroached upon from behind, narrow in front.

The occipital bone around the foramen magnum is exceedingly thick, and the margins of the lateral sinuses are exaggerated by the formation of bony ridges and spines.[1] This condition of thickening and unnatural porosity affects, also, markedly the adjoining mastoid portions of the temporal bones, which are ankylosed with the contiguous parts of the occipital. The basi-occipital is inclined abruptly downwards nearly at a right angle with the post-sphenoid A longitudinal section shows commencing synostosis between the inferior part of the basi-occipital and the post-sphenoid, and complete fusion of the ossifying mesethmoid and median cartilage (from which the vomer is separable) with the sphenoid; the pre- and post-sphenoid are conjoined as usual.

The cerebral surface of the sphenoid presents an osseous deposit tending to be longitudinally furrowed, and the lesser wings being chiefly affected.

In the bones of the face these inflammatory changes are marked mainly in the superior maxilla.

All the facial bones are of the size natural at the full time, as are also the tabular bones of the cranium.

[1] See fig. 2.

Digitized by Google

Digitized by Google

Fig. I.

Fig. III.

Fig. II.

E. Burgess lith.

West Newman & Co. imp

Digitized by Google

DESCRIPTION OF PLATE XXXIV.

Illustrating Mr. Shattock's communication on Fœtal Rickets.

FIG. 1.—The humerus of the fœtal skeleton described in the text, seen from behind, and showing the great size of the ends of the diaphysis, and the layer of bone over the lower portion of its surface.

FIG. 2.—The base of the skull (the frontal bone being removed) of the same fœtus as the preceding humerus, showing the diminutive size of the foramen magnum and the unnatural thickness and porosity of the several bones.

FIG. 3.—The left femur of the human cretin (Mus. Coll. Surg.) noticed in the text. Both the ends of the femur have been divided vertically, and the sections display much irregularity of the ossific process, and the fibrous condition of the larger part of the epiphysial cartilages.

Digitized by Google

Digitized by Google

The frontal and parietal bones are more capacious in the region of their eminences than natural.

The erratic extension of bone which has occurred into the costal cartilage has occurred also in another curiously rare situation.

The suspensory portion of the cartilage of Meckel is completely ossified and forms a solid osseous rod continued from the malleus to the inner side of the lower jaw.[1]

In most of the dorsal vertebræ an irregular formation of bone has occurred in the connecting cartilage of the arch, the laminæ of which are in some of the vertebræ incompletely ankylosed. In the axis the laminæ are continuously connected with the body of the vertebra.

The centres of the coccygeal vertebræ are nearly fully ossified, and the macerated specimens appear unnaturally proportioned to the bodies of the rest of the vertebræ.

Bone has been freely formed in all the segments of the sternum, including the xiphoid. The manubrium has the full adult form in miniature, and the ossifying segments of the gladiolus are through out continuous, though indications of its original elements remain.

The following measurements may be of service as definitely indicating the size of particular parts of the skeleton for purposes of comparison:

Between ends of great wings of the sphenoid, 5 cm. 9 mm.

Between ends of lesser wings of the sphenoid, 3 cm. 3 mm.

Between centres of optic foramina, 1 cm. 3½ mm.

Between centres of foramina rotunda, 1 cm. 9 mm.

Between centres of foramina ovalia, 2 cm. 8 mm.

Between upper margins of mastoid portions of the temporal bone (greatest breadth), 5 cm. 8 mm.

Breadth of post sphenoid at its posterior part, 1 cm.

Length of body of sphenoid, 1 cm. 7 mm.

Maximum thickness of basioccipital, 7½ mm.

Maximum thickness of postsphenoid, 7½ mm.

Thickness of supra-occipital behind the foramen magnum, 7 mm.

Length of basioccipital, 1 cm. 3 mm.

Transverse measurement of foramen magnum, 1 cm. 3 mm.

Antero-posterior measurement of foramen magnum, 7 mm.

Horizontal measurement of temporal bone at level of zygoma, 3 cm. 8 mm.

[1] 'Described in the 'Journal of Anatomy,' vol. xiv, p. 201.

Digitized by Google

From margin of tympanum to upper edge of squamous part of temporal bone, 2 cm. 5 mm.

Vertical measurement of parietal over eminence, 8 cm. 1 mm.

Horizontal measurement of parietal over eminence, 7 cm. 7 mm.

Horizontal measurement of frontal bone over eminence, 4 cm. 9½ mm.

Bones of the extremities, as measured in straight line:

Length of clavicle, 3 cm. 8½ mm.

Length of shaft of radius, 3 cm. 3½ mm.

Length of shaft of ulna, 3 cm. 3½ mm.

Length of shaft of humerus, 4 cm. 1 mm.

Length of shaft of femur, 4 cm. 8 mm.

Thickness of femur in antero-posterior section, 1 cm.

Length of shaft of tibia, 4 cm.

Length of shaft of fibula, 3 cm. 7 mm.

Blade of scapula from above, 3 cm. 4 mm.

Breadth of scapula at level of glenoid cavity, 2 cm.

Length of sternum, 5 cm. 2 mm.

Distance of highest point of iliac crest from centre of acetabulum, 2 cm. 7 mm.

Distance of ischial tuberosity from same centre, 2 cm. 1 mm.

Distance of symphysis pubis from same centre, 1 cm. 9 mm.

Length of spinal column, measured along its curve, 21 cm.

In the next place I may refer to four fœtal skeletons in the Hunterian Museum, viz. Nos. 321, 322, 322 *a* (Teratological Series), and No. 2879 *c*, *a* (Pathological Series), which illustrate a somewhat similar condition.

The first three are classed by Mr. Lowne as specimens of arrested growth of the limbs—"hanomelus." In these specimens, besides the unnatural thickness of the pelvic bones and scapulæ, marked beading of ribs and the shortness and terminal enlargement of the long bones, the latter present deformities of curvature, but in all the clavicles are of unabated length.

In No. 322 (which is hydrocephalic) the humeri are bent towards their lower ends, with their convexities backwards. The ulnæ are bent backwards, and the radii form shallow "clavicular" curves. The femora are markedly bent forwards and ridged behind, the fibulæ bent outwards, the tibiæ inwards. There is no premature formation of bone in the cartilaginous epiphyses or in the temporary synchondroses.

Digitized by Google

A longitudinal section of the skull (which Professor Flower has kindly permitted of all these specimens) shows no synostosis of the basi-occipital with the body of the sphenoid, but these bones, as is also the lower part of the supra-occipital, are increased in thickness and, as compared with the standard, deficient in length.

Length of basi-occipital, 1 cm. 1½ mm.

Length of body of sphenoid, 1 cm. 6 mm.

Distance between posterior margin of foramen magnum and external occipital protuberance, 1 cm. 7½ mm.

Thickness of basi-occipital at its anterior part, 6½ mm.

The parietal and other tabular bones are of the full size.

In No. 321 there are similar deformities. No ossification has occurred in the sternum. A longitudinal section of the skull shows complete synostosis to have occurred between the basi-occipital and body of the sphenoid, and shows increased thickness of the occipital around the foramen magnum, as in the preceding specimen.

Extreme length of conjoined basi-occipital and body of sphenoid, 2 cm. 7½ mm.

Distance between centres of foramina ovalia, 2 cm. 7 mm.

Distance between apices of petrous portions of temporal bones 1 cm.

Distance between posterior margin of foramen magnum and external occipital protuberance, 1 cm. 3 mm.

The bones of the skull in general slightly below the full size.

Length of spinal column, 18½ cm.

No. 322 *a* is a specimen in outward appearance identical with that described by Dr. Barlow. This specimen was exhibited at the Society by Mr. W. Adams, and is briefly noticed in the twenty-fourth volume of the 'Transactions,' p. 263.

No 2879, *c*, a (in the Hunterian Museum), placed amongst the specimens which illustrate the deformities of the bones which may follow, or the histological cure of rickets, is a specimen of a similar kind. The head is markedly hydrocephalic. A longitudinal section of the skull shows complete synostosis of the basi-occipital and sphenoid bones. The bones of the extremities are short and curved, the anterior ends of the ribs strongly beaded. Distance between posterior margin of foramen magnum and external occipital protuberance 2 cm.

The size of the cranial bones generally is in excess of that at birth; and it is possible that the child survived its birth some time.

Length of clavicle (in straight line), 3 cm. 7½ mm.

Digitized by Google

Length of shafts of ulna and humerus, 2 cm. 1 mm.

Length of spinal column, 15½ cm.

In none of these specimens are there marks of ossific periostitis, and no craniotabes.

I may, lastly, notice another specimen from the Hunterian Museum, which, through the kindness of Professor Flower, I have had the opportunity of examining.

Of this specimen (319) the only record is, that the child (a female) was stillborn at the eighth month of pregnancy.

This fœtus presents the appearances which have been described as typical of cretinism.

The limbs stunted, the hands and feet short and wide, the root of the nose flat and broad, its tip flattened and upturned its alæ thick and rounded, the mouth large, and the lips thick.

In sporadic cretinism, the presence of symmetrical fatty outgrowths, one of them beneath the skin of the neck, external to the sterno-mastoid muscle, appears to be of constant occurrence; and as of less constant occurrence, wasting or absence of the thyroid body. Two cases of complete absence of the thyroid body are recorded by Mr. Curling, but in one of four cases which came under the notice of Dr. Fagge,[1] the thyroid body was of full size or even enlarged.

In the specimen to which I am referring the thyroid body is perfectly normal. There are no fatty outgrowths recognisable in the neck, but in place of this, and perhaps as a related condition, is a general accumulation of subcutaneous fat. This association of general obesity with cases of arrested growth of the limbs is noticed of nearly all the recorded cases.

The tabular bones of the cranium are quite healthy and of the natural size.[2] The foramen magnum is much contracted, and its descent steep. The basi-occipital is in considerable part osseous; the body of the sphenoid is wholly cartilaginous. There is no hydrocephalus.

In regard to the condition of the long bones, I may describe the femur as an example of them all. The femur is but an inch and a quarter long; its shaft is flattened antero-posteriorly, and curved with its convexity outwards.

A longitudinal section shows the osseous tissue to be throughout

[1] Vol. xxv, p. 268, 'Transactions, Pathological Society.'

[2] The lower portion of the supra-occipital may be an exception.

Digitized by Google

firm, formed into a compact wall and finely cancellated interior devoid of medullary canal.

The growing margins of the diaphysis are notably irregular but throughout firm, and the diaphysis is terminated by epiphyses in which there is, next the bone, a layer between three and four millimètres in thickness, of soft, œdematous cartilage; beyond this the epiphyses are abundantly intersected by vascular spaces and accompanying fibrous tissue (fig. 3).

The microscopic appearances of sections of the upper and lower ends of the femur are as follow:

The line of ossification is irregular; the cartilage cells in front are large, round, or oval, and collected in groups without serial order.

Calcification has extended irregularly into this cartilage without the production of primary areolæ; and the proper alveolar formation has been effected by excavation of the calcified cartilage through means of the advancing medullary tissue.

The vessels of the cartilage, which communicate with those of the bone, are surrounded by bone-forming connective tissue, by which the bone is in a few spots extended into the deepest part of the unhealthy cartilage.

Both Eberth and Müller describe cretinism in the calf. And amongst the same specimens from which I have drawn, is an Hunterian one (No. 318 Teratological series) of a fœtal bitch puppy, which presents the characteristic cretinous habit. The longitudinal section of the skull shows no accomplished synostosis.

In this specimen there is in addition cleft palate and harelip.

There are four specimens from the human subject in St. Bartholomew's which belong to the same category. A, 9 (Teratological series); A, 254; No. 35·67 (series 35); No. A, 142 (Teratological series).

The last specimen is peculiar in the malformation of the head, which resembles that described in a case reported in the 'Jahrbuch der Kinderheilkunde.'[1] There is complete synostosis of the segments of the occipital bone; and of the lambdoid and coronal sutures, the enlargement of the head having subsequently occurred upwards by the anterior fontanelle.

Now, these specimens, as a whole, exhibit much that is in a

[1] Band xv, 1 Heft, p. 79.

Digitized by Google

general and outward way like rickets,—the shortness of the long bones, the comparative enlargement of their growing ends, their deformities of curvature,[1] and the thickening of the flat bones, perhaps, also, the association of these changes with hydrocephalus.

The essential error of nutrition would appear to consist in an histological spoiling of the cartilage concerned in ossification, which fails to furnish a medium for bone formation. In none of these cases is the intra-membranous process of ossification arrested.

The tabular bones of the skull (the supra-occipital cartilage-bone excepted) are of normal size; so is the lower jaw, and so are all the bones of the face. And in the bones of the extremities periosteal formation has outstripped the cartilaginous, as appears in the comparative thickness of the shafts, and in the extension of bone for a way over the epiphysial cartilages,—most notable in the ribs, which in all these specimens have deep cotyloid ends in which the outer extremities of the costal cartilages are received.

And I would submit that the exceptional length of the clavicles may be due to the same cause; for whilst all the other long bones of the body commence to ossify in cartilage, the ossification of the clavicle proceeds at first in membrane.

Evidence appears to me to render it probable that some, at least, of these cases (of which a series has been recently collected in the 'Jahrbuch der Kinderheilkunde,' 1880) illustrate recoveries from rickets, which has both arisen and passed away *in utero*.

Curvatures of the bones are recorded of all, and would indicate beyond doubt that a period had been passed through in which the osseous substance was unnaturally soft, and had unduly yielded to the muscular tone. And the histological accounts of such cases contain evidence of analogy between this condition and that of rickets; the ultimate result being perhaps intelligible on the supposition that the cartilage, not of the whole epiphysis, since this attains nearly the full size, but that the cartilage which has been concerned in the ossification process has by some means been spoiled, and rendered nearly functionless.

For example, in the case of Urtel's (noticed by Eberth), there was no new formation of the cartilage cells before the ossification

[1] Except in the case first noticed, which is quite exceptional in the premature formation of bone in so many unnatural situations, which may perhaps explain the absence of curvature in the long bones of the extremities, these being in great part firmly formed before the onset of the disease.

Digitized by Google

line; the cells were flat, like connective-tissue cells, or large, round, or oval, and heaped in irregular groups; the calcifying layers of cartilage were broken by medullary cavities, which are short, insomuch as the secondary osseous formation has taken place, and in the central parts of the ossifying surface are found, in the calcified cartilage, cells like large bladders.

Eberth's histological report in the case of the cretinous calf described by him,[1] shows the condition to be the same as that of the human cretin which I have described. He notices that the spheno-basilar and intersphenoidal synchondroses were vascular, gelatinous, with large, roundish, and elongated cells, the condition being such as existed also in the long bones. And Eberth admits the likeness between the condition observable in the cretinous calf and that of rickets, apparent in the irregularity of the ossification line, calcification of the cartilage, the pressing forwards of medullary spaces beyond the ossifying border, and the replacement of medulla by fibrous tissue, and notices, as telling against the likeness, the absence of excessive proliferation in the cells of the cartilage. But he is comparing rickets in progress with a condition which (if it is rachitic) is rather a sequel. Nevertheless, there are very few cases forthcoming in which the bones of the fœtus have been actually observed unnaturally soft. And in some of these it is less probable that the condition has been one of rickets than one of those as yet obscure forms of disease which render the bones fragile rather than flexible. Such a condition explains best the multitudinous fractures which have been recorded of some cases of fœtal disease; as, for instance, in a case[2] where the ribs where broken in forty-three places, and both the radii, the right humerus, and both clavicles in addition, or in another where there were not less than 113 fractures. But when these cases are eliminated it is nevertheless true that no microscopic account is on record of a progressing fœtal rickets, and until this evidence is forthcoming its occurrence rests only on conjecture.

As Dr. Crisp pointed out with relation to rickets, so it may be said from similar comparative evidence, that cretinism, whether it is a sequel of rachitis or a distinct condition, is not by any necessity associated with syphilis. But that syphilis may be added to such a

[1] Eberth, C. J., 'Die fötale Rachitis und ihre Beziehungen zu Cretinismus.' Leipzig, 1878.

[2] Quoted from Meckel in the 'Jahrbuch der Kinderheilkunde,' Band. xv, 1 Heft, p. 79.

Digitized by Google

condition in the human subject is not to be denied. And there is evidence of this, perhaps, in the specimen which I first noticed, where, besides the general changes common to all the cases, are superadded the marks of diffused periostitis, and complete atrophy of portions of the unhealthy bones of the cranium. But as to whether cretinism is a sequel of rickets or not, comparative pathology adds no new knowledge; the facts in comparative pathology run parallel with the human.

Dr. LONGHURST regarded the affection as due to imperfect nutrition, a consequence of civilization and its attendant evils, not congenital and not syphilitic. It is certain that all syphilitic children are not rickety, and on this point he felt that he could speak positively, for during many years of his life he had been engaged in the observation and treatment of the children of syphilitic parents, many of whom were syphilitic, but they were not rickety, because in his opinion they were not subject to its causes, being well fed, well clothed, under good sanitary conditions, and enjoying frequent change of climate.

Looking to the pathological changes in the structures, though similar conditions have been found in syphilis, and minutely described by Perrot and others, yet he did not consider them as conclusive; nor does he connect them with craniotabes. Then with regard to tubercle, though tubercle and rickets may co-exist, yet a markedly tubercular child seldom if ever becomes rickety.

The chemical change in the bones was a marked feature in the disease, and pointed to its being a malnutrition rather than one of diathesis.

He agreed with Dr. Crisp in thinking that much light might be thrown on the subject by considering the affection in relation to other portions of the animal kingdom, which he believed did not suffer except under similar insanitary conditions to those in which the affection is seen in the human subject.

Though the affection may be seen in the native children in the city populations in Africa and India, he had not seen it amongst them in the up country and mountainous districts.

Mr. SPENCER WATSON.—1. One argument against the theory of the identity of rickets with congenital syphilis has hitherto escaped notice. It is one, sir, on which I trust that we shall have some expression of opinion from yourself. I allude to the rarity of the

Digitized by Google

concurrence, in the same individual, of the characteristic *stamps* of congenital syphilis and rickets respectively. For these two diseases have this in common. Each, *when typically developed*, leaves its mark on the individual affected by it, so that the adult who has suffered from either in infancy is recognisable by the alterations effected either in the long bones and skull, as in the case of rickets, or the teeth and physiognomy, as in congenital syphilis.

You, sir, have shown conclusively how unmistakable are the alterations of the permanent upper incisor teeth resulting from infantile syphilis. (I have satisfied myself, by examining a large number of cases, that your conclusions are correct on this point.) We should, therefore, expect to find rickety bones and peg-shaped and notched teeth in the same individual very frequently, if rickets were nothing but a phase or variety of congenital syphilis; but, according to my experience, this is far from being so. I cannot remember to have seen more than one such case, and in that the rickety manifestations were very meagre and unsatisfactory. There being, however, no *primâ facie* reason why the two diseases should not occasionally meet in one individual, the rarity of this occurrence is, I think, a very strong argument against their being identical. Possibly a commingling of the two may give rise to the somewhat puzzling phenomena of *craniotabes*, in which neither syphilis nor rickets evince their most characteristic manifestations, though it presents features suggestive of both.

2. The *geographical distribution* of rickets has not been alluded to except by Dr. Hilton Fagge, who incidentally mentioned that its exceptional prevalence in this country earned for it the name of morbus Anglicus. It seems to be found now in every quarter of the globe (Senator), but to prevail more in cold and damp climates. As far as I can learn, however, no systematic inquiry has ever been instituted as to the relative prevalence of the disease in various parts of the world; and I would suggest that a committee of this Society might be very profitably employed in making such an inquiry, and that we might, as a result, obtain a clue to the cause or causes of rickets, about which we seem at present to have by no means an exact knowledge. In order to test the feasability and possible advantages of such a line of investigation, I have written to several eminent retired Indian medical officers, asking them to give their opinions as to the prevalence of rickets in India. I chose

Digitized by Google

India as offering, perhaps, the greatest possible contrast to our own country in point of climate, race, and habits of the people.

The following gentlemen have kindly replied to me :—Dr. Norman Chevers, Dr. Ewart, Dr. Evézard, Dr. Thomas Parker Smith, and Dr. Mackellar; and I shall venture to read some of their opinions.

A. Dr. Norman Chevers, whose name is well known in connection with the Hospital and Medical College at Calcutta, thus writes :—"It cannot be doubted that the disease (rickets) is rarer in Indian hospitals—so rare that I never, during my long experience as a clinical physician, said to my students, 'Here is a typical case of rickets.'" He, however, explains this absence of rickety children from his experience as being perhaps due to the excessive mortality among native infants from acute diseases and neglect, or otherwise, so that only strong and non-rickety children survive.

B. From Dr. Evézard, whose experience was chiefly in the Madras Presidency and Burmah, I have the following remarks :—"I can only call to mind two or three cases and these occurred in a damp climate, not the climate of the parents (Hindoos, the most vegetarian), where the excessive rains necessitated confinement in close and damp huts, the natural food of the infants having been suddenly cut off by disease; and (wet nurses not being procurable) the patients had been fed on rice or arrowroot." "The native population is almost free from true rickets." This applies to Hindoo, Mussulman, and Chinese of the Madras Presidency, and in Burmah, "Rickets was so uncommon in Madras as to induce Surgeon Chipperfield, the Anatomical Lecturer of the Government College, to make a special report of a case occurring in his practice."

Dr. Evézard states, however, that in India and Burmah infants are not brought in large numbers to the public hospitals and dispensaries, and that when ill opium is the almost universal native remedy both for mother and child, and that it is often administered injudiciously, and carries off a vast number of infants before their diseases have fully developed themselves.

C. Dr. Ewart, formerly Professor of Pathology in Calcutta, whose experience was in the Bengal Presidency says, "Rickets is not a very common affection in India." "The practice of mothers suckling their own offspring is almost universal." "Then there is little real overcrowding, even in towns, inasmuch as much of the twenty-four hours is, throughout the year, virtually passed in the open air, in

Digitized by Google

courtyards or in habitations full of chinks, crevices, and other openings freely communicating with the external air, so that the rebreathing of air already utilised only exists in a minimum degree."

D. Dr. Thomas Parker Smith, whose time in India was spent in the north-west and central Provinces, says that "he does not remember to have seen a single case of rickets among the European children (140 in number) of his regiment, and thinks it must be equally rare among the natives."

E. Dr. Mackellar, who was in Upper India for about twenty-five years, says that he cannot call to mind a single case of rickets either among natives or Europeans. He served also for two years in Burmah, where rice is eaten, and has no recollection of rickets there.

Dr. Mackellar remarks that the native children in India "are suckled longer as a rule than they are in this country," and that "their young lives are passed out of doors in the open air and bright sunshine." As regards the influence of food, he thinks that if the rarity of rickets depends on the dietetic advantages of the natives it is probably due to the addition of dāl to the rice and even to the wheat-flour, which forms the principle food of the poorest classes. Dāl is a sort of pea-meal, and is very rich in albuminates. "Children after they are weaned get much more milk than here. This alone would go far towards the prevention of rickets."

I should therefore, judging from the testimony of these gentlemen, conclude that rickets is certainly rare in India, and that the immunity of the population from this scourge is probably due to their constant exposure (adults as well as children) to air and sunlight, though the habits as to lactation and the character of the food ought also to be credited with some portion of the protective influence.

If then we turn to America we find that Drs. Meigs and Pepper, of Philadelphia are perfectly astonished at the statements made by English authors as to the enormous prevalence of rickets in our cities. They congratulate themselves that "owing to the better accommodation and larger size of the houses, the better quality and the greater abundance of the food of the lower classes in American cities as compared with English or European," they "escape, to a great extent, the ravages of this fatal disease."

I have cited these instances of comparative immunity of other countries rather as specimens of the kind of information which might be obtained by a systematic inquiry, than as giving any perfectly reliable data on which to form a theory. The inquiry is

Digitized by Google

too large in extent to allow of being followed out by any individual, but I cannot help thinking that if placed in the hands of a committee of the Society appointed for the purpose, a most important and valuable table of results might be obtained, and our present general impressions as to the cause or causes of rickets might be replaced by something like an exact theory.

Dr. GOODHART.—My text is *visceral* rickets, if there is such a thing. Three propositions concerning this branch of the subject have been put forward at one time or another.

1st. That the spleen and liver are not enlarged in rickets; the seeming increase is due to displacement.

2nd. That the enlargement of the spleen and liver is as much a part of the disease as the changes in the bones, an opinion advanced by Sir William Jenner and supported by Dr. Dickinson.

3rd. That the viscera are enlarged, but present no distinctive features, and that the increase in size is due to some cause antecedent to it and the skeletal changes, an opinion attributed to Dr. Gee and reaffirmed by Dr. Hilton Fagge.

I shall confine myself mostly to the question of *splenic* enlargement, because I think the facts at hand concerning the liver are hardly sufficient to enable us to form a positive opinion whether it is or is not diseased in rickets. To take the three statements in order:

1st. Is the spleen enlarged or is it not?

It is certainly enlarged in some cases of rickets: (*a*) by the unanswerable proof afforded by *post-mortem* examinations; (*b*) I have notes of cases in which the spleen has occupied a third, at least, of the abdominal cavity during life, an amount of enlargement which puts the possibility of a mere displacement in such quite out of the question; and (*c*) it is possible to separate during life those cases of rickets with splenic enlargement from those without it, almost without physical examination, by means of the peculiar pallor which the splenic cases present.

No further evidence is wanting to demonstrate that an actual increase in the size of the spleen is, at any rate, an occasional fact in the history of rickets.

Having stated that there is *post-mortem* proof of splenic enlargement in rickets, I will next state what is the change which I conceive such spleens to have undergone, a point upon which there

Digitized by Google.

has been some difference of opinion, even in this discussion. I have examined four cases, and to judge from them the spleen is large and firm, with some slight thickenings of its capsule; its section is homogeneous in appearance, from the paucity of the Malpighian corpuscles and the want of that contrast which is usually afforded between them and the splenic pulp. Under the microscope the change is one of hyaline fibroid thickening of the septa and stroma at the expense of the pulp and Malpighian sheaths. I have described and figured this condition elsewhere,[1] so that it is unnecessary to say more of it here.

From this it will be seen that I am quite in accord with Dr. Dickinson, so far as the spleen is concerned, that the change is one of interstitial splenitis, if it be desirable to call it so, but perhaps better of interstitial fibrosis, the new material being of a hyaline kind, and not necessarily by any means the outcome of an inflammatory state. I have not been able to detect any similar change in the liver, or, perhaps, to put this statement more guardedly, I have not been able to satisfy myself that this material exists in the rhachitic liver in an abnormal quantity.

Sir William Jenner alluded to some observations of his own in which the spleen and liver in thin sections were found to be glue-like from the presence of a peculiar morbid deposit; appearances which he considered denoted something of an unusual kind. And he therefore takes exception to Dr. Dickinson's description of the change as one of interstitial fibrosis. But, if I may be allowed to say so, the observations of Sir William Jenner are by no means irreconcilable with those of Dr. Dickinson. It will be allowed that the glue-like change must have been exceptionally extreme, and it is well known that this fibrous material or hyaline fibroid, when it rises to an extreme degree, presents just such a gristly, cartilaginous, and in thin slices, glue-like appearance as was noticed by Sir William Jenner; and, so far from any antagonism, we have, indeed, some remarkable facts in corroboration of the assertion that the disease is one of thickening of the stroma of certain organs. The original term—albuminoid—applied to this material, is not by any means a bad one as applied to the morbid material itself; it is objectionable chiefly in that it has been taken to indicate something peculiar to the morbid deposit of rickets—a something not found in other diseases—whereas the material does not differ from that found in several

[1] 'Atlas of Pathology,' New Syd. Soc., Fasc. 2, Art. "Spleen."

Digitized by Google

other states, or, to speak more precisely, from the morbid material found in the spleen in chronic enlargement, from ague, and many other conditions.

When I come to the next question, What is the relation between splenic enlargement and rickets? I am no longer able to keep company with Dr. Dickinson, for I am unable to support his contention that the visceral enlargement is as much a part of the disdisease as are the skeletal changes. I am mostly influenced in thinking otherwise by finding that the splenic enlargement, in my experience, occurs in but a small proportion of cases of rachitis, and that when it does occur it is by no means in the worst cases. I am unable to say what number of cases of rickets have come under my notice, but, as is patent, they form a staple commodity in out-patient practice, and it is certainly a very moderate computation to say that in the last six years I must have seen 800 to 1000 cases. It has always been my habit to examine for splenic enlargement, and all such cases have been carefully recorded. Referring to these notes I find fifty-three cases of splenic enlargement of all sorts. They are grouped as follows:

Leucæmic	3
Rachitic (certainly)	16
Rachitic (doubtfully)	7
Cause unascertainable	14
From congenital syphilis	9
Tubercular	5
	54

One of these cases being both syphilitic and rachitic has been included under both heads, explaining the fifty-four total. Now, considering the difficulty which exists in distinguishing slight degrees of rickets, we may include the doubtfully rickety enlargements as rickets, and we have then twenty-three cases. We might even do more, and include those cases in which the enlargement was due to no very obvious cause—a matter of fourteen more, or thirty-seven all told. But they would still—although rachitic enlargements form the greater part of all the splenic cases—form so small a proportion of all the cases of rickets, as can hardly be said to indicate that the enlargement is as much a part of the disease as the changes in the bones. I have called no spleen enlarged which was not certainly palpable below the ribs, or if the chest was sufficiently distorted to explain its altered position.

Digitized by Google

It does not seem, therefore, that the swelling of the spleen can be in any sense essential to rickets, since it occurs so seldom; and I am disposed to agree with Dr. Gee and Dr. Hilton Fagge, that when it occurs it is due to some cause which antedates both it and the bone enlargement.

It may, however, be said that this argument is much weakened by the fact of congenital syphilis, as shown in my own table. Congenital syphilis is very common in the out-patient room; and if we were to enumerate all the cases, and estimate the proportion in which enlargement of the spleen occurs, it would be but a small one—smaller, I think, than that of enlargement of the spleen to rickets. I have notes of nine cases only. But though such a small percentage of all the cases, it is not contested that the splenic enlargement of syphilis is an integral part of the disease, as much as the other signs of the malady. This is all true; but then, on the other hand, there is this difference. The spleen in congenital syphilis, and the liver also, are known to present certain definite cell proliferations, which are similar to those in other parts, and similar to those of syphilis in the adult. This is not so in rickets. The change in the one may be said to be specific, in the other "indifferent."

The liver of rickets appears to be, from my notes, but seldom enlarged, and when it is, the increase is, as Dr. Dickinson has already stated, inconsiderable.

Passing now to the blood and its condition in rickets, I have wondered that no one has hitherto drawn attention to it in this discussion, until our President alluded to the absence of observations on the subject. I know not whether Mr. Hutchinson had in his mind a chemical or microscopical examination or both. Both would be instructive, but a chemical examination of rachitic blood presents difficulties of achievement which I have not surmounted, and I can only speak of microscopical work. Some years ago I examined the blood of many rachitic children; the notes of these were scattered, and have unfortunately been mislaid, but I well remember that in many of them its condition was a very peculiar one, though it was not always the same.

In some there was simple deficiency of corpuscles, in others deficiency of colouring matter; but in most these points were not so noticeable as the remarkable variety which the size of the red corpuscles exhibited. There were three, four, and five different

Digitized by Google

sizes of red corpuscles, these going with a quantity of free granules; beaded strings and dumb-bell aggregations, such as have always been held to be morbid, but the exact significance of which is still doubtful. I have lately, for the purpose of this discussion, turned my attention again to this subject, and verified my former observations, though only in a few cases. Whatever the significance of such changes may be, it cannot be disputed that they may be of considerable importance, and they are in accord, I think, with the view expressed so clearly by Mr. Hutchinson, that rickets is a diet disease. I am quite in accord with such an hypothesis, nor can I see any difficulties in the way of accepting it provisionally, except that it appears to be difficult to prove its truth. Children are either fed badly or assimilate badly; bad blood is formed, and bad bone follows. The microscopical appearances of the blood are such as to suggest both immaturity and poverty. Bad feeding must act primarily upon the blood, but not necessarily by producing always a constant deficiency of one particular element or excess of others, a general lack all round would, it seems to me, be the alteration, which would best supply the conditions which I conceive to be necessary for the production of rickets. If I might venture upon opinions after recording facts, I would say that the histology of rickets point to improper development rather than to disease, and in this light I doubt if rickets, mollities ossium and senile fragilitas ossium have any relation to each other. Rickets is probably a similar process to what is observed when plants are cultivated in foreign soils; put the child under natural conditions and in the great majority of cases the rachitis disappears completely. Have we any parallel disease so severe as rickets which invariably gets well if treated properly?

Dr. F. Dawtrey Drewitt exhibited a *Case of late Rickets (living specimen)*.—The boy whom I have brought to the Society this evening from the Hospital for Sick Children, and who is sitting in the next room helpless and deformed, was, up till nine years of age, a healthy, active child, accustomed to walk to and from school, and to take part in out-of-door games. His father and mother are healthy and strong, and come of long-lived families. He has six healthy brothers and sisters who have not suffered from rickets, nor is there any evidence of hereditary syphilis. His mother states that he was weaned at two months old, and that corn-

Digitized by Google

flour and arrowroot were then given him. That he perspired so much when asleep that she used to wipe the drops off his forehead with a handkerchief; but that he was never tender to the touch, nor felt the weight of his bedclothes; that his teeth came early and were good; that his legs were straight, and that at two years old he could walk well and run. At five years old he began to attend school, and continued doing so until May, 1879, when he was nine years and three months old. At that time his legs became painful and he was unable to walk to school. His mother, too, noticed that they were slightly deformed. The pain on walking then increased, and he could only just move about the room by leaning on chairs and crawling with his hands on the ground. Then the forearms were noticed to be bent, and the deformity of the legs became more marked. A cough from which he had suffered for some months increased in severity, and he rapidly lost flesh. In this state he was brought to the Hospital for Sick Children a year ago and admitted under the care of Dr. Cheadle, whose patient he has remained ever since.

On admission.—The child was greatly deformed,[1] the thorax was distorted owing to the yielding of the ribs. There was marked constriction in the mammary line, and expansion of the border of the chest below. The back is still much rounded, and there is lateral curvature of spine with prominence of the angles of the right ribs. The shoulders are thrust forwards, and the distance between them lessened owing to the bending of clavicles and scapulæ. The sternal ends of the clavicles are enlarged, and there is marked beading of the ribs. There is deformity of all the long bones. In both humeri there is curvature with convexity forwards and outwards, throughout the whole length of the bones, but most marked beneath the deltoids. The radii and ulnæ on both sides are greatly curved, the convexities being outwards, and the principal point of curvature about one and a half inches from the wrist. The ends of the radii and ulnæ at the wrist are both enlarged. There is marked clubbing of the fingers. The abdomen is distended, but liver and spleen are apparently not enlarged. In the femora there is the greatest distortion. The right femur is doubly bent, the upper three fourths presenting a curve with convexity outwards, while the lower fourth is sharply bent backwards at a right angle to the

[1] The photograph well represents his *present* condition. The deformity of the bones is much masked by his having gained flesh. The chest, too, has expanded.

Digitized by Google

rest of the bone. The lower ends of both femora are enlarged, and the right is tender to the touch. The inner condyle of the right tibia is longer than the outer, producing marked genu valgum on that side, so that on flexing the knee the patella is dislocated outwards. The genu valgum is further increased by the curving of the tibia and fibula with convexity inwards. On the left side the femur is curved throughout from before backwards, the sharpest curve being in a corresponding position to that on the right side.

The left tibia is in the same line with the femur, and there is no dislocation of patella on flexing the knee. There is a slight antero-posterior curve in the lower half of the tibia. The ends of both tibiæ are enlarged at the ankles. The toes are slightly clubbed.

The child cannot stand. Attempting to do so causes great pain

WOODCUT 8.

in the knees. He moves in a sitting posture, helping himself along on his hands.

During the first month or two after his admission he had painful

Digitized by Google

swellings, apparently periosteal, on the subcutaneous surfaces and lower ends of the long bones, especially of the tibiæ—also on each ramus of the jaw. On his admission, and for some months previously he suffered from persistent cough. There was general bronchitis of both lungs, with occasional cyanosis, and he coughed up abundant muco-purulent sputa.

Treatment.—At first cod-liver oil was given, but the loss of flesh and tenderness of the bones continued to increase. When, however, owing to the enlargement and tenderness of parts of the bones, iodide of potassium was taken in doses of eight grains, three times a day, the lung symptoms cleared up, the tenderness of the bones disappeared, and the boy began to gain flesh.

The disease is a very curious one, and though occurring in a child of more than nine years of age, and though its course was unchecked by cod-liver oil, while under iodide of potassium the patient rapidly improved. It appears on the whole to resemble rickets more than mollities ossium.[1]

Dr. F. Dawtrey Drewitt also exhibited *Specimens of Rickety Ribs.*—These specimens are horizontal sections through the point of junction of the ribs and costal cartilages. They are taken from children who had some symptoms of rickets during life, but in whom the beading of the ribs could not be detected until *post-mortem*, owing to the enlargement being entirely on the pleural surface of the ribs.

Dr. Hilton Fagge, in his address, has already alluded to the fact that the enlargement may be greater on the inner than the outer surface of the ribs, and these sections very well illustrate that point; for, though the beading was considerable, and even indented the lungs, it could not in any of the cases be diagnosed during life on passing the hand over the chest.

Dr. F. C. Turner exhibited *Specimens from a Case of Rickets.*—The right humerus, radius and ulna, from a well-marked case of rickets, in a child 18 months old, who died in an epileptiform attack. The child was well nourished, and at the autopsy no disease of the viscera was found.

The specimens show—

1. Characteristic changes in the cartilages of the head of the

[1] This case was referred to a committee, whose report appears on page 391.

Digitized by Google

humerus and at the lower end of the radius and ulna, but very little change in those at the elbow-joint. The cartilage, at the upper end of the ulna, shows no appreciable alteration.

2. A very conspicuous formation of spongy bones on the shaft of the bones, especially down the front of the ulna and on the inner surface of the radius at its upper end. In these situations it is as thick as the wall of bone on which it rests.

3. In some parts, as at the lower end of the ulna posteriorly, there is no bony deposit, and then the wall of the shaft is much more compact than where so covered. About the middle of the radius, and at the junction of the two upper thirds of the ulna, the bones are thickened, and the medullary canal is closed for a short distance (? the result of willow fracture). The bones are soft and pliable.

Dr. H. Radcliffe Crocker exhibited a *Specimen of Craniotabes in a Case of Congenital Syphilis.*—The skull-cap was removed from a male child (twin), aged seven weeks, admitted into the East London Children's Hospital under Dr. Eustace Smith. It died two days after admission. It was much emaciated, very small for its age, and had an ulcerating syphilide upon the buttocks. About half an inch behind the parietal eminences, on each side, the skull could be easily indented, and on removal the thinning was very evident, the left side more than the right.

There was no evidence of disease in any of the viscera. The spleen weighed very little over ʒj. The brother had died two days previously with similar symptoms, but was not brought to the hospital.

Dr. Fagge, in reply, expressed his thanks to the various speakers, who had added so much interest to the discussion, which would no doubt be of great use in stimulating research. He had been told that he had misrepresented M. Parrot, but though he had been unable to find the expression he quoted in his published speech, he was of opinion that he had heard him make use of it. He thought it would be well to get rid of the word diathesis, as no two people mean the same when they use the word. For instance, would Sir Wm. Jenner allow with the President that scorbutus was a diathesis? And would the President agree with Sir Wm. Jenner in calling inherited syphilis a diathesis? He was extremely sorry if he had not done justice to Sir Wm. Jenner's lectures on rickets; they were

Digitized by Google

the starting-point of all that is known in this country on the subject. He himself had first learnt what he knew from them, and had constantly referred to them in later years; and it was because he thought he knew the lectures too well that he attributed the observation of the tenderness of the muscles and bones to another source. He should be glad to say anything to induce any one to read the lectures for himself.

Report of Committee appointed to examine Dr. Drewitt's case.—We have to-day examined the boy Henry L—, aged 11, who was exhibited to the Pathological Society by Dr. Drewitt on 21st December, 1880.

We do not think the case one of mollities ossium. In almost every respect it appears to us to be identical with rickets, but we should hesitate to pronounce positively with regard to it, without having had an opportunity of examining the epiphysial ends of the bones histologically.

The case shows no sign of syphilis, and we do not think that the fact of improvement having occurred under the use of iodide of potassium should be taken as suggesting that the condition is of syphilitic origin.

C. Hilton Fagge, M.D.
Warrington Haward.
May 11*th*, 1881. F. Dawtrey Drewitt.

Digitized by Google

Tables illustrating Dr. Lees' and Dr. Barlow's

Table A.—*Craniotabes marked:*

No.	Miscarriages.	Stillborn.	Premature.	Other Children.	No. of this.	Snuffling.		Rash.		Age (Months).	Weight (lbs.).	Suckled.
						Began at	Lasted.	Began at	Lasted.			
1	...	...	...	...	1st	3 mo.	1 mo.	Birth	4 mo.	7	...	...
2	...	...	...	...	...	...	...	...	...	6	13½	Yes
4	...	...	...	Brother snuffled much	...	...	...	...	Several weeks	3½	1½	Yes
6	No	...	...	All 3 have had rash before a month old	3rd	3 mo.	1 mo.	2 mo.	6 wks.	5	14	Yes
7	2	...	...	...	3rd	...	...	7 wks.	4 wks.	3	8	3 wks.
8	No	...	...	1st died at 6 mo.	2nd	Birth	Still	2 days	Still	2¾	7½	No
13	No	...	...	...	2nd	3 mo.	2 mo.	Some doubtful		5	15	Yes
14	No	...	...	...	...	6 wks	6 wks	...	...	3	11	Yes
18	3 at 3 mo.	...	...	1 died at 11 wks.	3rd	...	...	1 mo.	1 mo. 'bad'	3½	12¾	Yes
20	...	...	1st at 8 mo.	Died at 7 hours	2nd	...	...	...	...	6	13¾	...
24	...	1st at 7 mo.	...	2nd died at 3 mo.	3rd	7 wks	Still	1 mo.	2 mo.	5	11	Never
29	No	...	...	...	9th	4½ mo	2 wks	6 wks.	3 wks.	5	11½	Yes
30	2	...	...	3 died under 1 mo. All snuffled and had 'thrush'	5th	...	...	5 wks.	3 wks.	2	6	...
41	...	4 at 7 mo.	1 at 7 mo.	Died at 3 days	6th; 2nd alive	Birth	...	None	...	5	11¼	Never

* Finger-breadths below

Digitized by Google

PAPER ON CRANIOTABES (See page 323).

Syphilis almost certain (35).

Hand-fed.	Snuffles now.	Rash now.	Enlargement of Liver.	Enlargement of Spleen.	Tint.	Bosses.	Remarks.
...	Yes	No	2 f. b.	4 f. b. *	Sallow	4 peri-bregmatic	Cry muffled. Much improved by Hg.
No	Yes	Brown, squamous on chin	2 f. b.	2 f. b.	...	...	Alopecia.
No	Yes	No	...	...	...	...	Rash reached to popliteal spaces.
...	...	...	...	...	...	Left frontal	... ...
Milk; Ridge	No	...	...	No	...	...	Father has undoubted syphilis. Child had typical rash, reaching to ankles (seen).
Yes	Yes	Yes	...	No	...	...	Illegitimate. *P.M.*: thin diffuse cranial osteophytes.
No	Yes	No	...	No	...	...	Died of whooping-cough. *P.M.*: Thin diffuse cranial osteophytes and miliary gummata of liver.
No	Yes	On face	...	...	Pale	...	Typical bone-lesions above elbows and wrists. Some alopecia.
...	Yes	...	...	No	...	...	Hoarse. Rapidly improved by Hg.
...	Slight	Some doubtful	...	1 f. b.	...	...	Hoarse for a week at 4 mo. Improved under free use of Hg.
Cow's milk 1 mo.; Swiss 4 mo.	Marked	...	...	No	...	No	Occasionally blood from nostrils.
Swiss; baked flour	...	...	3 f. b.	2 f. b.	Muddy	...	Voice muffled. Anus pigmented.
...	...	Fading	...	...	Sallow	...	Treated without Hg. for 6 weeks. No improvement. At 3½ mo. weight 6¼ lbs. Ung. hydr. ordered for inunction twice daily. Improved at once and steadily. At 5½ mo. weight 9½ lbs.
Swiss	...	No	...	No	...	...	Slight collapse of nose-bridge.

the margin of the thorax.

Digitized by Google

TABLE A—

No.	Miscarriages.	Stillborn.	Premature.	Other Children.	No. of this.	Snuffling		Rash		Age (Months).	Weight (lbs.).	Suckled.
						Began at	Lasted.	Began at	Lasted.			
44	...	...	...	...	2nd	None	...	Some ful at	doubt- 1 wk.	1¾	6¾	...
47	No	2nd	...	3rd died at 2 hrs.; 6th at 2 mo.	7th	1 mo.	Still	Never	...	3¼	8	Yes
50	1 at 2 mo.	4	...	Only 3 alive out of 12.	12th	3 wks	Still	3 wks.	1 mo.	1¾	...	No
52	No	...	...	1 died at 6 mo. Most had rash very early	6th	2 wks	3 mo.	1 wk.	5 wks.	5	11	2 wks.
63	1 at 3 mo.	...	...	1st died at 7 days	2nd	3 days	Still	1 mo.	Few days	4	10½	3 days
64	No	...	1st, 7 mo.; 2nd, 7 mo.	Both died at 3 wks.	3rd	Birth	Still	2 wks.	1 mo.	6	14	Yes
68	No	No	...	...	2nd	Birth	Much always	2 days	7 wks.	2½	9½	Yes
70	1 at 3 mo.	1st	...	2nd snuffled, had 'thrush' badly within the mouth, lasted 3 mo., 3rd had 'thrush' less severely, did not snuffle.	4th	None	...	None	...	4	17	Yes
71	No	...	...	...	1st	3 wks	2 mo.	5 days	1 wk.	9	9½	Yes
73	No	...	...	All 8 had 'thrush' in mouth and about anus at 1 wk.	8th	Birth	Still	1 wk.	1 wk.	7½	...	3 wks.
74	No	1st	No	Some snuffled.	6th	Birth	...	None	...	8	8½	Yes
75	4—1 at 4 mo., 3 at 3 mo.	3rd	1st, 8 mo.; 4th, 6½ mo. 5th, 7 mo.	1st died at 2 wks., 4th at 8 days	5th	Birth	3 mo.	3 mo.	1 wk.	6	12	Never
76	No	No	1st, 8 mo; 5th, 8 mo.	3rd had rash on bottom for 6 wks.	9th	Birth	3 mo.	1 wk.	...	8	12¾	Never

Digitized by Google

continued.

Hand-fed.	Snuffles now.	Rash now.	Enlargement of Liver.	Enlargement of Spleen.	Tint.	Bosses.	Remarks.
...	No	No	...	No	...	...	*P.M.* : Osteitis of orbital plates and temporal bones. Softening gumma of brain. Meningitis.
No	Yes	No	...	No	...	...	Hoarse. Collapse of nose-bridge.
Swiss	Yes	Distinct	...	No	...	...	*P.M.* : Thin diffuse cranial osteophytes.
Cow's milk; Robb	Marked	No	...	No	Pale	? on frontals	... ...
Swiss; Robb	Yes	No	...	No	...	...	Mother had good health before marriage. Had alopecia after first confinement.
Partly	Slight	No	...	Probable	...	Doubtful	... ...
Yes	Yes	No	...	No	...	No	... ...
Bread and milk	Slight dry	Some desquamation occiput	...	No	...	...	Gradually diminishing syphilis.
Cow's and Robb	No	No	2 f. b.	2 f. b.	Sallow	No	Cry not quite clear. Cries on gentle handling. Nasal discharge 'mattery.' Slight collapse of nose-bridge.
Cow's and Ridge	Yes	No	2 f. b.	2 f. b.	Yellowish	No	Vaccination-vesicles broke before 1 week; did not heal for 3 mo. Sore behind ear for 3 mo.
Cow's and bread	No	Purpura	6 f. b.	4 f. b.	Greenish	Doubtful	Mother has had genital sores, and has scars on throat and on face.
Cow's and Ridge	Slight dry	No	...	No	No	Distinct both frontals	... ...
Swiss and Ridge	No	Squamous on nates	...	No	Sallow	4 small peri-bregmatic	Fissure at angle of mouth. Cries on gentle handling.

Digitized by Google

TABLE A—

No.	Miscarriages.	Stillborn.	Premature.	Other children.	No. of this.	Snuffling		Rash.		Age (months).	Weight (lbs.).	Suckled.
						Began at	Lasted	Began at	Lasted			
80	No	1st	...	All snuffled from birth a few days	6th	Birth	At times	None	...	8	10½	Yes
81	1 at 4 mo.	...	...	...	2nd	Birth	Still	3 wks.	3 wks.	12½	15¾	Never
82	0 at 3 mo.	...	...	...	7th	None	...	2 wks.	Several weeks	6	13½	Yes
87	No	...	...	...	3rd	7 wks	Still	3 wks.	4 mo.	11	12½	3 wks.
88	1	1st	1 at 8 mo.	...	3rd	Birth	Still	...	...	2¾	11½	Always
90	2—1 at 7 wk., 1 at 8 wk.	...	...	...	1st	3 wks	5 wks	3 wks.	3 wks.	3	9½	Yes
93	No	...	...	...	1st	2 mo.	Still	2 mo.	3 mo.	11½	9	2 wks.
94	4—1 at 6 wk., 3 at 3 mo.	...	...	1 died at 10 mo.; 1, 5 mo.; 1, 3 days	13th	Early	'Few days'	3 wks.	1 wk.	5	12½	4 mos.

Digitized by Google

continued.

Hand-fed.	Snuffles now.	Rash now.	Enlargement of Liver.	Enlargement of Spleen.	Tint.	Bosses.	Remarks.
Cow's now	No	Purpura	2½ f. b.	4 f. b.	Earthy	No	... ...
Cow's and baked flour	Yes	No	...	No	No	Distinct both frontals	... ...
Cow's and bread	Distinct	No	...	No	...	No	Rash on genitals and reached to heels. Vaccination sores did not heal for 8 mo.
Cow's and Ridge	Yes	Some eczema	...	1 f. b.	...	Doubtfull	Rash involved trunk and limbs.
No	Distinct	No	...	No	...	...	Hoarse cough.
Robb	No	Erythema	...	1 f. b.	Pale	No	Improved and fattened under hyd. cum cretâ.
Swiss and Savory	Yes	No	...	No	...	...	Nasal discharge at times purulent and with blood. Cries on gentle handling.
Swiss and oatmeal	Decided	No	...	No	...	4 small peribregmatic	Most of the thirteen children have snuffled and had rash before a month old. One died at one year and ten months—snuffled all his life.

Digitized by Google

TABLE B.—*Craniotabes slight:*

No.	Miscarriages.	Stillborn.	Premature	Other Children.	No. of this.	Snuffling		Rash		Age (Months).	Weight (lbs.).	Suckled.
						Began at	Lasted.	Began at	Lasted.			
3	...	...	...	...	...	...	...	...	...	10	17	Yes
21	...	7th at 7 mo.	...	5th died at 6 mo., 8th died at 3 mo. They snuffled much	9th	Birth	Still slight	Some doubtful		3½	9½	2 mo.
32	No	...	...	...	1st	...	...	...	...	8	14½	...
40	No	...	...	...	1st	5 mo.	3 mo.	...	...	8	?	2 mo.
49	...	...	...	...	...	...	...	...	...	5	?	...
54	No	...	...	...	3rd	Birth	...	1 mo.	2 mo.	3	12½	Yes
62	No	No	This 8 mo.	...	1st	2 mo.	...	Never	...	10	?	No
65	No	...	...	...	4th	Birth	1 mo.	3 wks. 'all over'	...	5½	12½	Yes
78	2 at 6 and 3 mo.	...	Both at 8 mo.	1st died at 5 mo.	2nd	Birth	Still	None	...	6	13	Yes
95	1 at 4 mo.	...	This 8 mo.	...	1st	3 wk.	6 wks. and relapsd	3 wks.	2 mo.	9	13¾	4 mo.
99	No	...	...	These were twins	...	'Very early'	Still	None	...	10	...	6 wks.
100	No	...	...		...	...	...	1 mo.	...	10	...	...

* Finger-breadths below

Digitized by Google

Syphilis almost certain (12).

Hand-fed.	Snuffles now.	Rash now.	Enlargement of Liver.	Enlargement of Spleen.	Tint.	Bosses.	Remarks.
Sop	Yes	...	...	3 f.b.*	...	4 large peri-bregmatic	... ...
Swiss	No	No	...	No	...	...	*P.M.*: Thin diffuse osteophytes on parietals. All the children have snuffled much; the surviving ones are stunted in growth.
...	Slight	...	...	1 f. b.	...	2 large frontal	Depressed nose-bridge.
Cow's & biscuit	Severe	...	...	...	...	2 frontal	*P.M.*: Bosses on frontals. Extensive thin maroon-coloured osteophytes over nearly whole of parietals and occipital.
...	Slight	Pigmentation, occiput and thighs	...	2 f. b.	...	...	Nose-bridge *much* collapsed. Voice altered. Inflammation of growing ends of bones of both forearms.
No	Dry	Extensive typical	...	No	...	...	... ...
Yes	Slight	No	...	Noted at 2½ mo.	Sallow	Very marked	*P.M.*: Extensive bossy osteophytes. In the early months of this pregnancy the mother had a rash which lasted three weeks.
Rusks	No	Dry eczema on head	...	No	Sallow	No	Alopecia of scalp and eyebrows. Vaccination-sores long in healing. Died of pleurisy. *P.M.*: Diffuse osteophytes on parietals and occipital.
No	Marked	No	...	No	Good	No	... ...
Cow's; bread; potato	No	No	...	No	Muddy	Probable on frontals	Collapse of nose very marked. Mother has had rheumatic pains only since marriage, and has lost her hair since the confinement.
Cow's; bread	Yes	No	...	3 f. b.	Yellowish	On frontals	Improved, and craniotabes vanished and spleen diminished, but bosses and snuffles remained under the use of ung. hydrargyri *only*.
...	Collapse of nose	...	...	2 f. b.	...	On frontals and parietals	Improved, and craniotabes and spleen vanished, but bosses remained under ung. hydrargyri *only*.

the margin of the thorax.

Digitized by Google

TABLE C.—*Evidence as to Rickets (if*

Age in Months.	Evidence of Syphilis.	Suckled.	Hand-fed.	Ordinal Number.	Head-Sweating.	Tenderness.	Feces.	Laryngismus.
2	...	Wholly	...	2nd	...	...	Offensive	...
2¼	...	Wholly	...	3rd	Much	...	...	...
2¼	Decisive	Partly	Partly	2nd	Yes	Cries when washed	...	...
2½	Some	Never	Cow's	6th	...	...	Offensive	...
2¾	Decisive	Wholly	...	3rd	...	...	...	...
3	...	Wholly	...	4th	Yes	...	Green	...
3	Decisive	Wholly	...	3rd	...	...	...	...
3	...	2 mo.	Cow's 1 month	3rd	...	...	...	Doubtful
3	Some	1 mo.	Cow's; Ridge	1st	...	...	Frequent	...
3	Decisive	Partly	Robb	1st	A little	...	Offensive	...
3½	Some	1 mo.	Cow's; Robb	3rd	...	...	...	...
3½	...	Wholly	...	6th	...	...	...	...
3½	Decisive	Wholly	...	7th	...	...	...	...
4	Decisive	3 days	Swiss; Robb	2nd	Slight	...	...	...
4	Decisive	Partly	Bread and milk	4th	Yes	...	Costive	Occasional
4	Some	Wholly	...	4th	...	...	Offensive green	...
4	Some	Partly	Cow's; biscuits	3rd	Occasional	...	Offensive green	...
4	Some	Almost wholly	A little	3rd	...	...	...	...
4¼	Some	1 week	Cow's	1st	Much	...	Offensive	Doubtful
5	Decisive	2 weeks	Cow's; Robb	6th	Slight	...	Costive	...
5	...	Wholly	...	8th	...	...	...	...
5	Decisive	4 mo.	Swiss; oatmeal	13th	...	...	Offensive	...
5	Decisive	Never	Swiss, &c.	12th	...	...	...	...
5½	...	Partly	Biscuits	1st	Much	...	Offensive	...
5½	Decisive	Partly	Rusks	4th	Yes	...	...	...
6	Some	Partly	Ridge; Savory	2nd	...	...	...	...
6	Some	Never	Cow's; Ridge	2nd	Frequent	Some, lately	Green	...
6	Decisive	Partly	Partly	3rd	...	...	...	...
6	...	Partly	Boiled bread since birth	3rd	Yes	...	Offensive	...
6	Decisive	Never	Cow's; Ridge	5th	Much	...	Offensive	...
6	Decisive	Wholly	...	2nd	Slight	...	Slight	...

Digitized by Google

any) in Fifty-three Cases of Craniotabes.

Fits.	Teeth.	Enlargement of Epiphyses.	Curvature of Bones.	Beads on Ribs.	Grooves on Thorax.	Enlargement of Liver.	Enlargement of Spleen.
...	...	...	...	...	...	...	...
...	...	...	...	...	...	...	...
...	...	...	...	...	...	...	...
...	...	...	...	...	...	...	...
...	...	...	...	...	...	...	...
...	...	...	...	...	...	1 f. b.	...
...	...	...	...	...	...	1 f. b.	...
...	...	...	...	...	...	½ f. b.	...
...	...	...	...	...	...	...	...
...	...	...	...	...	...	½ f. b.	½ f. b.
...	...	...	...	...	...	...	...
...	...	...	...	...	...	...	...
...	...	...	...	...	...	...	...
...	...	...	...	Very slight	...	...	...
...	...	...	...	Very slight	...	...	...
...	...	...	...	...	...	1½ f. b.	1½ f. b.
...	...	...	...	Small	Very slight longl. and transverse	...	1 f. b.
...	...	...	...	Almost nil	...	...	...
...	...	...	...	Distinct	Slight longl. and transverse	1 f. b.	...
...	...	...	...	Distinct	...	...	...
...	...	...	...	...	...	...	...
...	...	...	...	Distinct	...	...	...
...	...	Slight, wrists	...	Slight	...	...	2 f. b.
...	...	...	...	Slight	...	2 f. b.	...
...	...	...	...	...	...	1 f. b.	...
...	...	...	...	Very slight	...	1 f. b.	...
...	...	...	...	Decided	...	...	...
...	...	...	...	Very slight	...	...	Probable
...	...	Slight, wrists	...	Yes	Moderate transverse	...	...
...	...	Wrists, ankles.	...	Marked	Transverse	...	...
...	...	...	...	...	...	½ f. b.	...

Digitized by Google

TABLE C—

Age in Months.	Evidence of Syphilis.	Suckled.	Hand-fed.	Ordinal Number.	Head-Sweating.	Tender-ness.	Fæces.	Laryngis-mus.
6	Some	Wholly	...	1st	Much first 2 mo.; not since	...	...	...
6	Decisive	Partly	Cow's; bread	7th	1 week only	1 week only	...	...
6	Some	7 weeks	Milk Ridge	6th	Much	...	Offensive slimy	...
6	Some	Partly	Robb	1st	Yes	...	...	Doubtful
7	Some	Partly	Partly	1st	Yes	Last few days	...	...
7½	Decisive	3 weeks	Cow's; Ridge	8th	...	Some at 5 months	Costive	Yes
8	Decisive	Partly	Cow's; bread	6th	For 3 mo.	...	Variable	...
8	Decisive	Never	Swiss; Ridge	9th	Yes	Yes	Slimy	Occa-sional
8	Decisive	Partly	Cow's	6th	Much last 3 months	...	...	...
8½	...	6 mo.	Bread and milk	5th	Occasional	...	Loose	Yes
9	Decisive	Partly	Cow's; Robb	1st	Yes	Some	Offensive	Yes
9	Some	Partly	Cow's; Robb	5th	2 weeks only	...	...	...
9	Decesive	4 mo.	Cow's; bread; potatoes	1st	1 month	...	...	...
9	Some	2 weeks	Swiss; bread	5th	Much	...	Offensive	...
10	Some	2 weeks	Swiss; Savory	1st	Yes	Some	...	...
10	Decisive	6 weeks	Cow's; bread	?	...	...	...	...
11	Decisive	3 weeks	Cow's; Ridge	3rd	Much	...	Offensive green	...
11½	...	4 mo.	Since 4 months	1st	?	?	?	?
11¾	Decisive	2 weeks	Swiss; Savory	1st	'Much always'	'Always'	Offensive	...
12½	Decisive	Never	Cow's; baked flour	2nd	Much last 4 months	Marked 4 months ago	Offensive	...
18	Some	Never	Swiss; biscuits since 8 mo.	2nd	...	At 12 months	...	...
19	No history	7 mo.	?	5th	?	?	?	?

Digitized by Google

continued.

Fits.	Teeth.	Enlargement of Epiphyses.	Curvature of Bones.	Beads on Ribs.	Grooves on Thorax.	Enlargement of Liver.	Enlargement of Spleen.
...	...	...	...	...	...	1 f. b.	...
...	...	...	...	Some	Slight	...	...
...	...	...	...	Very slight	...	...	...
...	...	...	...	Almost nil	...	3 f. b.	3 f. b.
11 in all	...	...	...	Decided	...	1½ f. b.	3 f. b.
...	...	...	...	Distinct	...	2 f. b.	2 f. b.
...	...	...	...	Moderate	Some longtl.	3 f. b.	4 f. b.
...	...	...	...	Yes	Slight	...	...
...	...	Slight, wrists	...	Decided	Longl. and transverse	2½ f. b.	4 f. b.
...	2 cut at 8 months	...	...	Marked	Commencing transverse	...	...
...	None	Slight, wrists	...	Slight	Slight transverse	2 f. b.	2 f. b.
...	None	...	...	Very slight	...	2 f. b.	3 f. b.
...	None	...	...	Slight	Very slight	...	...
...	2 cut at 9 months	Slight, wrists and ankles	...	Decided	Some transverse	1 f. b.	1 f. b.
...	None	...	...	Slight	Very slight	...	...
8 at 8 months	None	...	...	Large	...	2 f. b.	3 f. b.
...	None	Wrists	...	Decided	Longl. and transverse	...	...
?	6	Wrists	...	Large	Some	...	...
...	None	...	Radius	Distinct	Slight	...	...
Frequent from 3 to 6 wks. old	None	Ankles, wrists	Spine	Large	...	...	...
...	None till 14 mo	?	Radius, clavicles	Large	?	...	...
?	2	Wrists	...	Yes	...	1 f. b.	...

Digitized by Google

Postscript to Dr. Lees' and Dr. Barlow's paper on craniotabes.—Since this paper was written we have met with two cases of infants, certainly not syphilitic, in which a slight depression of the parietals could be obtained on rather firm pressure. Both seemed to be in every respect healthy and free from rickets; one was suckled, the other fed on Swiss milk. In the latter the yielding was noticed at the age of five months, in the former at three and a half months, and in a month afterwards it had disappeared. But the extent of yielding in these cases was very slight indeed in comparison with what one finds in definite cases of craniotabes. It seems possible that the thinning of the posterior part of the skull in infant life, which Friedleben claims to be a normal process, may be connected with the commencing formation of the pits which correspond with the convolutions. It is certain that these pits do not exist at birth and in their formation some absorption of the inner plate no doubt occurs. Given that the bone becomes softened by syphilitic deposit, our view would be that the physiological thinning becomes extreme and passes into the morbid condition—craniotabes. Thus, without maintaining that craniotabes is necessarily a syphilitic sign, we should hold that it is much more likely to occur in a syphilitic child than in any other.

Digitized by Google

INDEX.

ABERCROMBIE (*John*), congenital cyst in larynx . . . 33
„ congenital imperfection of septum ventriculorum, with ante-mortem thrombosis of right ventricle and pulmonary artery 73
„ disease of right shoulder- and right hip-joint in an infant . . 192
„ extra-renal growth 205
„ case of scleroderma 266
ABSCESS of liver in a child (Norman Moore) . . . 132
„ — consequent upon dysentery contracted in England (W. H. Dickinson) 127
„ — opened by aspiration, and then by direct incision, death on sixth day (Sir J. Fayrer) 119
„ — multiple, and acute dysentery (Sir J. Fayrer) . . . 123
ADAMS (*William*), *post-mortem* examination of Sir J. Fayrer's case of abscess of the liver 121
ADENOID DISEASE of the rectum (cancer), (W. H. Cripps) . . 87
ADENOMA of upper jaw (R. Parker) 239
„ acinous, of right breast (R. Parker) 237
„ — of tip of nose (R. Parker) 238
„ tubular, of left breast (R. Parker) 238
„ — of root and dorsum of tongue, submucous (R. Parker) . . 238
ADENO-MYXOMA, hyaline, of breast (R. Parker) . . . 236
AINHUM, cases of (A. Crombie) 302
ANDERSON (*W.*), syphilitic disease of the cerebral arteries . . 55
„ case of long retention of the ivory pegs in Dieffenbach's operation for pseud-arthrosis 170
ANEURYSM of middle cerebral artery in a boy of twelve, rupturing into descending cornu of the lateral ventricle (S. West) 69
„ of the anterior communicating artery of the circle of Willis (W. M. Ord) . 65
„ of the left posterior communicating artery (S. West) . . . 66
„ of the pulmonary artery (S. West) 67
ANEURYSMAL dilatation and rupture of aortic valve (S. West, for L. Humphry) 77
ANIMALS, LOWER, SPECIMENS from . . . 311-12
AORTA arising from both ventricles (T. B. Peacock) . . . 35
„ calcareous degeneration of the (R. W. Burnet) . . . 78
„ ARCH of the, rupture of, from injury (Jer. McCarthy) . . 54
AORTIC APERTURE, atresia of, in an infant (S. G. Shattock) . . 38
AORTIC VALVES, aneurysmal dilatation and rupture of (S. West, for L. Humphry) 77
„ disease of, in a case of mitral and tricuspid stenosis (R. E. Carrington) . 75
AREOLA and NIPPLE, connection between disease of, and tumours of the breast (G. Thin) 218

Digitized by Google

ARM, &c., arrested development and growth of (S. G. Shattock) . . 276
ARMS, truncated, bearing at the ends fœtal hands voluntarily mobile, two cases (R. Barwell) 280
ARTERIES, CEREBRAL, syphilitic disease of (W. Anderson) . . 55
„ MIDDLE CEREBRAL, see *Aneurysm* of.
„ — embolism in, in cancer of right lung (N. Moore) . . . 32
„ ANTERIOR COMMUNICATING of the circle of Willis, see *Aneurysm*.
„ POSTERIOR COMMUNICATING, see *Aneurysm*.
„ MESENTERIC, and VEIN, obstruction of, followed by intestinal and peritoneal hæmorrhage, fatal (F. Taylor) 61
„ PULMONARY, see *Aneurysm*.
„ — stenosis of orifice of, in malformation of heart (T. B. Peacock) . 35
„ — thrombosis in, causing gangrene of the lung (B. G. Morison) . 23
„ — penetrated by ulcer of right bronchus (N. Moore) . . 33
ARTHRITIS, rheumatic, joints showing changes characteristic of, and of gout (J. Hutchinson) 193
ASTRAGALUS, comminuted fracture of, with subastragaloid dislocation of the foot outwards and backwards (H. Morris) 156
ATRESIA of the aortic aperture in an infant (S. G. Shattock) . . 38
AXIS, ANTERO-POSTERIOR, partial dislocation of foot by rotation round its (H. Morris) 158
BAKER (*W. Morrant*), ostitis of the femur 165
„ circumscribed scleroderma affecting the face and scalp . . 261
„ *report* on ditto by the Committee (J. Hutchinson, P. H. Pye-Smith and John Cavafy) 262
„ *for Dr. Gregory White*, acute necrosis of the tibia . . . 163
„ *report* on Dr. Cavafy's case of abnormal pigmentation of the skin . 260
BALDING (*Mortimer*), *per Sidney Coupland*, congenital malformations of hand and feet 190
BARLOW (*Thomas*), *remarks* in the DISCUSSION ON RICKETS . 323, 364
BARROW (*A. Boyce*), stenosis of tricuspid and mitral valves, with contraction of the aortic semilunar valves, in a boy fourteen years of age . . 74
BARWELL (*Richard*), two cases of truncated arms, bearing at the ends fœtal hands voluntarily mobile 280
„ unilateral hypertrophy of the head and face, involving bones and soft parts, 282
BAXTER (*E. B.*), *remarks* in the DISCUSSION ON RICKETS . . 360
BECK (*Marcus*), *report* on Mr. Hutchinson's case of tumour of the leg . 231
„ *report* on Mr. R. W. Parker's case of adeno-fibroma and carcinoma . 235
BELL (*H. Royes*), case of excision of the anterior third of the tongue for epithelioma, followed by gangrene of the lung 26
BLADDER, epithelioma of, following removal of a calculus (J. N. Davies-Colley) 139
„ squamous epithelioma of, with secondary growths in left lung (R. J. Godlee) 30
„ villous polyp of the bladder (F. Treves) 141
BLOOD from a patient who died of diabetes (N. Moore) . . 72
BONES, DISEASES of 152-193
BRAILEY (*W. A.*), remarkable case of chronic hydrocephalus (with cyst beneath tentorium) 1
„ *remarks* on ditto by Professor Humphry 3
BRAIN, &c., gummatous disease of, and of cranial bones and vertebræ (F. Jordan) 15
„ of a child aged five months: pyocephalus (N. Moore) . . 6

Digitized by Google

BREAST, acinous adenoma of right (R. Parker) . . . 237
„ tubular adenoma of left (R. Parker) 238
„ hyaline adeno-myxoma of (R. Parker) 236
„ cancer of, following eczema of nipple (H. M. Jones) . . . 242
„ cystic degeneration of (C. M. Moullin) 215
„ tumours of, connection of disease of nipple and areola with (G. Thin) . 218

BRONCHUS, RIGHT, ulcer of, penetrating the pulmonary artery (N. Moore) . 33

BURNET (*R. W.*), heart with calcareous plates . . . 53
„ calcareous degeneration of the aorta 78

BUTLIN (*H. T.*), round-celled sarcoma, with hyaline degeneration (cylindroma) of the popliteal space 210
„ squamous epithelioma of the upper jaw 212
„ paper on "disease of the nipple," reference to . . . 226
„ *report* on Mr. Moullin's specimen of cystic degeneration of the breast . 217

CALCAREOUS degeneration of the aorta (R. W. Burnet) . . 78
„ plates, heart with (R. W. Burnet) 53

CALCULI, vesical, spontaneous disintegration of (Wm. M. Ord) . . 304
„ — large (Surg.-Major Curran) 310
„ — from a dog (F. Treves) 311

CALCULUS, removal of a, followed by epithelioma of bladder (J. N. Davies-Colley) 139

CANCER of right lung with embolism in middle cerebral artery (N. Moore) . 32
„ of mamma following eczema of the nipple (H. M. Jones) . . 242
„ of right pleura, following cancer of right mamma successfully removed two years before (Samuel West) 227
„ of the rectum (W. H. Cripps) 87
„ colloid, of peritoneum invading the spleen (W. M. Ord) . . 214

CARRINGTON (*R. E.*), nutshell impacted in the larynx, tracheotomy, membranous tracheitis, and purulent bronchitis, collapse of lung . . . 16
„ case of mitral and tricuspid stenosis, with concurrent disease of the aortic valves 75

CARTILAGE, hyaline, epulis containing masses of (H. A. Lediard) . 244

CAVAFY (*John*), a case of abnormal pigmentation of the skin following jaundice 258
„ — *report* on ditto by committee (J. Hutchinson, P. H. Pye-Smith, and W. M. Baker) 260
„ *report* on Mr. M. Baker's case of circumscribed scleroderma . . 262

CHEEK, congenital fibro-cystic nævoid tumour of (J. Hutchinson) . 240

CHEIRO-POMPHOLYX (H. M. Jones) 272

CIRCLE OF WILLIS, ANTERIOR ARTERY of, see *Aneurysm of*.

CIRCULATION, ORGANS of, DISEASES, &c., of . . 35-78

CIRRHOSIS of liver in a child (N. Moore) 132
„ — in a child, with congenital hydrocele (S. Osborn) . . 133

CLAVICLE, sarcoma of (H. M. Jones) 242
„ sequestrum of (H. M. Jones) 192

COBBOLD (*T. C.*), on filaria sanguinis hominis, *referred to* . 286-7

COLLEY, see *Davies-Colley*.

Digitized by Google

COMMITTEE ON MORBID GROWTHS, REPORTS:
„ on C. M. Moullin's specimen of cystic degeneration of the breast (H. T. Butlin and J. F. Goodhart) 217
„ on Jonathan Hutchinson's case of tumour [epithelial ulcer] of the leg (M Beck and R. J. Godlee) 231
„ on R. Parker's case of adeno-fibroma and carcinoma of the same breast (M. Beck and R. J. Godlee) 235
CORACOID PROCESS, fracture of, followed by fibrous repair (S. G. Shattock) 155
COUPLAND (*Sidney*), see *Balding* (*M.*).
CRANIUM, BASE of, dermoid tumour growing from (W. Hale White) . 201
CRIPPS (*W. Harrison*), adenoid disease of the rectum (cancer) . . 87
CRISP (*Edwards*), *remarks* in the DISCUSSION ON RICKETS . . 331
CROCKER (*H. Radcliffe*), *specimen shown* in the DISCUSSION ON RICKETS . 390
„ the histology and pathology of molluscum contagiosum . . 254
CROFT (*John*), tubercular disease of synovial membranes, and tubercular disease of joints 174
„ — *microscopical report* on the cases of ditto, by W. S. Greenfield . 177
CROMBIE (*A.*), *per Mr. Jonathan Hutchinson*, ainhum . . 302
CURRAN (*Surgeon-Major*), *per Dr. Fr. Taylor*, vesical calculi . . 310
CYLINDROMA of the popliteal space (H. T. Butlin) . . . 210
CYST, congenital, in larynx (J. Abercrombie) . . . 33
„ proliferating, in the ovary of a seven months' fœtus (A. Doran) . 147
CYSTIC DEGENERATION, see *Degeneration* (*cystic*).
„ disease of the liver and of both kidneys (P. H. Pye-Smith) . . 112
DAVIES-COLLEY (*J. N.*), epithelioma of bladder, following removal of a calculus 139
DAY (*W. H.*), case of sarcoma of the right kidney confined to the capsule . 142
DEGENERATION, calcareous, of the aorta (R. W. Burnet) . . 78
„ — see *Calcareous Plates*.
„ cystic, of breast (C. M. Moullin) 215
„ hyaline, of popliteal space (H. T. Butlin) 210
DERMOID, see *Tumour* (dermoid).
DEVELOPMENT and growth, arrested, of the right upper limb in man (S. G. Shattock) 276
DEVIS (*C. J.*), *per J. F. Payne*, case of acute myositis of thigh . . 273
DIABETES, blood from a patient who died of (N. Moore), . . 72
„ insipidus, tumour of optic tract from a case of (N. Moore) . . 5
DICKINSON (*W. Howship*), abscess of the liver consequent upon dysentery contracted in England 127
„ *remarks* in the DISCUSSION ON RICKETS 336
DIEFFENBACH'S operation for pseudarthrosis, long retention of the ivory pegs in (W. Anderson) 170
DIGESTION, ORGANS of, DISEASES, &c., of . . . 79-138
DILATATION of the central canal of the spinal cord (N. Moore) . . 7
DISCUSSION on the pathology of RICKETS 313
„ see under *Rickets*.
DISEASES, &c., OF THE NERVOUS SYSTEM 1-15
„ of the ORGANS OF RESPIRATION . . . 16-34
„ of the ORGANS OF CIRCULATION . . 35-78

Digitized by Google

DISEASES, &c., of the ORGANS OF DIGESTION . . 79-138
„ of the GENITO-URINARY ORGANS . . . 139-151
„ of the OSSEOUS SYSTEM 152-193
„ MORBID GROWTHS 194-244
„ of the SKIN 245-272
„ MISCELLANEOUS SPECIMENS 273-310
„ SPECIMENS from the LOWER ANIMALS . . . 311-312
DISLOCATION of the patella, old outward (C. J. Symonds) . . 193
DOG, vesical calculus from a (F. Treves) 311
DORAN (*Alban*), proliferating cysts in the ovary of a seven months' fœtus . 147
„ *microscopic examination* of the so-called abscesses of the liver in Sir Jos. Fayrer's case of acute dysentery 126
DREWITT (*F. G. Dawtrey*), *remarks* in the DISCUSSION ON RICKETS . 386
DUCTUS ARTERIOSUS, closed, in malformed heart (T. B. Peacock) . 35
DYSENTERY contracted in England, abscess of liver consequent on (W. H. Dickinson) 127
„ acute, and liver abscess; the liver and large intestine of a case of multiple abscess (Sir J. Fayrer) 126
" chronic, and abscess of the liver, opened by aspiration and then by incision; death on sixth day (Sir J. Fayrer) 119

ECZEMA of the nipple, cancer of mamma following (H. M. Jones) . 242
EDMUNDS (*Walter*) external hydrocephalus 4
ELBOW-JOINT, tubercular disease of (G. H. Makins) . . . 189
EMBOLISM in middle cerebral artery, in cancer of right lung (N. Moore) . 32
ENCHONDROMA, fibro- (H. A. Lediard) 244
EPITHELIOMA of bladder following removal of a calculus (J. N. Davies-Colley) 139
„ arising in an ulcer of the leg (C. J. Symonds) . . . 244
„ recurrence of, in the lung; two cases (R. J. Godlee) . . 27
„ of tongue, with secondary growths in the lungs, &c. (R. J. Godlee) . 27
„ excision of third of the tongue for, followed by gangrene of the lung (H. Roger Bell) 26
„ round-celled acinous, or adenoma of upper jaw (R. Parker) . . 239
„ columnar, of antrum of upper jaw (R. Parker) . . . 239
„ squamous, of the bladder, with secondary growths in left lung (R. J Godlee) . 30
„ — of the upper jaw (H. T. Butlin) 212
EPULIS containing masses of hyaline cartilage (H. A. Lediard) . . 244
EVE (*Frederic S.*), sarcoma of the lower extremity of the femur, extending into the knee-joint, and simulating destructive disease of the joint . . 169
„ symmetrical exostoses of the inferior maxilla . . . 170
EXCAVATION, see *Lung*.
EXCISION of third of the tongue for epithelioma, followed by gangrene of the lung (H. Royes Bell) 26
EXOSTOSES, symmetrical, of the inferior maxilla (F. S. Eve) . . 170
FACE, circumscribed scleroderma affecting (W. M. Baker) . . 261
FACE and HEAD, unilateral hypertrophy of, involving bones and soft parts (R. Barwell) 282
FAGGE (*C. Hilton*), *opening remarks* in the DISCUSSION ON RICKETS . 313
„ *remarks*, a *reply* on ditto 391

Digitized by Google

FAYRER (*Sir Joseph*), chronic dysentery and abscess of the liver, opened first by aspiration and then by direct incision, antiseptical precautions, death sixth day 119
„ *post-mortem* examination of the case by Wm. Adams . . 121
„ acute dysentery and liver abscess; the liver and large intestines of a case of multiple abscess 123
„ *microscopic examination* of the abscesses of the liver in the case, by Alban Doran 126
FEET, malformation of (M. Balding) 190
„ see *Foot*.
FEMUR, ostitis of the (W. M. Baker) 165
„ osteo-sarcoma of lower end of (H. M. Jones) . . . 242
„ sarcoma of the lower extremity of, extending into knee-joint (F. S. Eve) . 169
FENWICK (*Bedford*), two cases of extreme stenosis of the tricuspid orifice (with table of forty-six recorded cases) 42-48
FIBROID TUMOUR, see *Tumours* (fibroid).
FIBROUS TUMOURS, see *Tumours* (fibrous).
FIBROUS repair following fracture of coracoid process (S. G. Shattock) . 155
FIBULA, congenital absence of, and of two toes, and talipes equino-valgus (A. R. Gould) 152
FILARIA *in situ*, in a lymph scrotum (P. Manson) . . . 285
„ sanguinis hominis, history of its relations with the mosquito . 291-293
„ endemic character of, in South China 294
FINGER, congenital tumour at the extremity of, in an infant (Jon. Hutchinson) 241
FINGERS, cartilage tumours in the bones of (Jon. Hutchinson) . . 241
FŒTAL STRUCTURES in a congenital tumour removed from the sacrum of a child (C. Macnamara) 199
FŒTUS, seven months', proliferating cysts in the ovary of a (A. Doran) . 147
FOOT, partial dislocation of, by rotation round its antero-posterior axis, in a fracture of the inner malleolus (H. Morris) 158
„ subastragaloid dislocation of, outwards and backwards (H. Morris) . 156
„ see *Feet*.
FORAMEN OVALE, defects in the fold of, in malformed heart (T. B. Peacock) 35
FRACTURE, comminuted, of the astragalus, &c. (H. Morris) . . 156
GANGRENE of the lung from thrombosis in pulmonary artery (B. G. Morison) 23
„ — following excision of tongue for epithelioma (H. Royes Bell) . 26
GEE (*Samuel Jones*), *remarks* in the DISCUSSION ON RICKETS . . 349
GENERATION, ORGANS of, DISEASES, &c., of . . 139-151
GENU VALGUM (H. Morris) 160
GLIOMA of the spinal cord (T. T. Whipham) . . . 8
GODLEE (*R. J.*), two cases in which epithelioma recurred in the lung . 27
„ fibro-cellular tumour removed from the interior of the knee-joint . 207
„ *report* on Mr. Hutchinson's case of tumour of the leg . . 231
„ *report* on Mr. R. W. Parker's case of adeno-fibroma and carcinoma . 235
GOODHART (*James F.*), perforating ulcer of the stomach, leading to fatal hæmatemesis, thirty hours after birth 79
„ cicatrices in the liver, the result of suppurative pylephlebitis . . 137

Digitized by Google

GOODHART (*James F.*) *remarks* in the DISCUSSION ON RICKETS . 382
„ *report* on Mr. Moullin's specimen of cystic degeneration of the breast . 217
GOULD (*A. Pearce*), congenital absence of fibula and two toes, and talipes equino-valgus (*living specimen*) 152
„ congenital mucous polypus of umbilicus 204
GOUT, joints showing changes characteristic of, and of rheumatic arthritis (J. Hutchinson) 193
GREENFIELD (*W. R.*), *microscopical report* on Mr. Croft's cases of tuberculosis of synovial membrane, and of joints 177
GROWTH, arrested, of the right upper limb (S. G. Shattock) . . 276
GROWTHS, MORBID 194-244
GUMMATOUS disease of brain, cranial bones, and vertebræ (F. Jordan) . 15
„ see *Syphilis*.

HÆMORRHAGE, intestinal and peritoneal, following obstruction of mesenteric artery and vein, fatal (F. Taylor) 61
HAND, malformation of (M. Balding) 190
HANDS, fœtal, voluntarily mobile, at the ends of truncated arms, two cases (R. Barwell) 280
HAWARD (*Warrington*), *remarks* in the DISCUSSION ON RICKETS . 334
HEAD and FACE, unilateral hypertrophy of, involving bones and soft parts (R. Barwell) 282
HEART with calcareous plates (R. W. Burnet) . . . 53
„ malformation of the (N. Moore) 39
„ — (N. Tirard) 41
„ — stenosis of orifice of pulmonary artery, aorta from both ventricles, &c. (T. B. Peacock) 35
„ — eight cases in which the patients survived to twenty years of age and upwards 38
„ mucous tumour of, syphilitic gumma? (S. G. Shattock) . . 77
HEMIATROPHIA FACIALIS, case of (J. F. Payne) . . . 306
HERNIA, strangulated inguinal, reduction "en masse," from separation of the neck of the sac (J. McCarthy) 80
HIP-JOINT, RIGHT, disease of, in an infant (J. Abercrombie) . . 192
HORROCKS (*P.*), tricuspid and mitral stenosis . . . 76
HUMPHRY (*Lawrence*), see *West* (*Sam.*).
HUMPHRY (*G. Murray*); *remarks* on Dr. W. A. Brailey's case of chronic hydrocephalus 3
HUTCHINSON (*Jonathan*), parts of joints, showing changes characteristic of gout and rheumatic arthritis from the same patient . . . 193
„ an epithelial ulcer in the leg, with unusual history . . . 230
„ — *report* of the Committee on Morbid Growths (M. Beck and R. J. Godlee) 231
„ congenital fibro-cystic, nævoid? tumour of the cheek . . 240
„ congenital tumour at the extremity of the finger of an infant . . 240
„ congenital tumour on end of toe of an infant . . . 241
„ cartilage tumours in the bones of fingers and metacarpus . . 241
„ the kidneys of a boar pig, dilatation and atrophy of, from disease of the vesiculæ seminales 312
„ *remarks* in the DISCUSSION ON RICKETS . . . 349
„ *report* on Dr. Cavafy's case of abnormal pigmentation of the skin . 260
„ *report* on Mr. W. Baker's case of circumscribed scleroderma . . 262

Digitized by Google

HUTCHINSON (*Jonathan*) see *Crombie* on Ainhum.
„ see *Jones* (*H. Macnaughton*).
„ see *Jordan* (*F.*).
HYALINE, see *Degeneration* (hyaline).
HYDROCELE, congenital, in a case of cirrhosis of the liver in a child (S. Osborn) 133
„ — of the neck, dissection of (F. Treves) 194
HYDROCEPHALUS, chronic, remarkable case of (W. A. Brailey) . 1
„ — with cyst beneath tentorium, *remarks* on W. A. Brailey's case by Professor Humphry 3
„ external (W. Edmunds) 4
HYPERTROPHY, unilateral, of the head and face, involving bones and soft parts (R. Barwell) 282

ICHTHYOSIS, congenital, case of (James Startin) . . . 268
INTESTINAL OBSTRUCTION, two cases of (F. C. Turner) . . 82
INTESTINE, large, in a case of multiple abscess of liver (Sir J. Fayrer) . 123
INTESTINES, DISEASES of 79-138

JAUNDICE, abnormal pigmentation of the skin following (John Cavafy) . 258
JAW, UPPER, round-celled acinous epithelioma of (R. Parker) . . 239
„ — columnar epithelioma of antrum of (R. Parker). . . 239
„ — squamous epithelioma of (H. T. Butlin) . . . 212
„ LOWER, symmetrical exostoses of (F. S. Eve) . . . 170
JENNER (*Sir William*) *remarks* in the DISCUSSION ON RICKETS . . 347
JOINTS, changes in, characteristic of gout and rheumatic arthritis, from same patient (J. Hutchinson) 193
„ tubercular disease of (J. Croft) 174
„ see *Elbow*, *Hip*, *Shoulder*, *Knee*.
JONES (*H. Macnaughton*), *per J. Hutchinson*, sequestrum of clavicle . 192
„ *per ditto*, sarcoma of clavicle 242
„ *per ditto*, osteo-sarcoma of lower end of femur . . . 242
„ *per ditto*, cancer of the mamma following eczema of the nipple . 242
„ *per ditto*, cheiro-pompholyx 272
JONES (*Sydney*) fatty tumour from beneath scalp . . . 243
„ fatty tumour removed from right arytæno-epiglottidean fold . . 243
JORDAN (*Furneaux*), *per Jon. Hutchinson*, gummatous disease of brain, cranial bones, and vertebræ 15

KIDNEYS, extra-renal growth (J. Abercrombie) . . . 205
„ both, cystic disease of, and of liver (P. H. Pye-Smith) . . 112
„ RIGHT, sarcoma of, confined to the capsule (W. H. Day) . . 142
„ of a boar pig, dilatation and atrophy of, from disease of the vesiculæ seminales (Jon. Hutchinson) 312
KNEE-JOINT, fibro-cellular tumour from the interior of (R. J. Godlee) . 207
„ sarcoma of femur extending into, and simulating destructive disease of (F. S. Eve) 169

LARYNX, congenital cyst in (J. Abercrombie) . . . 33
„ nutshell impacted in, tracheotomy, tracheitis and purulent bronchitis, collapse of lungs (R. E. Carrington) 16

Digitized by Google

LEDIARD (*H. A.*), an epulis containing masses of hyaline cartilage (fibro-enchondroma) 244
LEES (*David B.*), *remarks* in the DISCUSSION ON RICKETS . . 323
LEG, see *Ulcer*.
LEUCODERMA, case of (James Startin) 268
LIMB, see *Arm*, *Leg*.
LIVER, abscess of, in a child (N. Moore) 132
„ — consequent upon dysentery contracted in England (W. H. Dickinson) . 127
„ — opened by aspiration and then by direct incision, death on sixth day (Sir J. Fayrer) 119
„ — multiple of, and acute dysentery (Sir J. Fayrer) . . . 123
„ cirrhosis of, in a child (N. Moore) 132
„ — in a child with congenital hydrocele (S. Osborn) . . . 133
„ cystic disease of, and of both kidneys (P. H. Pye-Smith) . . 112
„ cicatrices in, the result of suppurative pylephlebitis (J. F. Goodhart) . 137
LONGHURST (*A. E. T.*), *remarks* in the DISCUSSION ON RICKETS . 378
LUCAS (*Clement*), *remarks* in the DISCUSSION ON RICKETS . . 356
LUNG, cancer of right, with embolism in middle cerebral artery (N. Moore) . 32
„ cavity in, contiguous with thrombosis of innominate vein (W. W. Smith) . 70
„ chronic excavation of, terminating in localised pneumothorax (S. West) . 21
„ extensive opening into, in a case of pneumothorax (S. West) . . 21
„ recurrence of epithelioma in the, two cases (R. J. Godlee) . . 27
„ gangrene of, following excision of tongue for epithelioma (H. Royes Bell) 26
„ — of the, from thrombosis in pulmonary artery (B. G. Morison) . 23
„ secondary growths in, following epithelioma of the tongue (R. J. Godlee) . 27
„ secondary growth in left, following squamous epithelioma of the bladder (R. J. Godlee) 30
LUPUS, case of extensive (Malcolm Morris) 270
LYMPH SCROTUM, showing filaria *in situ* (P. Manson) . . 285
LYMPHATICS, dilatation of, in a case of glioma of the spinal cord (T. T. Whipham) 8

McCARTHY (*Jeremiah*), rupture of the arch of the aorta from injury . 54
„ case of reduction "en masse" of a strangulated inguinal hernia from separation of the neck of the sac 80
„ myeloid tumour of the head of the tibia 208
MACNAMARA (*C.*), congenital tumour containing fœtal structures, removed from the sacrum of a child 199
MAKINS (*G. H.*), case of tubercular disease of the elbow-joint . . 189
MALFORMATIONS (congenital) of hand and feet (M. Balding) . . 190
„ of the heart (N. Moore) 39
„ ditto (N. Tirard) 41
„ ditto, stenosis of orifice of pulmonary artery, &c. (T. B. Peacock) . 35
MALLEOLUS, fracture of the inner, with partial dislocation of the foot (H. Morris) 158
MAMMA, see *Breast*.
„ see *Cancer* of.
MANSON (*P.*), *per Dr. Geo. Thin*, lymph scrotum showing filaria *in situ* [history of the parasite] 285
MAXILLA, INFERIOR, symmetrical exostoses of (F. S. Eve) . . 170
„ see *Jaw*.
MEDULLA OBLONGATA, glioma of (T. T. Whipham) . . . 8

Digitized by Google

MEREDITH (*W. A.*), large multilocular fibro-cystic tumour of uterus . 145
„ fibro-cyst of uterus 151
METACARPUS, cartilage tumours in the bones of (Jon. Hutchinson) . 241
MITRAL VALVE, stenosis of, with contraction of the aortic semilunar valves, in a boy (A. Boyce Barrow) 74
MITRAL and TRICUSPID VALVES, stenosis of (P. Horrocks) . . 76
„ — stenosis of, with concurrent disease of the aortic valves (R. E. Carrington) 75
MOLLUSCUM CONTAGIOSUM, nature and affinities of (A. and B. G. Morison) 245
„ histology and pathology of (H. R. Crocker) . . . 254
„ of Bateman, on the histology of (Geo. Thin) . . . 257
MOORE (*Norman*), tumour of optic tract from a case of diabetes insipidus . 5
„ pyocephalus: brain of a child aged five months . . . 6
„ spinal cord showing dilatation of the central canal . . . 7
„ cancer of the right lung, with embolism in middle cerebral artery, . 32
„ ulcer of right bronchus penetrating the pulmonary artery . . 33
„ malformation of the heart 39
„ blood from a patient who died of diabetes . . . 72
„ abscess of liver in a child 132
„ cirrhosis of liver in a child 132
„ calcified fibroid of uterus 145
„ *remarks* in the DISCUSSION ON RICKETS 334
MORBID GROWTHS 194-244
„ see COMMITTEE on
MORGAN (*John H.*), sarcoma of testis (recent) . . . 243
MORISON (*Alex.* and *Basil G.*), observations on the nature and affinities of molluscum contagiosum 245
„ (*B. G.*), case of gangrene of the lung from thrombosis in pulmonary artery 23
MORRIS (*Henry*), comminuted fracture of the astragalus with subastragaloid dislocation of the foot outwards and backwards . . . 156
„ fracture of the inner malleolus, with partial dislocation of the foot by rotation around its antero-posterior axis 158
„ genu valgum 160
MORRIS (*Malcolm*), case of extreme lupus (living specimen) . . 270
MOSQUITO, history of its relations with the *Filaria sanguinis hominis* 291-293
MOULLIN (*C. Mansell*), cystic degeneration of breast . . . 215
„ *report* of Morbid Growths Committee on ditto (H. T. Butlin and J. F. Goodhart) 217
MYELOID, see *Tumour.*
MYOSITIS, acute, of thigh (C. J. Devis) 273
MYXOMA, see *Adeno-myxoma.*

NECK, congenital hydrocele of, dissection of (F. Treves) . . 194
NECROSIS, acute, of the tibia (W. M. Baker, for G. White) . . 163
NERVES, paralysis of third, fifth, and sixth, of four years' duration, in a girl with inherited syphilis (E. Nettleship) 13
„ median, enlargement of, in a case of congenital syphilis (J. A. Ormerod) . 14
NERVOUS SYSTEM, DISEASES, &c., of 1-15
NETTLESHIP (*E.*), paralysis of third, fifth, and sixth nerves of four years' duration, in a girl, aged fourteen, the subject of inherited syphilis . . 13
NIPPLE and AREOLA, connection between diseases of, and tumours of the breast (G. Thin) 218

Digitized by Google

NIPPLE, see *Eczema* of.
NOSE, acinous adenoma of tip of (R. Parker) 238

OBSTRUCTION, see *Intestinal.*
ODONTOMA of second lower left molar tooth (R. Parker) . . 240
OPTIC TRACT, tumour of, from a case of diabetes insipidus (N. Moore) . 5
ORD (*W. Miller*), aneurysm of the anterior communicating artery of the circle of Willis 65
„ case of colloid cancer of peritoneum invading the spleen . . 214
„ spontaneous disintegration of vesical calculi . . . 304
ORMEROD (*J. A.*), enlargement of median nerve, congenital syphilis . 14
OSBORN (*Samuel*), cirrhosis of liver in a child with congenital hydrocele . 133
OSSEOUS SYSTEM, DISEASES, &c., of . . . 152-193
OSTEO-SARCOMA of lower end of femur (H. M. Jones) . . 242
OSTITIS of the femur (W. M. Baker) 165
„ deformans (F. Treves) 167
OVARY, proliferating cysts in that of a seven months' fœtus (A. Doran) . 147

PALATE (soft), dermoid tumour growing from (W. Hale White) . . 201
„ cleft, dissection of, from the adult (S. G. Shattock) . . . 284
PARKER (*Rushton*), mammary adeno-fibroma, containing an adjacent piece of carcinoma 233
„ — *report* of Morbid Growths Committee on (M. Beck and R. J. Godlee) 235
„ hyaline adeno-myxoma of breast 236
„ acinous adenoma of right breast 237
„ tubular adenoma of left breast 238
„ acinous adenoma of tip of nose 238
„ tubular adenoma of root and dorsum of tongue, submucous . . 238
„ columnar epithelioma of antrum of upper jaw . . . 239
„ round-celled acinous epithelioma, or adenoma of upper jaw . . 239
„ odontoma of second lower left molar tooth . . . 240
PARKER (*Robert W.*), *remarks* in the DISCUSSION ON RICKETS . . 338
PATELLA, old outward dislocation of (C. J. Symonds) . . . 193
PAYNE (*J. F.*), case of hemiatrophia facialis 306
„ see *Devis* (*C. J.*) on myositis.
PEACOCK (*T. B.*), malformation of heart: stenosis of the orifice of the pulmonary artery, aorta from both ventricles, defects in foramen ovale, ductus arteriosus closed 35
„ eight cases in which the patients survived to twenty years of age and upwards 38
PERITONEUM, colloid cancer of, invading the spleen (W. M. Ord) . 214
PHLEBITIS, pyle-, suppurative, with resulting cicatrices in the liver (J. F. Goodhart) 137
PIGMENTATION, abnormal, of the skin following jaundice (John Cavafy) . 258
PLEURA, cancer of right, following cancer of right mamma (S. West) . 227
PNEUMOTHORAX, chronic excavation of the lung terminating in localised (S. West) 21
POLYPUS, congenital mucous, of umbilicus (A. P. Gould) . . 204
„ villous, of the bladder (F. Treves) 141
POPLITEAL SPACE, cylindroma or hyaline degeneration of (H. T. Butlin) 210
PSEUDARTHROSIS, long retention of the ivory pegs in Dieffenbach's operation for (W. Anderson) 170

Digitized by Google

PULMONARY, see *Lungs*.

PYE-SMITH (*P. H.*), cystic disease of the liver, and of both kidneys . 112
„ *report* on Dr. Cavafy's case of abnormal pigmentation of the skin . 260
„ *report* on Mr. W. Baker's case of circumscribed scleroderma . . 262

PYLEPHLEBITIS, suppurative, with resulting cicatrices in the liver (J. F. Goodhart) 137

PYOCEPHALUS, brain of a child aged five months (N. Moore) . . 6

RECTUM, adenoid disease of (cancer) (W. H. Cripps) . . . 87

REDUCTION "en masse," see *Hernia*.

RENAL, extra-, growth, see *Kidneys*.

RESPIRATION, ORGANS of, DISEASES, &c. . . . 16-34

RICKETS, DISCUSSION on the PATHOLOGY of:
„ *opening remarks* by C. Hilton Fagge 313

„ *remarks* by David B. Lees and Thomas Barlow . . 323
„ — Edwards Crisp . . 331
„ — Norman Moore . . 334
„ — Warrington Haward . 334
„ — W. H. Dickinson . 336
„ — R. W. Parker . . 338
„ — Sir William Jenner . 347
„ — Samuel Jones Gee . 349
„ — Jonathan Hutchinson . 349
„ — Clement Lucas . . 356
„ — E. B. Baxter . . 360

„ *remarks* by Thomas Barlow . 364
„ — Samuel G. Shattock . 369
„ — A. E. T. Longhurst . 378
„ — Spencer Watson . 378
„ — James F. Goodhart . 382
„ — F. G. Dawtrey Drewitt . 386
„ *specimen shown* by F. C. Turner 390
„ — by H. Radcliffe Crocker . 390
„ *remarks in reply* by Hilton Fagge 391

„ — TABLES A. Craniotabes marked; syphilis almost certain . . 392
„ — „ B. Craniotabes slight; syphilis almost certain . . 396
„ — „ C. Evidence as to rickets (if any) in fifty-three cases of craniotabes 400

RUPTURE of aorta, see *Aorta (arch of)*.

SACRUM, congenital tumour of (S. G. Shattock) . . . 197
„ — from that of a child containing fœtal structures (C. Macnamara) . 199

SARCOMA of clavicle (H. M. Jones) 242
„ of the lower extremity of the femur extending into knee-joint (F. S. Eve) . 169
„ of the right kidney confined to the capsule (W. H. Day) . . 142
„ of testis (John H. Morgan) 243
„ round-celled, with hyaline degeneration of popliteal space (H. T. Butlin) 210
„ see *Osteo-sarcoma*.

SCALP, circumscribed scleroderma affecting (W. M. Baker) . . 261

SCLERODERMA, case of (J. Abercrombie) . . . 266
„ circumscribed, affecting the face and scalp (W. M. Baker) . . 261

SCROTUM, lymph, showing filaria in *situ* (P. Manson) . . 285

SEPTUM VENTRICULORUM, congenital imperfection of, with ante-mortem thrombosis of right ventricle and pulmonary artery (J. Abercrombie) . 73

SEQUESTRUM of clavicle (H. M. Jones) 192

SHATTOCK (*Samuel G.*), atresia of the aortic aperture in an infant . 38
„ mucous tumour of heart, syphilitic gumma? . . . 77
„ fracture of the coracoid process, followed by fibrous repair . . 155
„ congenital sacral tumour 197
„ arrested development and growth of the right upper limb in man . 276
„ dissection of cleft palate from the adult 284
„ *remarks* in the DISCUSSION ON RICKETS 369

Digitized by Google

SHOULDER-JOINT, RIGHT, disease of, in an infant (J. Abercrombie) . 192
SKIN, abnormal pigmentation of, following jaundice (John Cavafy) . 258
SMITH (*W. Wilberforce*), thombosis of innominate vein contiguous with a pulmonary cavity 70
SPECIMENS, MISCELLANEOUS 273-310
SPECIMENS from the LOWER ANIMALS . . . 311-312
SPINAL CORD showing dilatation of the central canal (N. Moore) . 7
„ and MEDULLA OBLONGATA, tumour of [glioma] with cavity in the central canal (T. T. Whipham) 8
SPLEEN, colloid cancer of peritoneum invading the (W. M. Ord) . . 214
STARTIN (*James*), case of congenital ichthyosis . . . 268
„ case of leucoderma 268
STENOSIS see *Artery* (pulmonary), *Mitral* valve, *Tricuspid* valve.
STOMACH, perforating ulcer of, fatal hæmatemesis thirty hours after birth (J. F. Goodhart) 79
„ INTESTINES, &c., DISEASES of . . . 79-138
SYMONDS (*Charters J.*), old outward dislocation of the patella . . 193
„ epithelioma arising in an ulcer of the leg 244
SYNOVIAL MEMBRANES, tubercular disease of (J. Croft) . . 174
SYPHILIS, congenital, enlargement of median nerve in a case of (J. A. Ormerod) 14
„ inherited, paralysis of third, fifth, and sixth nerves, of four years' duration in a girl, the subject of, aged fourteen (E. Nettleship) . . . 13
„ of the brain, cranial bones, and vertebræ (F. Jordan) . . 15
SYPHILITIC disease of the cerebral arteries (W. Anderson) . . 55
SYPHILITIC GUMMA ? in mucous tumour of the heart (S. G. Shattock) . 77
SYRINGOMYELUS : cavity occupying central canal of spinal cord (T. T. Whipham) 8

TALIPES EQUINO-VALGUS and congenital absence of fibula and two toes (A. P. Gould) 152
TAYLOR (*Frederick*), obstruction of the mesenteric artery and vein, followed by intestinal and peritoneal hæmorrhage, with rapidly fatal termination . 61
„ see *Curran*, calculi
TESTIS, sarcoma of (John H. Morgan) 243
THIGH, acute myositis of (C. J. Devis) 273
THIN (*George*), the connection between disease of the nipple and areola and tumours of the breast 218
„ — summary of his conclusions 227
„ on the histology of the molluscum contagiosum of Bateman . . 257
„ see *Manson* on filaria
THOMPSON (*Reg. E.*), notes of Dr. Whipham's case of glioma of the spinal cord 9
THROMBOSIS in pulmonary artery causing gangrene of the lung (B. G. Morison) 23
„ of right ventricle and pulmonary artery in congenital imperfection of septum ventriculorum (J. Abercrombie) 73
„ of innominate vein, contiguous with a pulmonary cavity (W. W. Smith) . 70
TIBIA, myeloid tumour of the head of (Jer. McCarthy) . . . 208
„ acute necrosis of (W. M. Baker, for G. White) . . . 163
TIRARD (*Nestor*), malformation of the heart . . . 41
TOE, congenital tumour on end of, in an infant (Jon. Hutchinson) . 241

Digitized by Google

TOES, two, congenital absence of, and of fibula, and talipes equino-valgus (A. P. Gould) 152
TONGUE, tubular adenoma of root and dorsum of (R. Parker) . . 238
„ epithelioma of, with secondary growths in the lungs, &c. (R. J. Godlee) . 27
„ excision of the anterior third of, for epithelioma, followed by gangrene of the lung (H. Royes Bell) 26
TOOTH, second lower left molar, odontoma of (R. Parker) . . 240
TREVES (*Frederick*), case of villous polyp of the bladder . . 141
„ ostitis deformans 167
„ dissection of a congenital hydrocele of the neck . . . 194
„ vesical calculus from a dog 311
TRICUSPID VALVE, two cases of extreme stenosis of (B. Fenwick) . 42
„ stenosis of, tabulated summary of 46 cases (B. Fenwick) . . 48
„ and MITRAL VALVE, stenosis of (P. Horrocks) . . . 76
„ — stenosis of, with contraction of aortic semilunar valves, in a boy (A. Boyce Barrow) 74
„ — stenosis of, with concurrent disease of the aortic valves (R. E. Carrington) 75
TUBERCULAR DISEASE of the elbow-joint (G. H. Makins) . . 189
„ — of synovial membranes and of joints (John Croft) . . . 174
„ — of synovial membranes and of joints, opinions of various authors on 184-188
TUMOUR of breast, connection with disease of nipple (G. Thin) . 218
„ of optic tract, from a case of diabetes insipidus (N. Moore) . . 5
„ congenital, at the extremity of the finger of an infant (Jonathan Hutchinson) 241
„ — sacral (S. G. Shattock) 197
„ — containing fœtal structures, from the sacrum of a child (C. Macnamara) 199
„ — on end of toe of an infant (Jonathan Hutchinson) . . 241
„ cartilage, in the bones of fingers and metacarpus (Jonathan Hutchinson) . 241
„ dermoid, growing from soft palate on base of skull (W. Hale White) . 201
„ fatty, from beneath scalp (Sydney Jones) . . . 243
„ — removed from right arytæno-epiglottidean fold (Sydney Jones) . 243
„ calcified fibroid, of uterus (N. Moore) 145
„ fibro-cellular, from the interior of the knee-joint (R. J. Godlee) . 207
„ congenital fibro-cystic, of the cheek, nævoid? (J. Hutchinson) . 240
„ fibro-cystic, of uterus (W. A. Meredith) 151
„ — large multilocular, of uterus (W. A. Meredith) . . . 145
„ [glioma] of the spinal cord and medulla oblongata (T. T. Whipham) . 8
„ myeloid, of the head of the tibia (Jeremiah McCarthy) . . 208
TURNER (*F. C.*), two cases of intestinal obstruction . . . 82
„ *specimen shown* in the DISCUSSION ON RICKETS . . . 390

ULCER of right bronchus penetrating the pulmonary artery (N. Moore) . 33
„ epithelial, in the leg, with unusual history (Jon. Hutchinson) . . 230
„ of leg, epithelioma, arising in an (C. J. Symonds) . . . 244
„ perforating, of the stomach, fatal hæmatemesis thirty hours after birth (J. F. Goodhart) 79
UMBILICUS, congenital mucous polypus of (A. P. Gould) . . 204
URINARY ORGANS, DISEASES, &c., of . . . 139-151
UTERUS, fibro-cyst of (W. A. Meredith) 151
„ large multilocular fibro-cystic tumour of (W. A. Meredith) . . 145
„ calcified fibroid of (N. Moore) 145

VALVES, see *Aortic, Mitral, Tricuspid.*

Digitized by Google

VASCULAR SYSTEM, DISEASES, &c., of 35-78
VEIN, INNOMINATE, thrombosis of, contiguous with a pulmonary cavity (W. W. Smith) 70
„ MESENTERIC, and ARTERY, obstruction of, followed by intestinal and peritoneal hæmorrhage, fatal (F. Taylor) 61
VENTRICLE, LATERAL, aneurysm of middle cerebral artery rupturing into (S. West) 69
„ see *Heart*, *Septum* ventriculorum.
VESICULÆ SEMINALES, disease of, causing dilatation and atrophy of the kidneys of a boar pig (Jon. Hutchinson) 312
VESSELS, see *Arteries*, *Veins*.
VOLKMANN (*R.*), opinions on synovial tubercular disease . . 184

WALDEYER on parenchymatous cancer of the breast, &c., reference to . 224
WATSON (*Spencer*), *remarks* in the DISCUSSION ON RICKETS . . 378
WEST (*Samuel*), chronic excavation of the lung, terminating in localised pneumothorax, with extensive opening into the lung . . . 21
„ aneurysm of the left posterior communicating artery . . 66
„ aneurysm of the pulmonary artery 67
„ aneurysm of middle cerebral artery in a boy of twelve, rupturing into descending cornu of the lateral ventricle 69
„ cancer of right pleura, following cancer of the right mamma successfully removed two years before 227
„ *for Lawrence Humphry*, aneurysmal dilatation and rupture of aortic valve 77
WHIPHAM (*T. T.*), tumour [glioma] of the spinal cord and medulla oblongata, dilatation of the lymphatics and syringomyelus . . . 8
WHITE (*Gregory*), see *Baker* (*W. M.*).
WHITE (*W. Hale*), dermoid tumour probably growing from soft palate or base of skull 201

PRINTED BY J. E. ADLARD, BARTHOLOMEW CLOSE.

Digitized by Google

Digitized by Google

Digitized by Google

Digitized by Google

UNIVERSITY OF MICHIGAN
3 9015 07023 0936

BOUND

JUN 25 1936

UNIV. OF MICH.
LIBRARY





Digitized by Google

Digitized by Google